

Determination of Sexual Dimorphism Using Occlusal Radiograph among Namakkal Population: A Radiographic Study

Sudhaa Mani¹, S Yasmeen Ahamed², A Sheela Amavasai³,
G S Sivaraman⁴, P Ambiga⁵, N Balan⁶

How to cite this article:

Sudhaa Mani, S Yasmeen Ahamed, A Sheela Amavasai, et. al./ Determination of Sexual Dimorphism Using Occlusal Radiograph among Namakkal Population: A Radiographic Study/Indian Journal of Forensic Odontology. 2021;14(1):17–20

Abstract

Background:

Introduction: Radiographs have been widely used to determine morphological traits among genders in forensic odontology.

Aim: The study aims to determine the gender using an occlusal radiograph.

Objectives: Assessing the reliability of linear and angular measurement in the occlusal radiograph.

Materials & Methods: The study was conducted in the Department of Oral Medicine & Radiology in Namakkal District, after obtained approval from the institutional ethical committee with total sample size of 40 dentate subjects using an occlusal radiograph. After obtaining informed consent from patients, the study has been conducted. Topographic occlusal radiographs were taken with help of an intraoral X-ray machine with ideal exposure parameters and all radiation protective precautions were carried out. Linear & angular measurement are measured attributing capital letters to the maxillary arch & small letters to the mandibular arch.

Statistical Analysis: The obtained data were analyzed using student t-test & Spss software version 22.0.

Results: In the present study among linear measurement molar (MM) is highly significant ($p=0.012$). Among Angular measurements max CIA R ($p=0.001$), max PIB R ($p=0.001$), max MIC R ($p=0.007$), man pib r ($p=0.017$), man mic r ($p=0.031$), man pib l ($p=0.028$) are highly significant.

Conclusion: Gender can be determined by occlusal radiographs with greater reliability when linear measurement & angular measurements are performed.

Keywords: Dental arch; Forensic dentistry; Occlusal radiograph; Sex determination.

Introduction

Radiology plays an indispensable role in human gender determination. Radiological images are utilized in the process of age and gender, which is

one of the essential tools in identification in forensic science.

The identification of remains gains utmost importance in cases of mass fatality like in earthquakes, tsunami, cyclones, and floods, etc., where the bodies are damaged beyond recognition. In such situations, where only fragments of skeletal remains are found for e.g. fragment of the jaws, only the odontometric features will help in recognition of the individual from the remains, particularly the teeth in the fragment.¹

Human identification can be done by different methods like fingerprint analysis, which is the most used when soft tissues are preserved. Although situations in which the corpse is charred or skeletonized, an anthropological and dental

Author Affiliation: ¹Professor, ²Associate Professor, ³Post Graduate Student, ^{4,5}Reader, ⁶Professor & HOD, Department of Oral Medicine & Radiology, Vivekanandha Cental College for Women, Elayampalayam, Tiruchengode, Namakkal District 637205, Tamil Nadu, India.

Corresponding Author: Sudhaa Mani, Professor, Department of Oral Medicine & Radiology, Vivekanandha Cental College for Women, Elayampalayam, Tiruchengode, Namakkal District 637205, Tamil Nadu, India.

E-mail: drsudhaamanimds@gmail.com

Received on: 28.05.2021

Accepted on: 15.07.2021

analysis may be necessary in order to determine the person's identity.²

Radiographic and tomographic images have become an essential aid for human identification in forensic dentistry.³ Various methods are employed in forensic odontology to determine the age and sex of an individual. The methods include rugoscopy, cheiloscopy, bite marks, tooth prints, radiographs, a photographic study, and molecular method. Although teeth are excellent study material, variation in the crown size has been reported among different populations. Numerous factors can contribute to variation in tooth size and may be described broadly as genetic, epigenetic, and environmental influences.⁴

The features depicted on radiographs must comply with two requirements in order to be of forensic identification value; on the one hand, the feature has to be unique to each individual, and on the other hand, it has to remain stable over time despite ongoing life processes and aging. Usually, one to four unique analogous features and no discrepancies are considered enough for positive identification.⁵ Males exhibit larger stature, more robust cranial and facial features, greater muscularity, strength, and speed as compared to females.⁶ Variability in arch width in male and female Aborigines was observed.⁷

Hence, the aim of this study is to determine gender using an occlusal radiograph by assessing the reliability of angular and linear measurement in the occlusal radiograph.

Materials & Methods

The study was conducted in the Department of Oral Medicine & Radiology in Vivekanandha Dental College & Hospital, Namakkal District. This radiographic study was done after obtained approval from the institutional ethical committee. Inclusion criteria was patients with the age limit of 20-25 years, Class -1 molar relation with impacted third molars. All the teeth should be present. Exclusion criteria comprised of dental caries, Tooth extraction/missing tooth, Restoration, Attrition & Congenitally missing tooth.

The sample size is 40 dentate subjects with same race are conformed by their demographic details. An occlusal radiograph were taken for the subjects. Blinding was done for the total sample then it is divided into 2 groups (group 1 consist of 20 subject and same as in group 2 =20 subject). After obtaining informed consent from patients, the study has been conducted.

Ideal Topographic maxillary and mandibular occlusal radiograph were taken on an intraoral X-ray machine with ideal exposure parameters such as - F E speed film, 0.40 sec, 70 kvp, 15 mA with minimal errors using lead apron with a thyroid collar for the patient and lead apron for the investigator were used following Position-and distance rule with all radiation precautions.

The radiograph was carefully processed & the image was obtained. Obtained images were traced using the tracing sheet. Linear & angular measurements were measured attributing capital letters to the maxillary arch & small letters to the mandibular arch. The letter L indicates the left side & R indicates the right side (Fig. 1).

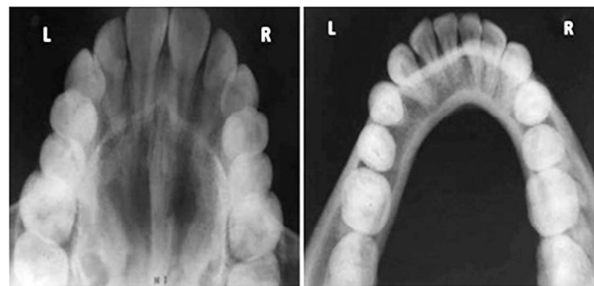

Fig. 1: Occlusal Radiograph representing right & left side.

Linear measurements were measured using a scale in mm. The maxillary and mandibular dental arch's width was made in three portions. The line is drawn from the most vestibular portions of the left and right canines, second premolars, and first molars. Similarly, the lines are drawn for mandibular arches. Named as CC, PP, MM for maxillary arch and cc, pp, and mm for mandibular arch (Fig. 2).

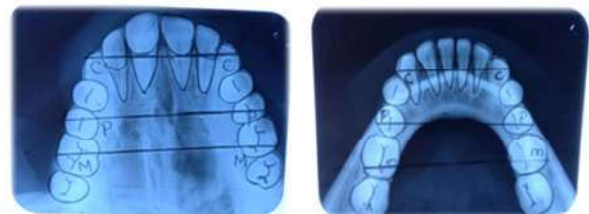


Fig. 2: Linear measurement in Maxillary (CC, PP, MM) & Mandibular arch (cc, pp, mm).

Angular measurements were measured by a median line and a line touching the vestibular portions of the projections of the maxillary central incisors were drawn. The intersection of these points was called the point "I". From this point, another line was drawn towards the most vestibular portion of the canine tooth ("C" point), and this line was named linear measure "IC". The angle formed by these two points and "A" point, locating in the line that coincides with the union of the palatal

processes of the maxillary bone, medial line, was named "CIA R, CIA L". Same way for the premolar & 1 st molar tooth and named as PIB R PIB L, MIC R.MIC L. For maxillary arch. Furthermore for the mandibular arch also and it is named cia r, pib r, mic r cia l, pib l, mic l. (Fig. 3)




Fig. 3: Angular measurements in maxillary (CIA R, PIB R, MIC R, CIA L, PIB L, MIC L) & Mandibular arch (cia r, pib r, mic r, cia l, pib l, mic l)

Statistical Analysis

The obtained data were analyzed by using student -t-test & SPSS software version 22.0 with $p < 0.05$

Result

Linear measurement of group 1 & group 2 are given in (Table: 1 & 2).

Table 1: Linear measurement in group 1.

Group1	CC	PP	MM	cc	pp	mm
Mean	40.45	54.15	59.80	32.45	47.40	57.75
Std.deviation	3.348	5.489	3.578	2.892	4.893	6.034

Table 3: Angular measurement in group 1.

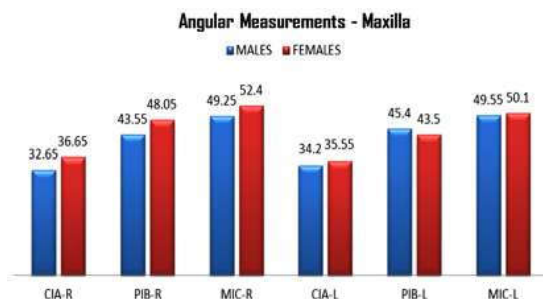
Group1	CIA R	PIB R	MIC R	CIA L	PIB L	MIC L	cia r	pibr	micr	cial	pibl	micl
Mean	32.65	43.55	49.25	34.20	34.20	34.20	28.80	41.15	47.25	29.95	42.50	48.45
Std. Deviation	4.017	3.456	4.064	3.942	3.912	3.762	3.548	2.110	2.110	4.861	4.904	4.968

Table 4 Angular measurement of Group 2: shows man PIB R($p \approx 0.017$),man MIC R($p \approx 0.031$)man PIB L ($p \approx 0.028$) are highly significant.

Table 4: Angular measurement in group 2.

Group 2	CIA R	PIBR	MICR	CIAL	PIBL	MICL	cia r	pibr	micr	cial	pibl	micl
Mean	36.65	48.05	52.40	35.55	43.50	50.10	28.60	43.25	49.45	31.60	45.35	49.85
Std. Deviation	2.925	4.110	2.780	3.734	3.620	3.851	4.272	3.110	3.649	5.661	2.560	2.159

Graph 2 & 3: Represents angular measurements in both the group for maxillary & mandibular arch.



- max CIA R ($p \approx 0.001$)
- max PIB R ($p \approx 0.001$)
- max MICR ($p \approx 0.007$) are highly significant.

Table 2: Linear measurement in group 2.

Group 2	CC	PP	MM	cc	pp	mm
Mean	41.35	51.90	56.95	34.40	47.25	55.40
Std.deviation	3.829	3.837	3.268	3.979	3.370	3.455

Graph: 1 Represents the linear measurement for the both groups. Maxillary molar (MM) are highly significant $p \approx 0.012$

Graph 1: Linear measurement of maxillary molar(MM) are highly significant $p \approx 0.012$

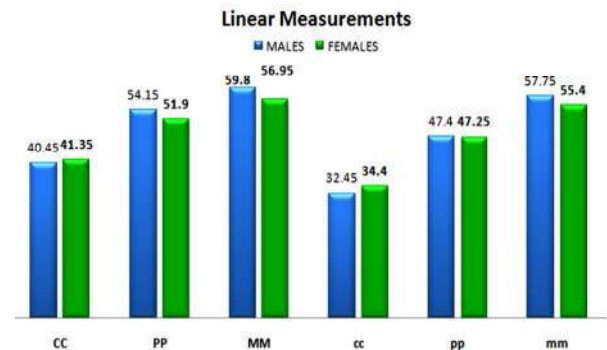
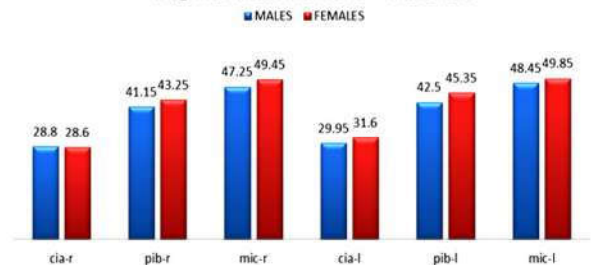


Table 3 Angular measurement of Group 1 shows max CIA R ($p \approx 0.001$)max PIB R ($p \approx 0.001$)max MICR ($p \approx 0.007$) are highly significant.

Angular Measurements - Mandible



- man PIB R($p \approx 0.017$)
- man MIC R($p \approx 0.031$)
- man PIB L($p \approx 0.028$) are highly significant.

Discussion

Sex determination from human remains the primitive step in the establishment of biological demands of the deceased individuals in anthropology and forensic science, go after age and stature appraisal as both are sex dependent.⁸

Inter molar arch width may be useful in determining the gender of dental remains accurately, of individuals with missing canine teeth, and also it may be more accurate in gender determination than inter-canine arch width, with maxillary inter molar arch width being more specific.¹ Maloth et al.2019 Conducted a study on 50 patients in Telangana Population using occlusal radiograph for gender determination.⁹ In his study, he concluded that all the linear measurements are highly significant & angular measurements are maxillary right canine (CIA R), maxillary left canine (CIA L), maxillary left molar (MIC L), maxillary right molar (MIC R) is significant.

Santos LF et al 2015 conducted a study on 50 Brazilian people to analyze the dental arches by occlusal radiograph concluded that linear measurement shows high reliability.¹⁰ The present study concluded that linear maxillary molar (MM) statistically significant.

Sathawane RS et al 2017 a study 60 Indian population to determine gender.¹¹ In that, they concluded that all linear measurements are definite key measurements for gender determination whereas only 2 angular measurements maxillary left canine (CIA L), maxillary left molar (MIC L) are useful. The limitation of our study is smaller sample size with single race .

Conclusion

Hence the present study concluded that gender can be identified with the guidance of occlusal radiographic measurements (odontometry). The main advantages of this method are it is a simple, quick, and accurate technique for gender determination. Future studies on varied population groups with higher sample size might further

useful in gender determination.

References

- Jonathan Daniel.M, MihirKhatri, SV Srinivasan, VK Jimsha, Fremingston Marak. Comparison of Inter-Canine and Inter-Molar Width as an Aid in Gender Determination: A Preliminary Study Indian A cad Forensic Med. April-June 2014, Vol. 36, No. 2
- Gupta A, Kumar K, Shetty DC, Wadhwan V, Jain A, Khanna KS. Stature and gender determination and their correlation using odontometry and skull anthropometry. J Forensic Dent Sci. 2014; 6: 101-6.
- Panchbhai AS. Dental radiographic indicators, a key to age estimation. Dentomaxillofac Radiol.2011; 40: 199-212.
- Litha, H. C. Girish, Sanjay Murgod, and J. K. Savita-Gender determination by odontometric method Journal of Forensic Dental Sciences 2017 Jan-Apr; 9(1): 44.
- Kahana T, Hiss J. Forensic radiology. In: Tsokos M, editor. Forensic Pathology Reviews.Vol 3. Humana Press Inc.;2005. p. 443-60.
- Krishan, K., Chatterjee, P. M., Kanchan, T., Kaur, S., Baryah, N., & Singh, R. K. A review of sex estimation techniques during examination of skeletal remains in forensic anthropology casework. Forensic Science International, 2016; 261, 165.e1-165.e8.
- Dalidjan, M., Sampson, W., & Townsend, G. Prediction of dental arch development: An assessment of Pont's index in three human populations. American Journal of Orthodontics and Dentofacial Orthopedics, 1995;107(5), 465-475.
- Rosing FW, Graw M, Marre B, Ritz-Timme S, Rothschild MA, Rotzsch K, et al. Recommendations for the forensic diagnosis of sex and age from skeletons. Homo 2007;58:75-89.
- Maloth KN, Kundoor VK, Vishnumolakala SL, Kesidi S, Lakshmi MV, Thakur M. Mandibular ramus: A predictor for sex determination-A digitalradiographic study. J Indian Acad Oral Med Radiol 2017;29:242-6.
- Santos LF, Galo R, Alves da Silva RH. Gender evaluation in human beings by occlusal radiographs. Braz J OralSci 2015;14:23 6.
- Sathawane RS, Tripathi K. Determination of gender from occlusal radiographic measurements. IPInt J Maxillofac Imag 2017;3:92 4.

