

Chelioscopy Study on Lip Prints of Male/Female/Transgender/Illness: A Review

Vijayalakshmi Veerasamy¹, Rohith Mohanan²

How to cite this article:

Vijayalakshmi Veerasamy, Rohith Mohanan. Chelioscopy Study on Lip Prints of Male/Female/Transgender/Illness: A Review. Indian J Forensic Med Pathol.2023;16(4):287-294.

ABSTRACT

Like fingerprints, lip prints are completely one-of-a-kind. Lip wrinkles come in a wide variety of shapes and sizes, but this review will focus on the differences between the sexes. There are forensic and non-forensic uses for lip prints. Chelioscopy is a powerful method for solving crimes by examining physical evidence left at the site. Greek chelioswich, meaning “lip” is where the term “cheiloscopy” originates. Both destructive and nondestructive techniques are used to categorize samples. There are numerous classifications that may be applied to lip prints due to their distinctive wrinkling and shape patterns; for instance, the clauco martin santos, Suzuki, and tsuchihasi classifications. Reviewing a large population, we find that both sexes share a preponderance of type IV groove patterns, that male and female lip prints exhibit no discernible variation over time, and that lip prints from the third gender display strikingly different characteristics.

KEYWORDS: Personal identification; Suzuki and Tsuchihashi; Lip prints; Destructive and non-destructive methods; Trimester; Age; Gender; Distinctive folds; Rooves.

INTRODUCTION

The skin, muscles, glands, and mucous membrane that make up the lip folds form an

anatomical barrier to the oral cavity at its entrance. In the same manner as the upper half of the lip extends laterally toward the cheeks to generate the nasolabial sulcus, the bottom part of the lip is bounded inferiorly to form the labio sulcus. The buccal gap, or space between the two lips, is distinct. Skin and a mucous membrane cover the lip area. Lip wrinkles or grooves emerge when the labial cord and Klein’s zone contract. Neither inflammation, herpes, diabetes, or any other medical condition can alter the unique pattern of these lips’ fingerprints.^{1,2}

Other few Methods of Classification:

1. Martin santos classification

Author’s Credentials: ¹Post Graduate Student, ²M.Sc. Student, Department of Forensic Science, University Institute of Allied Health Science, Chandigarh University, Punjab 140413, India.

Corresponding Author: Rohith Mohanan, M.Sc. Student, Department of Forensic Science, University Institute of Allied Health Science, Chandigarh University, Punjab 140413, India.

Email: rohithmohan610@gmail.com

Received on: 29-05-2023

Accepted on: 21-11-2023

2. Suzuki and tsuchihashi classification
3. Renaud classification
4. Afchar-bayat classification
5. Josemaria Dominguez classification^{4,9}

METHOD AND MATERIAL

Lipstick, a brush, cellophane tape, bond paper, and a magnifying glass are all necessities for the sample collection. Put some pressure on the paper where the lipstick is and see what happens. The paper was taped to ensure its survival for future reference. Under magnification, the prints were identified as belonging to the Suzuki and tsuchihashi schools. There were a total of 2112 persons analyzed in the study conducted by Tim Peter Thermadam, Laxmikanth Chatra, and Auswaf Ahsan of the Department of Oral Medicine and Radiology at the KMCT Dental College in Calicut, Kerala. After getting institutional ethical permission and the subject's informed agreement, the researchers employed lipstick to record the lip groove patterns, which were later examined under a microscope. The statistical analysis was performed using SPSS 22.0.^{4, 6, 13}

1. Apply lipstick in the lips using earbuds.
2. Ask the person to cling the lips against bond paper.
3. And the impression is obtained clear with the fissure marks.
4. Fix a cellophane tape over the sample collected.
5. Using the help of magnifying glass make the view of sample more clear.
6. Study the variation of each sexuality/gender.
7. Classify the lip prints and note it.⁶

Chelioscopy:

Chelioscopy was initially described by R. Fischer in 1902. In 1932, the eminent French criminologist Edmond Locard advocated for the use of lip prints as a means of identification. The purpose of this research is to determine the individuality of lip prints and their usefulness in personal identification. The human lip has a transition zone between the inner labial mucosa and the outer skin, and this zone is where fingerprints can be taken in the form of creases and grooves. Chemo-microscopy is a common term for this type of research.⁹

Advantage of Chelioscopy:

Because of its ease of use and low cost, cheiloscopy is increasingly being incorporated into forensic investigations. Our research found no association between ABO blood groups and the prevalence of any given lip print pattern among populations.¹²

LITERATURE REVIEW

Various Methodology of Analysis:

Before each application, the lipstick (REVLON, No. 02 created by Aero pharma Pvt Ltd, Mumbai, India; it was black in color and non-glossy to ensure the optimum print visibility) was wiped off with a tissue paper, as stated by researchers Muniapillai Siva Kumar and Ravi Aravindha. When the subject opened their mouth, lipstick was applied quickly and evenly to their upper and lower lips.^{4,6,7,8,29} "After applying the lip stick, the volunteers were told to rub their lips together. In order to get a good lip print, the person had to keep their mouth open the whole time. To make a lip impression on a glass slide, we first dabbed its center and then pressed our lips uniformly on its upper and lower corners. The lip print can be created with different powders or cyanoacrylate and then photographed if it is preserved on the proper surface. Lip prints taken in latent form must be completely dry before they can be developed, and the same powder is used for both."⁹

BASIC DUSTING OF LATENT PRINTS

Many crime scene investigators employ conventional, non magnetic powder, which accounts for more than half of the powder they use. This rule applies to any domestic crime scene where windows, counters, televisions, and other goods are moved or handled. At commercial break-in scenarios, it can be applied to metal filing cabinets, painted doors, broken glass, and metal window frames. White, dichromatic, silver/gray, and black are only some of the colors available in regular powders. The proper hue is chosen to provide sufficient contrast.⁹

Technique

Muniapillai Siva Kumar and Ravi Aravindan are two practitioners of these methods. Lip designs in order Slides were inspected thoroughly at 10X magnification and then categorized according to suzuki and tsuchihashi's (1970) quadrant wise classification. Only the central 10 mm of the lips

were considered to avoid errors caused by lip prints from the right and left sides of the lips overlapping. Using Suzuki and Tsuchihashi's criteria, the lip prints were categorized, and then the kind and number of grooves were input into the subject's pre-existing proforma, one quadrant at a time. After compiling the information, a comprehensive subject chart was made.^{8,9}

COMPARISON STUDIES OF LIP PRINT

Reddy KS claims that extensive identification is crucial to any criminal inquiry. At the turn of the last century, fingerprints were the only reliable technique of human identification, and their development was largely due to the efforts of Sir William Herschel, Sir Francis Galton, and Sir Edward Henry. In India in 1858, Sir William Herschel used fingerprinting for the first time.^{1,2} Fingerprints and lip grooves, both of which are unique to each individual, can be used for identifying purposes. According to his research, finger printing is much simpler because the details are more distinct.

Kasprzak j, utsuno H, Kanoh T, Tadokoro O, Inoue K as a, state that criminals are familiar with the processes police use while looking into crimes. Lip prints, which are reddish brown to pink in hue and extend from the nasolabial folds to the lower edge of the face, are the subject of chelioscopy. Which is more distinctive than fingerprints due to patterns, and which forms in the womb between the ages of four and six months and cannot be altered unless in the case of certain diseases, such as inflammation and herpes. Lip prints found on napkins, drink glasses, mirrors, or articles of clothing at the scene of a crime might be submitted as evidence in court by the forensic dentistry division.^{1,2,3,6,24}

Cases involving murder, rape, and other serious crimes rely heavily on scientific and investigative controls such as fingerprints, lip prints, DNA, and dental records. As we've already established, there are a number of different categorization methods for chelioscopy, but the one developed by Suzuki and Tsuchihashi in 1970 is by far the most often used. These grooves are broken down into five distinct categories and detailed in Table 1.

Table 1: Types of Lip print patterns according to Suzuki and tsuchihashi.⁸

Classification	Patterns
TYPE - I	Complete Vertical Grooves
TYPE - I	Partial Vertical Grooves
TYPE - II	Branching Grooves

TYPE - III	Interescted Grooves
TYPE - V	Reticular Grooves
TYPE - VI	Other Undifferenated Grooves

The study makes use of brand new computer programs. Statistics are performed using SPSS 2.0. The four sections of a lip print are as follows: The square test was utilized as the significance examination of choice. The letters A, B, C, and D From 0% to 34.70% to 0% to 12.10% in month zero to 28.80% to 35.70% to 0% to 0% in month six. Agreement testing for gender identification using latent variable analysis Gender identification is an important part of forensic science. Significant quadrant based intra and inter-observer agreements were measured using kappa values at 0 and 6 months by both observers. There was statistically significant agreement between the two observers on their assessments of the morphologic pattern of the lip in each of the four quadrants. The calculated kappa values show that the two observers had "excellent" to "very good" agreement when identifying gender. Kappa (K) values were calculated to examine levels of agreement between and among groups of observers. Gender identification is an important part of forensic science. It is based on research in dental rehabilitation. Graph 4 displays the results of an assessment of strong intra and inter-observer agreements using kappa values in each quadrant by both observers at 0 months and 6 months. After six months, Observer measured a gender determination agreement of approximately 67.5% and Observer II measured a gender determination agreement of approximately 57.5%, indicating statistically significant inter and inter-observer agreement when evaluating the morphologic pattern of then accordance. After six months, Observer I's measurement of stability was 0%, whereas Observer II's measurement was 27.8%. Gender identification is an important part of forensic science. It is based on research in dental rehabilitation.

Inter-observer and inter-observer ag that are statistically significant were measured using kappa values in each quadrant by both observers at 0 months and 6 months, respectively. Observer I found an agreement of 95.40%, 95.90%, 100%, and 97.50% between the lipstick and photo methods for determining gender in quadrants A, B, C, and D during the first month, and 82.40%, 85.50%, 87.30%, 92.20% after six months. Gender identification by digital image is discussed as a potential gold standard in Graph 3. The accuracy

of the latent technique to identifying gender in photographs is evaluated.⁷

Using a cross-sectional design, Muhammad hammad 1, Haroon habib 2, Yasir Ali bhatti 3, sadia zia 4, Fouzia javeds 5, mudaser Hussain abbasi 6, rana Muhammad akhtar 7, hassan barkat 8, and salahuddin analyzed data from 1,000 MBBS students. Chi square was computed in the lip print using SSPS software. Tables 2 and 3 both provide chi-square results in the final column.

Table 2: Number of people involved in the research and number of people with types of patterns

	Male	Female	Total
Type I-Long vertical grooves	15	45	60
Type II-Short vertical grooves	2	6	8
Type III-Branching grooves	6	14	20
Type IV-Diamond grooves	1	4	5
Type V-Reticular grooves	2	3	5
Type VI-Undifferentiated grooves	1	1	2

Table 3: The count of each lip print is a calculated in Pearson chi square, likelihood ratio, linear by linear association N of valid cases and they a cell of (58.3%) have excepted count less than⁵

	Value	Df	Asymp. sig (2 sided)
Pearson chi square	1.319 ^a	5	.933
Likelihood ratio	1.233	5	.942
Linear by linear association	.680	1	.409
No of valid cases	100	-	-

Type V was the least common, and there was no significant correlation between male and female lip prints.²³ Cheiloscopy Vahan Wala sonal 1, chintan shah 2, sandeep pagare 3, kapil gavand 4, claimed that, the first proposed i1950, and in the 1960s and early 1970s, experimentation was undertaken on lip prints because, as of right now, unless other than health difficulty at birth, lip prints will not alter.¹⁰⁻²⁰ A recognizable fingerprint may have been acquired. Forensic cheiloscopy specialists say that studying the third gender categorization would provide a good place to begin, and that courts should support such research. The authorities can utilize this information to better identify third gender victims of crime". At all, Pattern types I, I', and II are more common in females, as reported by vahanwala S.P *et al.*²³ The signature of Type III is Male has been identified. Typically males. Because

of the complexity of patterns, errors are possible. Cheiloscopy gender determination may still leave room for doubt. That's why we got result.¹⁰ Eunuchship, as defined by Peeran and Ramalingam, is a peculiar behavioral pattern seen in men who are physiologically born much later in life. It was shown that the majority of the sample population had lip groove types I, I', 4, and 5. Men were more likely to have a type 1' or type 1 lip groove pattern, whereas women were more likely to have a type 4 or type 5 pattern. Comparable findings were found when comparing male and female upper and lower lips independently.

Researchers Aparna 1, Ahmed Mujib. B 2, Rashmi Naik 3, Shruti K Patil 4, and Arun Kumar 5 found that the vast majority of persons with hypertension and diabetes mellitus were classified as having type IV (14) diabetes. The purpose of the research is to compare children with and without²⁹ down syndrome. This research employed an inductive strategy, a cross-sectional design, and extensive direct observation. Among the 68 participants in this cheiloscopy investigation, 34 have Down syndrome and the remaining 34 do not. Labial grooves (I-complete vertical, I'-Incomplete vertical, II-bifurcated, III-crifor the research purpose cross, IV-reticular, or V-undefined) and lip thickness (thin, thick, medium, and mixed) were evaluated in eight labial regions called sub-quadrants in the city of Joo Pessoa, PB, Brazil. Analysis of the data was performed.¹⁵ There are more women than men in the type II category. Type 2 lip print patterns were more common in Bihar and West Bengal than Type 1 patterns were in Odisha.^{7,13,16}

The study's findings suggest that establishing identification is crucial to any criminal inquiry. If available, lip prints should be analyzed with other methods to establish the offender's link to the crimes they committed. Forensic anthropologists rely heavily on cheiloscopy, the study of lip prints, because they are just as unique as fingerprints. Estimating sexuality with lip prints. The study included 434 students, 143 male and 291 female. Dark lipstick and cellophane tape were used to record²⁸ each person's lip print, which were then transferred to white paper. The designs of the upper and lower lips were each divided into three sections, for a total of six sections.^{22,28} Lip print fig. 1 shows the many lip print designs.

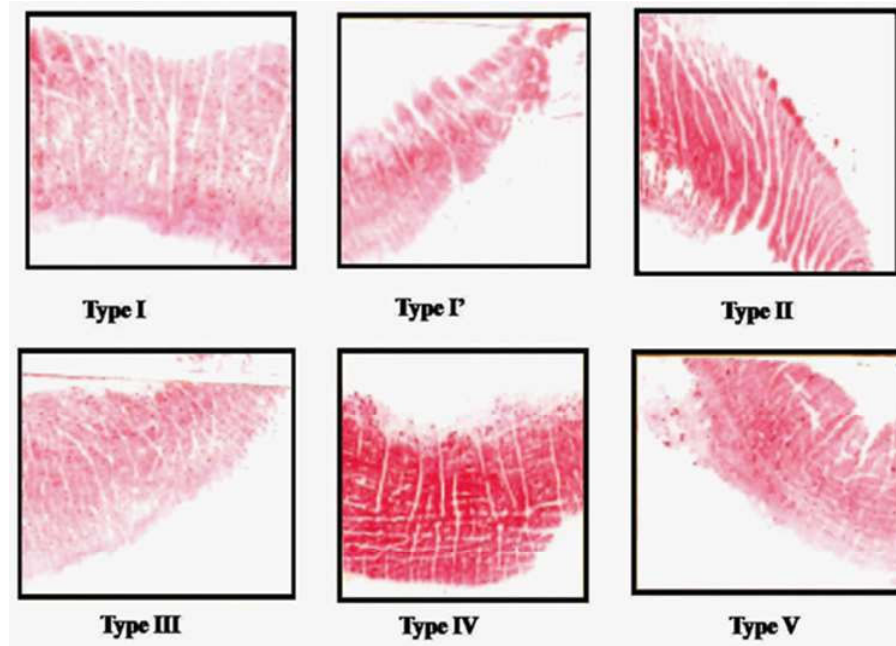


Fig. 1: Different patterns of lip print type I-Full vertical grooves, typeI'-Partial vertical, typeII-Branching grooves, typeIII-intersecting grooves, typeIV-reticular, typeV-other grooves.

Researchers Vikash Ranjan 1, Mysore K Sunil 2, and Raghav Kumar 3 came to the conclusion that the creases and grooves in each participant's labial skin resembled those produced by the conventional way of applying lip stick. Lip prints were unique to each individual, making them a potential form of personal identification. Types I and II predominated in the first quadrant.⁸ Each individual also has their own unique pattern combinations.

Therefore, there is no scientific basis for genetic features like rugae patterns in finger prints or lip prints, nor for castrated men or nice guys behaving in a feminine manner (gay), as both are physically male.²⁷ The present According to studies, more extensive research with a larger sample size is still required to fully understand the transgender community.¹⁰ The amount of rugae on the mid palatine raphe on the right and left sides According to the length of the rugae: The rugae were classified into the following three groups, based on their length:

First >5 mm

3 to 5 mm secondary

3 mm of fragmentation.

A number of researchers, including Eshani saxena 1, B. Rchandrsekhar 2, Sudheer hongal 3, Nilesh torwane 4, Pankaj goel 5, and priyesh mishra 6, have

come to this conclusion: Shorter than 2 millimeter long rugae were disregarded. The length of a rugae was determined by using a divider to measure its biggest dimension, regardless of its shape.²⁶

The rugae were divided into the following classes according to their outward appearance:

They were shaped like a crescent and had a small curvature. Curved rugae were those in which the or end showed any sign of curvature at all. A wavy rugae was one that was curved all the way along its length but just slightly curved at its start or finish. They don't pause between their launch and their destination. Circular rugae are those that form a clear, continuous circle. Two clusters of rugae, one in each direction, were formed. Rugae that pointed ahead were associated with positive angles. Rugae that faced backward were associated with negative angles. Joining of rugae together. When two rugae met at their beginning or end, they were said to be joined. Two distinct groups of rugae emerged as a result of the consolidation. When two rebels begin in the same midline location but shortly split off in opposite directions, we say that they have diverged. Rugae that branched off the midline but met at the sides are said to converge. The palatal rugae pattern was assessed by a single trained and certified analyst. To determine intraexaminer reliability, we re-examined 10 randomly selected casts after a 3

hour interval.¹¹ Type III was the most common male lip print type, whereas Type I was the most common female lip print type. The outer four sections of the lip showed statistically significant differences between sexes. Lip print patterns showed that the central third of the lip played no role in identifying gender. Lip thickness was significantly different between sexes, and this difference could be used in a logistic regression model to identify gender. Not only do the lip prints of men and women differ greatly in pattern, but also in size. A person's sex can be determined using these features.¹⁸ Sudan III dye and aluminum powder generated statistically significant results ($p < 0.05$) when used to make visible lip prints, but had no effect when used to make latent impressions. The use of indigo dye resulted in statistically significant results for the appearance of both latent and obvious lip prints ($p < 0.05$).¹⁹ In one quadrant, there was a statistically significant correlation between parental and offspring lip print patterns, while in the other three quadrants, there was no correlation at all. The good resemblance between family members can be

attributed to genetics and heredity. Lip prints are an extra method of identification.²⁰

According to vahanwala sonal 1, chintah shah 2, Sandeep pangree 3, kapil gavand 4, Hemant bhuntani 5, Naveen shetty 6, mandavi waghare 7, they collected 50 samples of eunuchs, Mumbai roads, and 50 samples of men using the traditional lipstick method; these were analyzed using the Suzuki and Tsuchihashi method to determine whether or not there was a significant difference between the two sexes. Even while they undergo physiological changes characteristic of women, the results indicated that type I and I' that are predominate in nature.¹¹

Researchers K Randhawa 1, R S Narang, and P C Arora say they used lip prints to determine the ages of 600 people (289 men and 311 women) and then split the larger group into three age brackets based on the results: group 1 (individuals aged 1 to 20 years old), group 2 (individuals aged 21 to 40 years old), and group 3 (individuals aged 41 years or older).

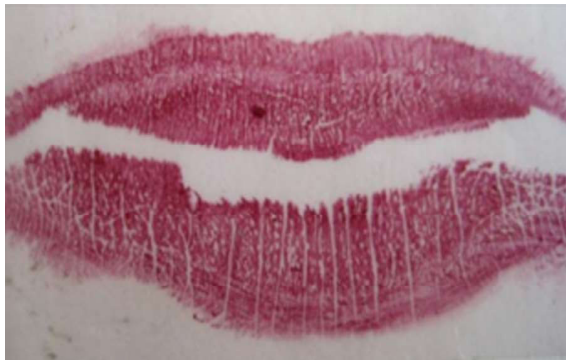

Fig. 2: Lip prints of female with type I-complete vertical grooves



Fig. 3: Type II' in lip print of female

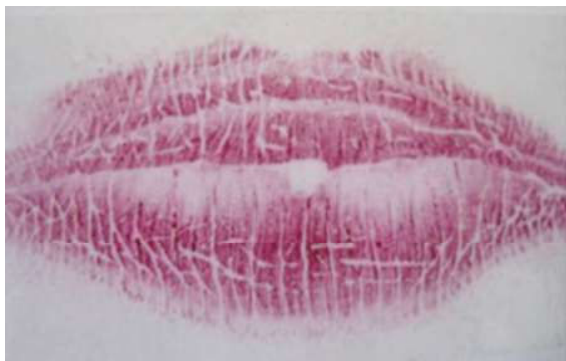

Fig. 4: Type IV in male

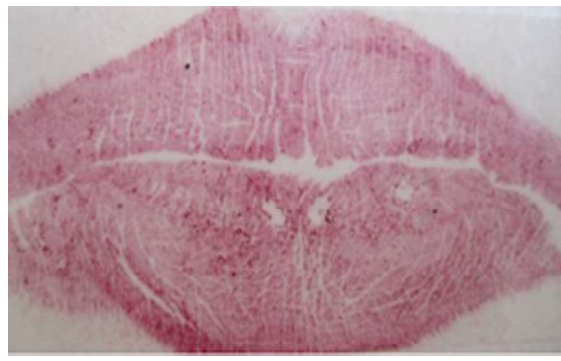


Fig. 5: Type V in male

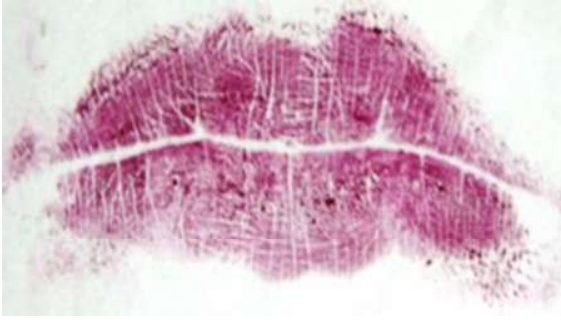


Fig. 6: 9 years old child lip print 1/3 of the lower lip has reticular patterns

According to Rashmi Venkatesh¹, Mariaprisilla David² they organized a research with 200 subjects as a sample for the research purposes and they made them under the group of 4 and the samples of father, mother, child A and child B is taken traditional lip stick method and cellophane tape is stuck against it the glued part into sample bond paper and the analyses is conducted and as a part of result the lip prints between identical twins are different considering the family lip print the child is either is having mother or father same lip print pattern with their own individual miniatures and group 3 the lip prints were taken after an interval of 3 months and the prints are similar to the first set of lip prints hence the lip prints permanence is proved.²⁹

DISCUSSION

The lip prints of people with diabetes and hypertension are distinct from the lip prints of those without these diseases, and the lip prints of brothers and sisters are also different. Because there is a distinct difference in the lip prints of every individual, it is possible to easily recognize a person's gender. This is because the lip prints of the third

gender are also different, and these lip patterns differ based on the hormonal changes.

CONCLUSION

According to these researchers, the research population shows a separate change between male and female in which male has type I or I' in the maximum study population and female has type II very few researchers who have examined the lip print of third genders until the person either with diabetes, hypertension, herpes, inflammation and trauma only that can change the lip print during the period of this illness other than this nothing can change the lip print. And even this lip prints of patients with diabetes and herpes have predominance of type III in common without considering genders.²⁵

Forensic Significance of Cheiloscopy:

Most people of both sexes share the same type 4 lip print pattern, which is significant according to the research of 1. Avanindra Kumar, 2. Swami Nand Prasad, 3. Vaibhav Kamal, 4. Swati Priya, 5. Mukesh Kumar, 6. Avanish Kumar. The research suggests that lip prints can be used as an additional method of determining a person's race. Cheiloscopy is a newer technique among the various identifying methods available to forensic experts. Several important conclusions have already been drawn from this line of inquiry, including the fact that an individual's lip print can be used to verify their identification, that it does not change over time, and that it can be used to distinguish between the sexes. With greater study, cheiloscopy has the potential to become a reliable evidence method.^{13,21}

Conflict of Interest: Nil

Source of Funding: Nil

REFERENCES

- Kasprzak, J. (1990, May).** Possibilities of cheiloscopy. *Forensic Science International*, 46(1-2), 145-151.
- Finnegan, M. (2000, March 1).** T. Dale Stewart: Remembrances of a Scholar and Colleague. *Journal of Forensic Sciences*, 45(2), 14678J.
- Study on Pattern of Lip Prints and its Relation to Sex and Blood Groups in Telangana Population. (2020, October 23).** *Medico-Legal Update*, 20(4).
- Prabhu, R., Dinkar, A., Prabhu, V., & Rao, P. (2012).** Cheiloscopy: Revisited. *Journal of Forensic Dental Sciences*, 4(1), 47.
- Utsuno, H., Kanoh, T., Tadokoro, O., & Inoue, K. (2005, May).** Preliminary study of post mortem identification using lip prints. *Forensic Science International*, 149(2-3), 129-132.
- Thermadam TP, Chatra L, Ahsan A.** Cheiloscopy in gender determination: A study on 2112 individuals. *J Family Med Prim Care*. 2020 Mar 26;9(3):1386-1390. doi: 10.4103/jfmpc.jfmpc_1046_19. PMID: 32509620; PMCID: PMC7266203.
- Utsuno, H., Kanoh, T., Tadokoro, O., & Inoue, K. (2005, May).** Preliminary study of post mortem identification using lip prints. *Forensic Science International*, 149(2-3), 129-132. <https://doi.org/10.1016/j.forsciint.2004.05.013>.
- B, A., B.R, A. M., Naik, R., K Patil, S., & N, A. K. (2018, April 5).** Evaluation and Comparison of Various Methods of Lip Prints in Gender Determination and Its Stability Over a Period of Time. *International Journal of Anatomy and Research*, 6(2.1), 5167-

- 5171.
9. **Ranjan, V., Sunil, M., & Kumar, R. (2014).** Study of lip prints: A forensic study. *Journal of Indian Academy of Oral Medicine and Radiology*, 26(1), 50.
 10. **Dineshshankar, J., Ganapathi, N., Yoithapprabhunath, T., Maheswaran, T., Kumar, M., & Aravindhan, R. (2013).** Lip prints: Role in forensic odontology. *Journal of Pharmacy and Bioallied Sciences*, 5(5), 95.
 11. **Sonal, V., Shah, C., Pagare, S., Gavand, K., Bhutani, H., Shetty, N., & Waghmare, M. (2019).** Cheiloscopy in Transgenders. *Medico-Legal Update*, 19(2), 234.
 12. **Saxena, E., Hongal, S., Torwane, N., Mishra, P., Chandrashekhar, B., & Goel, P. (2015).** A study of the palatal rugae pattern among male female and transgender population of Bhopal city. *Journal of Forensic Dental Sciences*, 7(2), 142.
 13. www.cheiloscopywikipedia.com
 14. **Chatra, L., Thermadam, T., & Ahsan, A. (2020).** Cheiloscopy in gender determination: A study on 2112 individuals. *Journal of Family Medicine and Primary Care*, 9(3), 1386. https://doi.org/10.4103/jfmpc.jfmpc_1046_19.
 15. **Goud, E. S. S., Verma, F., Kulkarni, M., Gupta, S., Choudhury, B., & Rajguru, J. (2022).** Reliability of cheiloscopy and dermatoglyphics in hypertension and diabetes. A comparative study. *Annals of African Medicine*, 21(1), 77.
 16. **Fernandes, L. C. C., Bento, M. I. C., Oliveira, J. D. A., Soriano, E. P., Santiago, B. M., & Rabello, P. M. (2017).** Identificação Odontológica Post-Mortem Por Meio De Fotografias Do Sorriso: Revisão De Literatura. *Revista Brasileira De Odontologia Legal*, 57–66. [http](http://).
 17. **Dash, K., Mishra, P., Panda, A., Kumar, H., Bhuyan, L., & Mahapatra, N. (2022).** A cheiloscopy study among students of different regional states in Eastern India: An institutional study. *Journal of Pharmacy and Bioallied Sciences*, 14(5), 616.
 18. **Gupta, K., Sardana, V., Malhotra, G., Balappanavar, A., & Singh, J. (2012).** Sex determination using cheiloscopy and mandibular canine index as a tool in forensic dentistry. *Journal of Forensic Dental Sciences*, 4(2), 70.
 19. **Kautilya D., V. (2013).** Efficacy of Cheiloscopy in Determination of Sex Among South Indians. *Journal of Clinical and Diagnostic Research*.
 20. **Dolly, A. (2016).** Evaluation of Efficacy of Three Different Materials Used in Cheiloscopy – A Comparative Study. *Journal of Clinical and Diagnostic Research*.
 21. **Yadava, T., Chandrakala, J., Suganya, G., Doddawad, V., Nagarathna, J., & Kalavathi, M. (2022).** Lip print patterns: Similarities among the parents and their children. *Journal of Oral and Maxillofacial Pathology*, 26(1), 134. https://doi.org/10.4103/jomfp.jomfp_194_21.
 22. **Kumar, A., Prasad, S. N., Kamal, V., Priya, S., Kumar, M., & Kumar, A. (2016).** Importance of Cheiloscopy. *International Journal of Oral Care & Research*, 4, 48–52.
 23. **Pelin, C., Oktem, H., Kurkcuoglu, A., & Olmus, H. (2019).** Lip Print Characteristics in Anatolian Population: Baskent University Sample. *OALib*, 06(01), 1–10.
 24. **Muhammad Hammad, Haroon, Habib, Bhatti, Yasir Ali, Sadia, Zia, Fouzia, Javed, Mudaser, Hussain Abbasi, Rana, Muhammad Akhtar, Barkat, Hassaan, SALAHUDDIN,** Gender Variation of Lip prints among the students of Avicenna Medical College, Lahore, *P J M H S*, 2014;8(2), Apr – Jun:323.
 25. **Yendriwati, Y., Joe, J. W., & Fitri, A. R. (2019, September 16).** Lip Print as a Method for Forensic Identification on Malaysian with Chinese Ethnicity. *Journal of Evolution of Medical and Dental Sciences*, 8(37), 2831–2835. <https://doi.org/10.14260/jemds/2019/615>.
 26. **Henderson, J. (1996, January 31).** WWW: What do Researchers Want? *IASSIST Quarterly*, 19(3), 31.
 27. **Rateb, A., EzAldeen, M., & Bushra, R. (2022, November 19).** Palmar Dermatoglyphics and Lip prints Morphological Patterns as Genetic Markers among Hypertensive Patients (A study on the Upper Egyptian Females Population at Assiut University Teaching Hospital. *Egyptian Academic Journal of Biological Sciences. C, Physiology and Molecular Biology*, 14(2), 287–310.
 28. Study on Pattern of Lip Prints and its Relation to Sex and Blood Groups in Telangana Population. (2020, October 23). *Medico-Legal Update*, 20(4).
 29. **Venkatesh, R., & David, M. (2011).** Cheiloscopy: An aid for personal identification. *Journal of Forensic Dental Sciences*, 3(2), 67.

