

Fatal Acute Upper Airway Obstruction Due to Cervical Goiter: A Rare Case Report

Abhishek Yadav¹, Abilash S², Jay Narayan Pandit³, Sudheer K Arava⁴

How to cite this article:

Abhishek Yadav, Abilash S, Jay Narayan Pandit, et. al. Fatal Acute Upper Airway Obstruction Due to Cervical Goiter: A Rare Case Report. Indian J Forensic Med Pathol. 2020;13(3):459-462.

Abstract

Acute upper airway obstruction may occur due to swelling of the thyroid gland. In such cases the onset of symptom is gradual as compared to fatal compression of neck and rarely causes sudden death. The authors report a case of death due to acute airway obstruction by complications of thyroid gland enlargement. The patients with a large goiter/ thyroid neck swelling, even asymptomatic, should be counseled about the impending complications by the treating doctor. The authors aim to add to Medical literature that acute airway obstruction due to natural causes may also be a cause of sudden death. Forensic Pathologists should consider this diagnosis in cases of sudden death with signs of asphyxia so as to prevent any misdiagnosis of violent asphyxial deaths.

Keywords: Acute Airway obstruction; Asphyxial deaths; Fatal thyroid enlargement; Adenomatous goiter.

Introduction

Human Upper respiratory system includes nasal cavity, pharynx and larynx. Acute upper airway obstruction causes narrowing or occlusion of the respiratory passage leading to respiratory distress and even death. Neck is a complex anatomical structure containing parts of the upper respiratory system. Any abnormality, deformity or trauma in neck structures could lead to compression of the respiratory passage, subsequent asphyxia and fatality. In Forensic Pathology practice generally the cases of airway obstruction are commonly encountered in cases of fatal compression of neck due to ligature, manual or by means of any object.¹

Upper airway obstruction may also occur due to swelling of the thyroid gland. In such cases the onset of symptom is gradual as compared to fatal compression of neck and rarely causes sudden death. The authors report a case of death due to acute airway obstruction by complications of thyroid gland enlargement. The authors aim to add to Medical literature that acute airway obstruction due to natural causes may also be a cause of sudden death.

Case History

The deceased was a 47 years old female taking treatment for goiter from past few years. One day she suddenly faced difficulty in breathing and was brought to hospital where she was declared brought dead.

Autopsy Findings

The deceased was an average built middle aged female. The clothes were intact. No external injury

Authors Affiliation: ¹Associate Professor, ^{2,3}Senior Resident, Department of Forensic Medicine and Toxicology, ⁴Additional Professor, Cardiac Pathology, Department of Pathology, All India Institute of Medical sciences (AIIMS), New Delhi 110029, India.

Corresponding Author: Abhishek Yadav, Associate Professor, Department of Forensic Medicine and Toxicology, All India Institute of Medical Sciences (AIIMS), New Delhi 110029, India.

E-mail: drayad_in@yahoo.com

was present over the body. A swelling of size 9 x 7 cm was present over the anterior aspect of neck. Bluish discoloration of lips and nail beds was present. Neck was dissected in bloodless field. Thyroid gland enlargement across midline was present with size of 10 x 8 x 3cm and is adhered with trachea compressing its lumen (Image 1). Weight of thyroid was 65 gm. The larynx was edematous and congested. Trachea, bronchii, lungs and brain were congested. Other organs did not have any gross pathology. Stomach contained about 800 ml of partially digested food material. There was no offensive smell or features of poisoning present in the stomach contents.

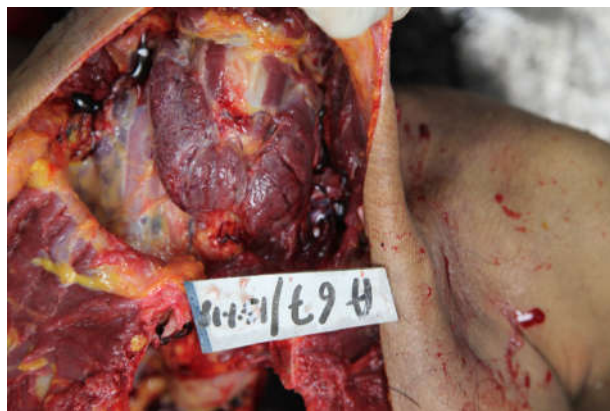

Image 1: Thyroid gland enlargement across midline with trachea compressing its lumen.

On gross examination, thyroid gland was enlarged grossly with lobulated surface and intact capsule. On sectioning, cut surface showed variably dilated and cystic spaces filled with colloid. On microscopy the thyroid gland showed benign thyroid follicles of variable size along with cystically

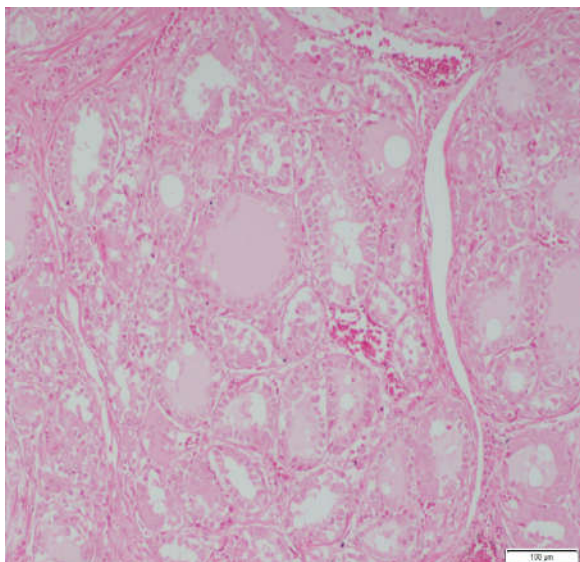


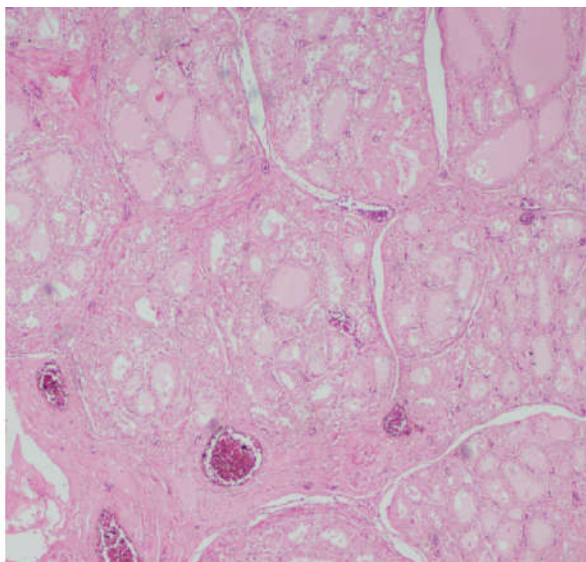
Image 2: Thyroid gland showing benign thyroid follicles of variable size along with cystically dilated follicles filled with colloid substance; Adenomatous goiter was rendered.

dilated follicles filled with colloid substance. Focal areas showing hyperplastic changes were also noted. There was no evidence of malignancy even after extensive sampling. Hence, the final histopathological diagnosis of adenomatous goiter was rendered (Image 2).

The cause of death was concluded as Asphyxia due to laryngeal edema consequent upon thyroid gland enlargement.

Discussion

Benign Nodular Goitre (BNG) affects 5% of the general population in non-endemic areas² and up to 15% in endemic areas.³ Indian population is prone to Iodine Deficiency Disorders (IDD) due to deficiency of iodine in the soil of the Indian subcontinent.⁴ Surveys conducted by the Central and State Health Authorities have recognized the IDD as a public health problem in all States and union territories in India.⁴ Goitre is included in the spectrum of diseases caused by IDD's which also include cretinism, hypothyroidism, brain damage, abortion, still birth, mental retardation, psychomotor defects and hearing and speech impairment.⁴ Adenomatous goiter as confirmed after histopathological examination in our case is a form of Benign Nodular Goiter (BNG). Thyroid Adenomas are typically discrete solitary masses derived from follicular epithelium⁵. Clinically Palpable thyroid nodules are present in approximately 4% of the adult population, with the prevalence increasing in the later decades of life.⁶ Women are affected more commonly than men in



relation to the presence of enlarged thyroid gland due to nodules.⁷ The deceased in our case was a middle aged female belonging to an endemic region, thus falling in this high risk group.

Acute airway obstruction by enlarged thyroid gland are commonly reported in presence of malignancies of thyroid gland^{8,9} and benign retrosternal goiters.^{10,11} Benign goitre causing acute airway obstruction is very rare^{12,13} and amongst them Cervical Benign goiters have a very low mortality rate and death due to airway obstruction.¹⁴ Airway problems due to enlarged thyroid glands appear usually in a gradual manner and are frequently associated with the insidious onset of symptoms. Previous studies have shown that tracheal occlusion in many patients ranging upto 50 to 70 percent is well tolerated and only minimal respiratory changes are observed in them.¹⁵ Benign goiters generally have a slow growth rate which allows adaptation to extrinsic hypoventilation without causing any acute symptoms.¹⁴ There may be cases in which patients present with acute premonitory symptoms which if ignored by the patient may precipitate a life threatening situation needing immediate management.¹⁵ In benign cervical thyroid enlargements few risk factors like acute hemorrhage into a cyst, an upper respiratory tract infection causing edema, tracheal collapse or worsening of comorbidities can cause acute airway obstruction.¹⁶ Agarwal et.al in their study described that the incidence of tracheomalacia due to huge goiters was another risk factor for acute upper airway obstruction.¹⁷ Thyroid with diffusely grown lobes pushing into the space between the posterior wall of the trachea and esophagus, can lead to the tracheal stenosis by compressing the posterior wall of the trachea.¹⁸ In our case acute upper airway obstruction occurred due to laryngeal edema in a case with already compromised respiratory passage. Laryngeal edema occurs due to mucopolysaccharide deposition in the supraglottic region, including the aryepiglottic folds, false vocal folds, vocal cords and surrounding regions. The edema can subsequently causes upper airway obstruction and acute respiratory distress.^{19,20} Though rare, laryngeal edema has been reported previously in hypothyroid cases, both with or without enlargement of thyroid gland due to goiter.^{21,22} But in these cases patients were saved due to timely Medical intervention. The same mechanism is seen in the present case, where no diagnosis of any infection of throat or respiratory tract was made. Histopathological examination of the gland also ruled out presence of any malignancy or haemorrhage into any cyst. The deceased was

not fortunate to reach the Hospital on time so that timely intervention could have saved her life.

Conclusion

The patients with a large goiter/ thyroid neck swelling, even asymptomatic, should be counseled about the impending complications by the treating doctor. The possibility of acute airway obstruction should always be discussed. An elective thyroidectomy should be performed with large goiters even with lesser grades of compressive symptomatology. Forensic Pathologists should consider this diagnosis in cases of sudden death with signs of asphyxia so as to prevent any misdiagnosis of violent asphyxial deaths.

Conflict of Interest: Nil.

Ethical clearance: Not Applicable.

Funding: None.

References

1. Saukko P, Knight B. Knight's Forensic Pathology. 4th ed. CRC Press; Boca Raton:2016. Chapter-15: Fatal Pressure on the neck: 369-397.
2. Knudsen N, Perrild H, Christiansen E, Rasmussen S, Dige-Petersen H, Jorgensen T. Thyroid structure and size and two year follow-up of solitary cold nodules in an unselected population with borderline iodine deficiency. Eur. J. Endocrinol. 2000;142:224-30.
3. Abraham D, Singh N, Lang B, Chan WF, Lo CY. Benign nodular goitre presenting as acute airway obstruction. ANZ journal of surgery. 2007 May; 77(5):364-7.
4. Pandav CS, Yadav K, Srivastava R, Pandav R, Karmarkar MG. Iodine deficiency disorders (IDD) control in India. Indian J Med Res. 2013 Sep; 138(3): 418-433.
5. Kumar V, Abbas AK, Aster JC. Robbins & Cotran Pathologic Basis of disease. South Asia edition-Volume-II. Elsevier; New Delhi:2015. Chapter-24; Endocrine system:1093.
6. Thomas, CG. Nodular goiter and benign and malignant neoplasms of the thyroid. In: Sabiston, DC , editor. Davis-Christopher textbook of surgery. 12th ed. Philadelphia: Saunders, 1981;690-713.
7. Sajja LR, Mannam GC, Sompalli S, Simhadri CS, Hasan A. Multinodular goiter compressing the trachea following open heart surgery. Asian Cardiovascular and Thoracic Annals. 2006 Oct;14(5):416-7.

8. Iwasaki Y. Undifferentiated Thyroid Carcinoma Caused Sudden Airway Obstruction. *Western Journal of Emergency Medicine: Integrating Emergency Care with Population Health*. 2015;16(7).
9. Musa AA, Adebayo SB, Banjo AA, Oyewole EA, Olateju SO. Case Report: Emergency partial thyroidectomy under cervical block to relieve severe acute airway obstruction from thyroid cancer. *African health sciences*. 2008;8(3):186-9.
10. Dias T, Santos A, Mesquita C, Santos RM. Acute airway obstruction due to benign multinodular goitre. *BMJ Case Reports CP*. 2019 Apr 1;12(4):e228095.
11. Ioannidis O, Dalampini E, Chatzopoulos S, Kotronis A, Paraskevas G, Konstantara A, Papadimitriou N, Makrantonakis A, Kakoutis E. Acute respiratory failure caused by neglected giant substernal nontoxic goiter. *Arquivos Brasileiros de Endocrinologia & Metabologia*. 2011 Apr;55(3):229-32.
12. Gauger PG, Guinea AI, Reeve TS, Delbridge LW. The spectrum of emergency admissions for thyroidectomy. *Am. J. Emerg. Med.* 1999;17: 591-3.
13. Anders HJ. Compression syndromes caused by substernal goiters. *Postgrad. Med. J.* 1998;74: 327-9.
14. Sharma A, Naraynsingh V and Teelucksingh S: Benign cervical multi-nodular goiter presenting with acute airway obstruction: a case report. 2010. *J Med Case Rep* 4: 258.
15. Shaha AR, Burnett C, Alfonso A, Jaffe BM. Goiters and airway problems. *The American Journal of Surgery*. 1989 Oct 1;158(4):378-80.
16. Ito T, Shingu K, Maeda C, Kitazawa M, Mizukami Y, Hiraguri M, Horigome N, Kaneko G, Itoh N, Ito KI. Acute airway obstruction due to benign asymptomatic nodular goiter in the cervical region: A case report. *Oncology letters*. 2015 Sep 1;10(3):1453-5.
17. Agarwal A, Agarwal S, Tewari P, Gupta S, Chand G, et al. (2012) Clinicopathological profile, airway management, and outcome in huge multinodular goiters: An institutional experience from an endemic goiter region. *World Journal of Surgery* 36: 755-760.
18. Kusunoki T, Homma H, Kidokoro Y, Yanai A, Wada R, Ikeda K. Tracheal stenosis due to huge adenomatous goiter. *Otorhinolaryngol Head Neck Surg*, 2016; 2(2): 1-2.
19. Wartofsky L. Myxedema coma. *Endocrinol Metab Clin North Am*. 2006;35:687-698.
20. Batniji RK, Butehorn HF 3rd, Cevera JJ, Gavin JP, Seymour PE, Parnes SM. Supraglottic myxedema presenting as acute upper airway obstruction. *Otolaryngol Head Neck Surg*. 2006;134:348-350.
21. Salgado nunez del prado SR, Steinman RA, Munir KM, Lamos EM. Supraglottic myxedema: two cases and a review of the literature. *AACE clinical case reports*. 2017 Mar;3(2):e101-5.
22. Batniji RK, Butehorn III HF, Cevera JJ, Gavin JP, Seymour PE, Parnes SM. Supraglottic myxedema presenting as acute upper airway obstruction. *Otolaryngology – Head and Neck Surgery*. 2006 Feb;134(2):348-50.

