

Where to Bind, Haemoglobin or Methemoglobin - Confused Oxygen

A. Josephine Leshiini¹, Priya Govil², Kishalay Datta³

How to cite this article:

A. Josephine Leshiini, Priya Govil, Kishalay Datta/Where to Bind, Haemoglobin or Methemoglobin - Confused Oxygen/Indian J Emerg Med 2023;9(2):93-95.

Abstract

Methemoglobinemia is a life-threatening condition in which there is a decrease in the oxygen carrying capacity of the blood (hemoglobin). The relative hypoxemia leads to fall in patient blood saturation without any breathing difficulty. We discuss a case of methemoglobinemia in a young adult with leprosy, the presentation and management of the condition in the Emergency room.

Keywords: Methemoglobinemia; methylene blue; tablet Dapsone

INTRODUCTION

Methemoglobinemia is a condition where there is diminished oxygen-carrying capacity of circulating hemoglobin. This occurs due to conversion of iron species from the reduced ferrous [Fe²⁺] state to the oxidized ferric [Fe³⁺] state of the hemoglobin.¹ Oxidized form of iron is unable to bind and transport the oxygen. Methemoglobin has a very high oxygen affinity and virtually no oxygen is delivered to the tissues. This increased level of methemoglobin results in functional anemia.

Methemoglobinemia can be congenital or acquired.^{1,2} Hemoglobin M disease are all possible mutations that usually occur in both the alpha or beta chains of hemoglobin near the heme iron.³ Acquired methemoglobinemia may occur due to exposure to direct oxidizing agents (e.g. benzocaine and prilocaine), indirect oxidation agents (e.g. nitrates), or metabolic activation (e.g. aniline and dapsone).⁴

CASE

A 24 year old male was brought to the emergency room with complaints of headache with lethargy and found to have low blood saturation. Patient blood saturation was on the lower side in the emergency room (around 75-80% on room air) without any breathing difficulty. Patient was not having any symptoms of lower respiratory tract infection, the blood gas analysis was having partial pressure of oxygen around 78 mmHg, oxygen saturation around 72.2 mmHg (both on room

Author's Affiliation: ¹Post Graduate Trainee, ²Senior Consultant, ³Director and HOD, Department of Emergency Medicine, Max Super Speciality Hospital, Shalimar Bagh, Delhi-110088, India.

Corresponding Author: A. Josephine Leshiini, Post Graduate Trainee, Department of Emergency Medicine, Max Super Speciality Hospital, Shalimar Bagh, Delhi-110088, India.

E-mail: josephineleshiini@gmail.com

Received on: 13-02-2023

Accepted on: 07-03-2023

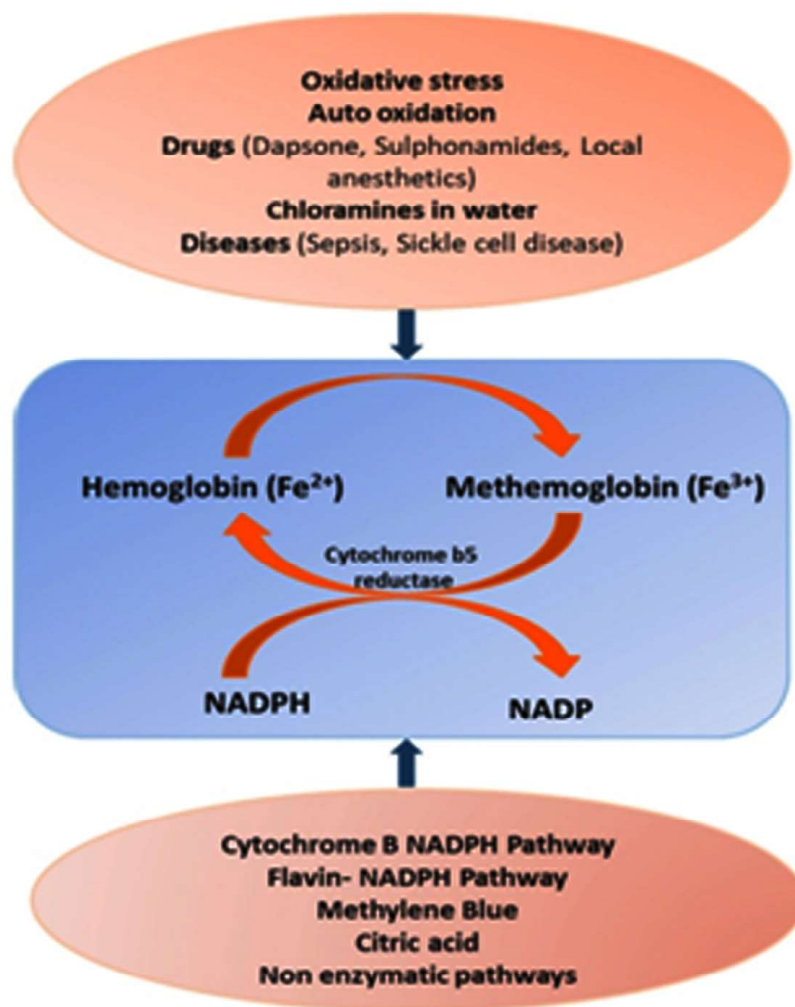
air). Patient was taken put on high flow oxygen (non rebreather mask) @ 15 litres oxygen still the oxygen blood saturation was persisting around 85%. Patient was recently diagnosed with leprosy and was started on leprosy therapy. Patient was admitted for further medical care in the critical care unit. Patient laboratory investigations and radiological imaging was all within normal limits. Patient desaturation state persisted even on a high flow mask.

On further detailed evaluation, the patient was noted to have started taking Tab Dapsone recently in his leprosy therapy. The patient Methemoglobin was found to be elevated on co-oximetry test. Patient was started Injection Methylene blue (as per toxicology screen). Patient condition started improving, the oxygen demand reduced and after

3 days of Methylene blue therapy, the patient was shifted to the general ward. Patient condition improved and was discharged home successfully with improved (on normal air) vitals stats. During the next few follow-up, patient condition remained stable, Dapsone dose was reduced to considerable level after discussion with the infection medicine specialist of our hospital which was appropriate for leprosy treatment and not injurious to the patient health.

DISCUSSION

Dapsone is metabolized in the liver by N-acetylation and N-hydroxylation. Dapsone hydroxylamine is a strong oxidant and metabolic activation results in methemoglobinemia.⁶



Methemoglobinemia is a clinical diagnosis based on history and presenting symptoms. The hypoxemia is refractory to supplemental oxygen. The presence of iron in oxidized state [Fe³⁺] results in allosteric changes in the molecule

leading to shifting of oxygen dissociation curve to the left. This leftwards shift leads to increased affinity of the iron molecule for oxygen and thus impaired oxygen release to the tissue.⁷ The end result of these changes is decreased oxygen

delivery leading to tissue hypoxia. The diagnosis is confirmed by arterial or venous blood gas with co-oximetry, which will speciate hemoglobin to determine the methemoglobin concentration.⁸ The pulse oximeter measures the relative absorbance of two wavelengths of light (660 and 940 nm), that correspond (respectively) to the absorption of oxyhemoglobin (O₂Hb) and deoxyhemoglobin (HHb). Although the methemoglobin absorbance at 660 nm wavelength is similar to that of deoxyhemoglobin, the methemoglobin absorbance at 940 nm wavelength is markedly greater than any other blood constituents parameter. This leads to a falsely low value of SO₂.

The CO-oximeter measures light absorbance at different wavelengths that correspond to the absorption characteristics of deoxyhemoglobin, oxyhemoglobin, carboxyhemoglobin, and methemoglobin, providing a more accurate measurement of SO₂.⁹

The antidote for methemoglobinemia is Methylene blue. Intravenous injection of methylene

blue at a dose of 1-2 mg/kg (0.1-0.2 mL/kg of a 1% solution) is effective in methemoglobinemia.¹⁰ Many physicians also recommend use of ascorbic acid for decreasing oxidative stress, protecting the red blood cell from hemolysis and also reducing methemoglobin formation.¹¹

CONCLUSION

Methemoglobinemia is a life threatening emergency caused due to oxidative stress on the hemoglobin iron chain. It can be caused by congenital or acquired defects. Co-oximetry is the best diagnostic approach, though physical examination and sound clinical knowledge remains by far the best approach. Methylene blue is the antidote of choice in methemoglobinemia. The patient may present with a simple headache to a life threatening comatose state. Brief history taking skill and sound clinical approach is necessary in diagnosing and threatening methemoglobinemia effectively.

Table 1: CAPTION NOT PROVIDED BY AUTHOR

| % MetHb | Symptoms |
|---------|--|
| <15 | Generally asymptomatic |
| 15-30 | Cyanosis, anxiety, light-headedness, fatigue, headache |
| 3-50 | Tachypnea, confusion, syncope |
| 50-70 | Seizures, arrhythmias, metabolic acidosis, coma |
| >70 | Death |

REFERENCES

- Curry S. Methemoglobinemia. *Ann Emerg Med.* 1982 Apr;11(4):214-21.
- Haymond S, Cariappa R, Eby CS, Scott MG. Laboratory assessment of oxygenation in methemoglobinemia. *Clin Chem.* 2005 Feb;51(2):434-44.
- Percy MJ, Lappin TR. Recessive congenital methemoglobinemia: cytochrome b(5) reductase deficiency. *Br J Haematol.* 2008 May;141(3):298-308.
- Bradberry SM. Occupational methemoglobinemia. Mechanisms of production, features, diagnosis and management including the use of methylene blue. *Toxicol Rev.* 2003;22(1):13-27.
- Guay J. Methemoglobinemia related to local anesthetics: a summary of 242 episodes. *Anesth Analg.* 2009 Mar;108(3):837-45.
- Hall RP, Mickle CP. Dapsone. In: Wolverton SE, editor. *Comprehensive Dermatologic Drug Therapy.* 2nd ed. Philadelphia: Saunders; 2007. pp. 239-53.
- Wright RO, Lewander WJ, Woolf AD. Methemoglobinemia: etiology, pharmacology, and clinical management. *Ann Emerg Med.* 1999 Nov;34(5):646-56.
- Nappe TM, Pacelli AM, Katz K. An Atypical Case of Methemoglobinemia due to Self-Administered Benzocaine. *Case Rep Emerg Med.* 2015;2015:670979.
- Barker SJ, Badal JJ. The measurement of dyshemoglobins and total hemoglobin by pulse oximetry. *Curr Opin Anaesthesiol.* 2008;21:805-10.
- Blanc PD. Methemoglobinemia. In: Olson KR, editor. *Poisoning and Drug Overdose.* 3rd ed. Norwalk: Appleton and Lange; 1999. pp. 217-9.
- Atyabi N, Yasini SP, Jalali SM, Shaygan H. Antioxidant effect of different vitamins on methemoglobin production: *An in vitro study.* *Vet Res Forum.* 2012;3:97-101.