

## A Rare Case of Eosinophilic Gastroenteritis

Ashar Khan<sup>1</sup>, Priya Govil<sup>2</sup>, Kishalay Datta<sup>3</sup>

### How to cite this article:

Ashar Khan, Priya Govil, Kishalay Datta. A Rare Case of Eosinophilic Gastroenteritis. Indian J Emerg Med 2020;6(4):275–277.

**Author's Affiliation:** <sup>1</sup>MEM Resident, <sup>2</sup>Consultant, <sup>3</sup>Associate Director and HOD, Department of Emergency Medicine, Max Superspeciality Hospital, Shalimar Bagh, New Delhi 110088, India.

**Corresponding Author:** Priya Govil, Consultant, Department of Emergency Medicine, Max Superspeciality Hospital, Shalimar Bagh, New Delhi 110088, India.

**E-mail:** drpriyasharma5@gmail.com

### Abstract

Eosinophilic gastroenteritis (EGE) is a rare disease characterized by eosinophilic infiltration and peripheral eosinophilia. It can be seen anywhere in the gastrointestinal tract. It is diagnosed in the biopsies taken during endoscopic examination of the patients with abdominal pain and chronic diarrhoea.

A 22 years old Female patient is having Gastroesophageal reflux disease (GERD) presented with complaints of pain in abdomen, centrally located, diffuse in nature, pain exacerbate with food and no relieving factor associated with nausea, vomiting and constipation. On examination abdomen was soft with diffuse tenderness.

In this article we present a case of Pain abdomen associated with vomiting and constipation diagnosed as EGE.

**Keywords:** Gastroenteritis; Eosinophilic.

### Introduction

Eosinophilic gastroenteritis (EGE) may be a rare disease characterised by eosinophilic infiltration and peripheral symptom. It will be seen anywhere within the alimentary canal.<sup>1</sup> The pathologic process isn't absolutely understood however hypersensitivity may be a major issue.<sup>2</sup> Three completely different forms are defined: tissue layer involvement, muscle involvement, and serosal involvement.<sup>3</sup> The primary identification of EGE was created by Kaijser et al. in 1937.<sup>3</sup> It's diagnosed within the biopsies taken throughout examination examination to the patients with abdominal pain and chronic looseness of the bowels.<sup>1,2,4</sup> the amount of diagnosed cases is increasing with the rise in examination procedures.<sup>4</sup>

This is a case of EGE with GERD and pain abdomen.

### Case Presentation

A 22 yrs old Female patient, having GERD presented

with complaints of acute onset pain abdomen, pain was poorly localised associated with nausea, vomiting, constipation and not able to pass flatus. On Per Abdomen examination she is having minimal abdominal distention with generalised tenderness with no palpable lump, no ascites and no hepatosplenomegaly.

### On Examination

Abdomen was soft with diffuse tenderness present with no organomegaly with stable vitals: Pulse Rate: 80/Min, BP: 110/70 MMHG, RR: 18/Min, SPO2: 98% On Room Air, Temp: AFEBRILE.

She was conscious, oriented, mentally stable.

Rest systemic examination was unremarkable

Pt had no known drug or food allergy

Blood Investigations revealed

Hb-11.4gm/dl, TLC-10400/cu mm, LFT-Normal, KFT-Normal, Coagulation Profile-Normal.

USG Abdomen - Done outside - ?Mass in Jejunual area

Plain X - Ray abdomen - Air Fluid levels

CECT Abdomen - Jejuno Jejunal Intussusception

Enteroscopy done, seen upto D4/Proximal Jejunum s/o diffuse proximal small bowel erosions, ulcerations and mucosal edema, no definite narrowing seen.

Biopsy taken for HPE and TB PCR. Imp: ? Eosinophilic Enteritis.

Post procedure histopathology report: Eosinophilic Gastro Enteritis.

*Hospital course and Outcome :*

1. *Regular OPD follow up, Pain abdomen:* Off and on, No fever or any other constitutional symptoms, Managed with PPIs, Repeated USG abdomen - Normal, No significant weight gain.
2. *Second Hospitalization:* She got hospitalized with Pain abdomen again after 2 months, Associated vomiting were present, No GI bleed, No features of Intestinal Obstruction, Clinical examination - Generalized abdominal tenderness, Labelled as Acute Gastritis, All investigations including Amylase were normal, Managed for 2 days and symptoms improved than Discharged.
3. *Third Hospitalization:* She had another episode of severe pain abdomen and vomiting in Nov 2018, She got hospitalized at PSRI, Evaluated extensively, All hematological and Metabolic parameters were normal, Plain X-Ray abdomen, USG abdomen - Normal, CT abdomen - Normal, UGI Endoscopy - Normal, Colonoscopy - A few superficial Ulcers in Terminal Ileum - HPE - Non Specific Ulcers, Capsule Enteroscopy - Capsule got stuck in Jejunum for 4 days, hence no recordings beyond that level.
4. *Fourth Hospitalization:* She was discharged from there as Non Specific Pain Abdomen,

Pain continued and she got hospitalized here in Dec 2018, Clinically - Tenderness all over the abdomen, more in epigastric and umbilical areas, No palpable organomegaly or lump, Re - Evaluation started, All metabolic parameters were normal, Urine porphobilinogen was also normal.

*Radiological investigations:*

- USG abdomen and plain X - Ray abdomen - Normal
- UGI Endoscopy - Normal except nodular mucosa noted in D2
- CT Enterography - Nodularity reported in Jejunum (Fig. 1)
- Enteroscopy - Nodular mucosa in Jejunum - Biopsy taken from 5-6 areas
- Histopathology - Eosinophilic Enteritis (Fig. 2).

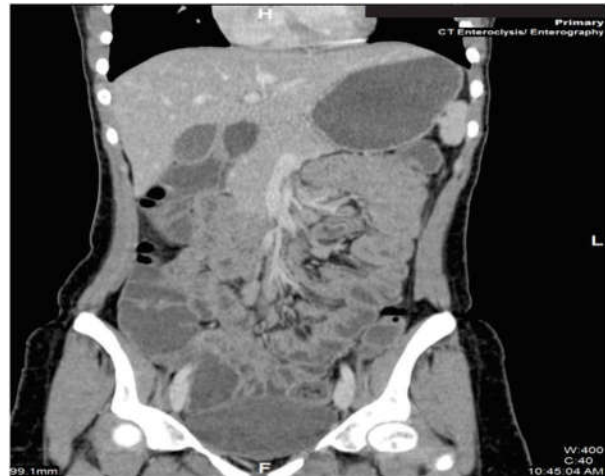

Fig.1: CT Enterography.

*Diagnosis:* Eosinophilic Gastro Enteritis - HPE Proven.

*Treatment:* Gastroenterology consultations were requested and the patient was admitted and treated with Steroids and leukotriene antagonists. Patient respond well to the given treatment and Patient was feeling better and is being discharged in stable condition.

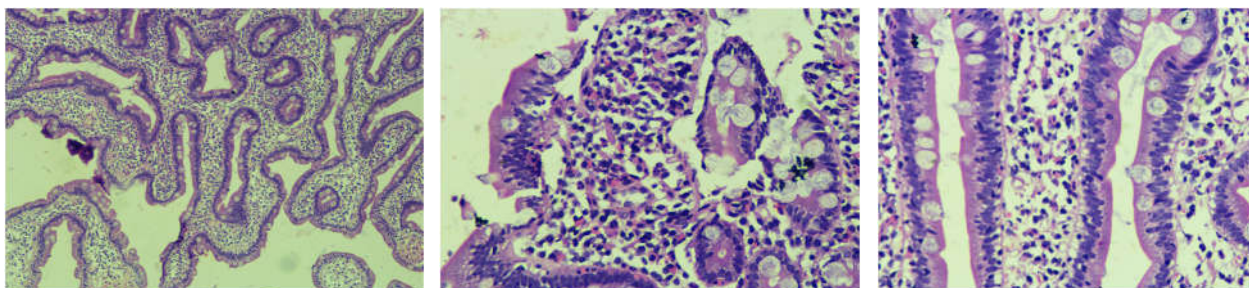


Fig.2: Histopathology.

## Discussion

EGE is a rare disease characterized by eosinophilic infiltration and peripheral eosinophilia. It is difficult to diagnose due to nonspecific symptoms. Gastric or duodenal biopsies are required for confirming diagnosis. The macroscopic appearance is nonspecific. More than 20 eosinophils were determined in each magnification field histologically.<sup>3,4</sup> Reasons (parasites, drug use, malignancy) resulting in eosinophilia must be excluded. EGE are often seen anywhere within the alimentary canal.<sup>1,5</sup>

Because of nonspecific symptoms, the primary step in diagnosing is suspecting EGE. Peripheral eosinophilia is seen in two-thirds of patients.<sup>6</sup> Eosinophilic infiltrations in the biopsy anywhere in the gastrointestinal tract is diagnostic if the other reasons (parasites, drug use, malignancy) are excluded. Because of diffuse involvement, multiple biopsy should be taken from different places.<sup>1,2,4,7</sup> High serum level of IgE is common in these patients. EGE affects both sexes and every one age groups but most of the cases are older than 30 years. It is difficult to work out the particular frequency or prevalence of EGE. Number of diagnosed cases is increasing with the rise in endoscopic procedures but the particular frequency of EGE isn't known.<sup>8</sup>

There is no consensus about the treatment of EGE. There are not enough studies on this. The treatment should be individualized consistent with the patient's age and therefore the severity of the symptoms. The steroids are the most drug within the treatment. Antihistamines (ketotifen), mastocyte stabilizer (oral chromoglycate), and leukotriene antagonists (montelukast) are other drugs which will be utilized in the treatment of EGE.<sup>1,8,9</sup>

The first step in diagnosing is suspecting EGE. It should be borne in mind in patients with chronic diarrhea.

## Conclusion

Since its initial description over seventy years ago, the efforts for characterizing the pathophysiology method and establishing customary diagnostic criteria for Eosinophilic Gastroenteritis are scarce. A nondespicable range of cases are rumoured, that indicates that clinical suspicion is increasing despite its low incidence.

This entity emphasizes the importance of an invasive approach beside a radical medical history; findings on physical examination don't seem to be helpful for reaching the designation, hence being basically histological.

Unlike different varieties of Eosinophilic Gastroenteritis diseases like Eosinophilic esophagitis, there aren't any clinical pointers out there for Eosinophilic Gastroenteritis; so, it'll stay under diagnosed, with unsure prognosis, and as for the patient we will solely supply low evidence-based therapeutic choices.

## References

1. Chen MJ, Chu CH, Lin SC, Shih SC, Wang TE. Eosinophilic gastroenteritis: Clinical experience with 15 patients. *World J Gastroenterol.* 2003;9:2813-6. [PMC free article] [PubMed] [Google Scholar].
2. Kelly KJ. Eosinophilic gastroenteritis. *J PediatrGastroenterolNutr.* 2000;30:28-35. [PubMed] [Google Scholar].
3. Talley NJ, Shorter RG, Phillips SF, Zinsmeister AR. Eosinophilic gastroenteritis: A clinicopathological study of patients with disease of the mucosa, muscle layer and subserosal tissues. *Gut.* 1990;31:54-5. [PMC free article] [PubMed] [Google Scholar].
4. Baig MA, Qadir A, Rasheed J. A review of eosinophilic gastroenteritis. *J Natl Med Assoc.* 2006;98:1616-9. [PMC free article] [PubMed] [Google Scholar].
5. Rothenberg ME. Eosinophilic gastrointestinal disorders (EGID) *J Allergy ClinImmunol.* 2004;113:11-28. [PubMed] [Google Scholar].
6. Straumann A, Simon HU. The physiological and pathophysiological roles of eosinophils in the gastrointestinal tract. *Al-lergy.* 2004;59:15-25. [PubMed] [Google Scholar].
7. Fleischer DM, Atkins D. Evaluation of the patient with suspected eosinophilic gastrointestinal disease. *Immunol Al-lergyClin North Am.* 2009;29:53-63. [PubMed] [Google Scholar].
8. Khan S. Eosinophilic gastroenteritis. *GastroenterolClin North Am.* 2008;37:333-48. [PubMed] [Google Scholar].
9. Furuta GT, Liacouras CA, Collins MH, Gupta SK, Justinich C, Putnam PE, et al. Eosinophilic esophagitis in children and adults: A systematic review and consensus recommendations for diagnosis and treatment. *Gastroenterology.* 2007;133:1342-63. [PubMed] [Google Scholar].

# REDKART.NET

(A product of Red Flower Publication (P) Limited)

(Publications available for purchase: Journals, Books, Articles and Single issues)

(Date range: 1967 to till date)

The Red Kart is an e-commerce and is a product of Red Flower Publication (P) Limited. It covers a broad range of journals, Books, Articles, Single issues (print & Online-PDF) in English and Hindi languages. All these publications are in stock for immediate shipping and online access in case of online.

**Benefits of shopping online are better than conventional way of buying.**

1. Convenience.
2. Better prices.
3. More variety.
4. Fewer expenses.
5. No crowds.
6. Less compulsive shopping.
7. Buying old or unused items at lower prices.
8. Discreet purchases are easier.

URL: [www.redkart.net](http://www.redkart.net)