

Spontaneous Subcutaneous Emphysema and Pneumomediastinum in Young Male Adult

Apurva Chowdhury¹, Santosh Kumar Singh², Uvesh Vaja³

How to cite this article:

Apurva Chowdhury, Santosh Kumar Singh, Uvesh Vaja/Spontaneous Subcutaneous Emphysema and Pneumomediastinum in Young Male Adult/Indian J Emerg Med 2023;9(1):37-40.

Author's Affiliation: ¹Junior Consultant, ²Head of Department, ³Senior Consultant, Department of Emergency, Ramkrishna Care Hospital, Raipur 492001, Chhattisgarh, India.

Corresponding Author: Santosh Kumar Singh, Head of Department, Department of Emergency, Ramkrishna Care Hospital, Raipur 492001, Chhattisgarh, India.

E-mail: drapurvachowdhury25@gmail.com

Received on: 26-11-2022

Accepted on: 28-12-2022

Abstract

Spontaneous pneumomediastinum refers to the presence of air in the mediastinum without any obvious cause. It is an uncommon condition occurring due to alveolar rupture as a result of increased intrathoracic pressure. In this report, we present a case of Subcutaneous Emphysema and Spontaneous Pneumomediastinum. Although there are several causes responsible for this condition, it is extremely rare to occur spontaneously with no prior trauma or predisposing factors, especially in older age groups.

Keywords: Spontaneous pneumomediastinum; Subcutaneous emphysema.

Introduction

Spontaneous pneumomediastinum (SPM) and subcutaneous emphysema (SE) are uncommon conditions. It can be spontaneous or secondary following trauma, hollow organ perforation, iatrogenic injuries, and infections. Spontaneous pneumomediastinum (SPM) is defined as the presence of interstitial air in the mediastinum without any precipitating factors. Spontaneous pneumomediastinum (SPM) was first described by Hamman, hence it's called Hamman's syndrome.¹ It is common among young males in the age group of 20 to 40 years, and has a benign course.^{2,3} The classical triad of presentation includes retrosternal

chest pain, dyspnoea, and subcutaneous emphysema.⁴

We report a rare case of Spontaneous pneumomediastinum (SPM) in a young male who was diagnosed promptly and managed conservatively. Usually, it is self-limiting or may require supportive management only, unless it is caused by a serious underlying pathology of the lungs or associated with critical conditions such as pneumothorax and secondary bacterial pneumonia.

Case Presentation

A 18-year-old male presented to the emergency department with complaints of Sudden onset of

Neck swelling since one day, which gradually progressed to cervical region since last few hours. The patient also complained of Throat pain and Dysphagia. The patient also had a history of intermittent cough for three days. He denied any history of trauma to the neck or any strenuous activity over the past one week. His other medical history was unremarkable. He had no addictions and not undergone any surgeries in the past.

Physical examination revealed a healthy looking young man with mild tachypnoea. His pulse rate was 112 beats/min and blood pressure was 120/70 mmHg, his respiratory rate was 24/min.

On physical examination Crepitations were felt in the neck region extending up to the cervical region. The breath sounds and heart sounds were normal. Other systemic examinations were within normal limits.

Laboratory values (complete blood count, renal function test, electrolytes) and arterial blood gas were within normal limits. His electrocardiogram (ECG) was normal. Urgent X-rays of the chest showed bilateral Subcutaneous Emphysema in the lower part of the neck and upper chest with minimal pneumomediastinum (Fig. 1).

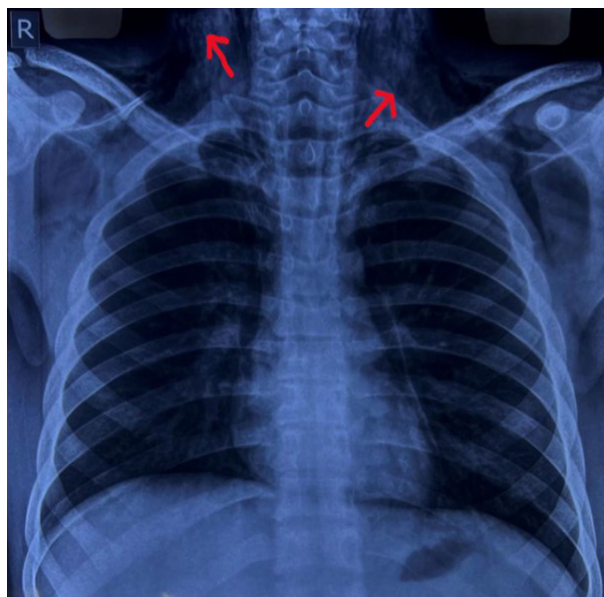


Fig. 1: Anteroposterior Chest X-Ray Demonstrated Subcutaneous Emphysema in the Soft tissue of the Neck

No pneumothorax or pleural effusion was noted. Computed tomographic scan of the head, neck and chest was done which was suggestive of pneumomediastinum (Fig. 2). There was no evidence of any oesophageal perforation, pneumothorax, pleural disease and lung pathology. Upper gastrointestinal endoscopy and bronchoscopy

was also normal. The patient was admitted and managed conservatively. He was given oxygen by mask, analgesics, cough suppressants, and steroid nebulisation. His symptoms settled with conservative management in three days and hence the patient was discharged.

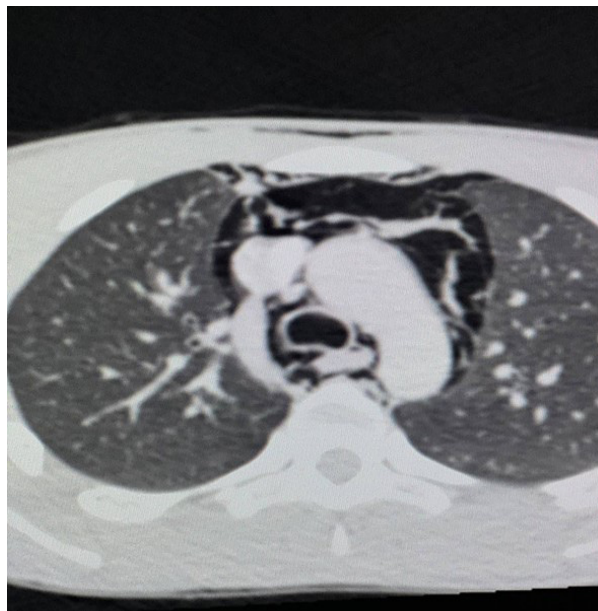


Fig. 2: Contrast-enhanced Computed Tomography (CECT) of the Chest Showing Pneumomediastinum (arrows)

Discussion

Spontaneous Pneumomediastinum (SPM) is a rare entity which was first described by Louis Virgil Hamman in 1939.¹ Secondary pneumomediastinum needs to be differentiated from Spontaneous Pneumomediastinum (SOM) before treating the patient as the causes of secondary pneumomediastinum are different such as iatrogenic injury to the oesophagus due to endoscopy/blunt trauma or as the sequel of lung pathology. SPM is common in young males and in patients with asthmatic disorders. Although our patient was a young male, we could not find any underlying pathology causing SPM.

Rupture of marginal alveoli due to increased alveolar pressure.³ The air ascends along the mediastinum and reaches the subcutaneous tissue and forms subcutaneous emphysema. This kind of presentation is called Hamman's syndrome.

The most common presenting symptoms include, but are not limited to, chest and neck pain, dyspnea, cough, nasal voice, and dysphagia, with signs on examination including tenderness with crepitus sensation over the areas of emphysema,

pulsus paradoxus, tachycardia, and Hamman's sign in cases of massive SE. Our patient also had similar complaints of retrosternal chest pain and neck swelling extending upto cervical region. The general condition of the patients presenting with SPM is usually good with occasional tachypnoea. Clinically subcutaneous emphysema in the neck is the most common sign noticed in about 40%-100% of the population.^{2-4,7,8} In 12% of the individuals, Hamman's sign can be elicited which is crunching sound occurring with every heartbeat.⁴

The diagnosis in SPM is mainly through radiographic images. Chest X-ray with lateral and antero-posterior views is mandatory since small retrosternal pneumomediastinum can be missed in postero-anterior view.⁹ However, in our patient pneumomediastinum and subcutaneous emphysema was evident on chest X-ray. Still, in 30% of the population, SPM can be missed in chest X-ray hence computed tomography (CT) neck and chest are considered the gold standard in the diagnosis.^{6,10,11} We had performed high resolution computed tomography (HRCT) of the thorax as well as contrast enhanced computed tomography (CECT) of the Neck, but we could not find any underlying pathology for the occurrence of subcutaneous emphysema and Pneumomediastinum.

As per history, investigations, and radiology, there was no detectable cause for SPM and SE in our patient, no pre-existing lung disease, or history of trauma/surgery. However, smoking, as well as strenuous physical activities and weightlifting required in daily military training can precipitate the condition along with upper respiratory tract infection leading to the resultant extensive SPM and SE.

Management is mostly conservative which includes adequate rest, oxygen by mask, and analgesia.^{4,5,7,8} Patients respond well to this treatment and can be discharged within two to five days of the in-hospital stay.^{2,7,8} Recurrences have been reported very rarely in the literature.^{5,12,13} Our patient was managed conservatively with oxygen by mask, analgesics, and antibiotics.

Conclusions

Spontaneous pneumomediastinum (SPM) is a rare benign condition which commonly occurs among young men. It should be considered as a differential diagnosis in young patients presenting with complaints of tachypnoea and subcutaneous emphysema. Diagnosis is mainly by imaging studies including chest X-ray and CECT

of the neck and thorax to rule out other causes of pneumomediastinum. Patients usually respond well to conservative management and complete resolution can be expected in two to five days.

References

1. Brown NF, Wong-Taylor LA, Beckles MA: Subcutaneous emphysema. *BMJ*. 2011, 2:11-15. 10.1136/sbmj.d5843.
2. Newcomb AE, Clarke CP: Spontaneous pneumomediastinum: a benign curiosity or a significant problem?. *Chest*. 2005, 128:3298-302. 10.1378/chest.128.5.3298.
3. Macklin MT, Macklin CC: Malignant interstitial emphysema of the lungs and mediastinum as an important occult complication in many respiratory diseases and other conditions: an interpretation of the clinical literature in the light of laboratory experiment. *Medicine*. 1944, 23:281-358.
4. Macia I, Moya J, Ramos R, et al.: Spontaneous pneumomediastinum: 41 cases. *Eur J Cardiothorac Surg*. 2007, 31:1110-4. 10.1016/j.ejcts.2007.03.008.
5. Abolnik I, Lossos IS, Breuer R: Spontaneous pneumomediastinum: a report of 25 cases. *Chest*. 1991, 100:93- 5. 10.1378/chest.100.1.93.
6. Koullias GJ, Korkolis DP, Wang XJ, Hammond GL: Current assessment and management of spontaneous pneumomediastinum: experience in 24 adult patients. *Eur J Cardiothorac Surg*. 2004, 25:852-855. 10.1016/j.ejcts.2004.01.042.
7. Weissberg D, Weissberg D: Spontaneous mediastinal emphysema. *Eur J Cardiothorac Surg*. 2004, 26:885-8. 10.1016/j.ejcts.2004.05.050.
8. Campillo-Soto A, Coll-Salinas A, Soria-Aledo V, Blanco-Barriob B, Flores-Pastora M, Candel-Arenasa M, Aguayo-Albasinia JL: Spontaneous pneumomediastinum: descriptive study of our experience with 36 cases [Article in Spanish]. *Arch Bronconeumol*. 2005, 41:528-31. 10.1016/s1579-2129(06)60274-7.
9. Ba-Ssalamah A, Schima W, Umek W, Herold CJ: Spontaneous pneumomediastinum. *Eur Radiol*. 1999, 9:724- 27. 10.1007/s003300050742.
10. Kaneki T, Kubo K, Kawashima A, Koizumi T, Sekiguchi M, Sone S: Spontaneous pneumomediastinum in 33 patients: yield of chest computed tomography for the diagnosis of the mild type. *Respiration*. 2000, 67:408- 11. 10.1159/000029539.
11. Sakai M, Murayama S, Gibo M, Akamine T, Nagata O: Frequent cause of the Macklin effect in spontaneous pneumomediastinum: demonstration by multidetector row computed tomography. *J Comput Assist Tomogr*. 2006,

- 30:92-4. 10.1097/01.rct.0000187416.07698.8d.
12. Freixinet J, García F, Rodríguez PM, Santana NB, Quintero CO, Hussein M: Spontaneous pneumomediastinum long-term follow-up. *Respir Med.* 2005, 99:1160-3. 10.1016/j.rmed.2005.02.025.
13. Gerazounis M, Athanassiadi K, Kalantzi N, Moustardas M: Spontaneous pneumomediastinum: a rare benign entity. *J Thorac Cardiovasc Surg.* 2003, 126:774-6. 10.1016/s0022-5223(03)00124-71.
14. Rosinhas JFAM, Soares SMCB, Pereira ABM: Hamman's syndrome. *J Bras Pneumol.* 2018, 44:433.10.1590/S1806-37562018000000180

