

## Interceptive Orthodontics in Developing Malocclusion Using 2x4 Appliance: Case Report

Ayesha<sup>1</sup>, Krishna Priya Vellore<sup>2</sup>, Prem Shankar Chauhan<sup>3</sup>, Santosh Kumar Challa<sup>4</sup>,  
Mayuri Ganesh<sup>5</sup>, Niharika Sowki<sup>6</sup>, K Saigeeta<sup>7</sup>

### How to cite this article:

Ayesha, Krishna Priya Vellore, Prem Shankar Chauhan, et al./Interceptive Orthodontics in Developing Malocclusion Using 2x4 Appliance: Case Report/Indian J Dent Educ. 2022;15(2):57-59.

### Abstract

Children developing malocclusion in the mixed dentition period are frequently delayed for treatment until all permanent teeth erupt. A stage of transition from primary to permanent dentition is the time period which mainly presents with malocclusion due to various factors. Among the problems most frequently seen in the mixed dentition period is anterior cross-bite. Interceptive orthodontics is usually carried out to reduce the severity of developing malocclusion.

This case report includes case series of patients with different forms of malocclusion such as cross bite correction and correction of rotated single tooth treated with 2x4 appliance respectively. Anterior cross bite in early mixed dentition can have long term effects on growth and development. This appliance is used in early mixed dentition for both anterior cross bite and alignment of incisors. Treatment of younger children in the early mixed dentition period offers advantages in terms of stability and avoidance of future complications.

**Keywords:** Keywords: 2x4 appliance; Mixed dentition; Early treatment.

**Key Messages:** Treatment of younger children in the early mixed dentition period offers advantages in terms of stability and avoidance of future complications.

### INTRODUCTION

Children having malocclusion in the mixed dentition period are frequently delayed for treatment until all permanent teeth erupt.<sup>1</sup> A stage of transition from primary to permanent dentition

is the time period which mainly presents with malocclusion due to various factors. Recently, much discussion in literature is regarding ideal timing to initiate orthodontic treatment.<sup>2</sup> Many aspects of orthodontics have been taken into consideration, such as the clinical effectiveness, the orthodontists' preference, the outcome of early treatment, and psychological influences associated with it (*Tulloch et al.*, 1997; *Yang*, 1998).<sup>5</sup> This article presents 2 case reports of patients treated by using 2x4 appliances.

### CASE: 1

A 9 year old male reported to the Department of Pedodontics and Preventive Dentistry, with a chief complaint of irregularly placed upper front teeth since 1 year. There was no significant

**Author's Affiliation:** <sup>1,3</sup>Post Graduate Student, <sup>2</sup>Professor and Head of Department, <sup>4,5</sup>Reader, <sup>6,7</sup>Senior Lecturer, Department of Pediatric and Preventive Dentistry, Army College of Dental Sciences, Secunderabad 500087, Telangana, India.

**Corresponding Author:** Krishna Priya Vellore, Professor and Head of Department, Department of Pediatric and Preventive Dentistry, Army College of Dental Sciences, Secunderabad 500087, Telangana, India

**E-mail:** [krishnapriyavllr@gmail.com](mailto:krishnapriyavllr@gmail.com)

**Received on:** 26.05.2022

**Accepted on:** 10.06.2022

family or medical history. Extra oral examination revealed straight profile of the patient. Intra oral examination revealed U-shaped arch with Class I molar relationship and distobuccal rotated 21 along with distal migration of 21. Orthopantomograph and lateral cephalogram of the patient was taken

and space analysis was done to measure the arch length discrepancy. Clinical examination revealed Class I molar relation, with deep bite. 2x4 fixed orthodontic treatment was planned. Alignment was done using 0.012 NiTi stainless steel wire. Results were achieved in 2 months.

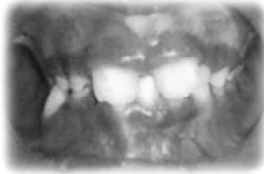

Fig. 1: Pre-operative

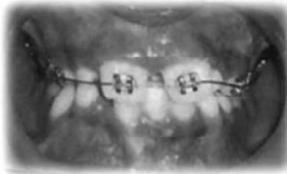


Fig. 2: Operative

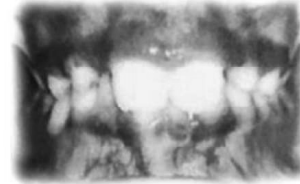

Fig. 3: Post-operative

## CASE: 2

A 10 year old male had reported to the department of pedodontics and preventive dentistry with the chief complaint of irregularly placed upper front teeth. On examination, 12, 11, 22 were found in cross bite. This was treated using a 2x4 appliance, as it engages both the maxillary first permanent molars and central incisors, lateral incisors in its set up. 0.022" slot brackets were bonded onto the anterior

teeth and buccal tube was cemented on maxillary first permanent molars of both quadrants. 0.012 Round NiTi wire was used initially for alignment for 1 month followed by 0.014 NiTi wire for 2 months. One important modification done in this case was placing the bracket on the first premolar bilaterally till lateral incisors erupted in occlusion plane, then bonding it on both the lateral incisors. This was done to prevent debonding and extended length of treatment.

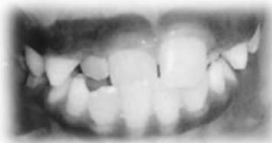

Fig. 4: Pre-operative

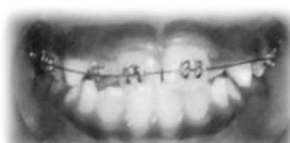

Fig. 5: Operative

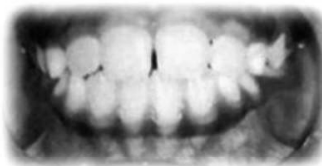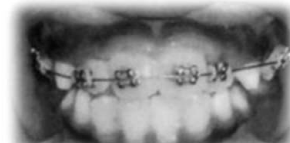


Fig. 6: Post-operative

## RECALL

Recall examination after every 1 month is continued without any relapse.

## CONCLUSION

The two case reports described clearly demonstrate the versatility of using the 2x4 appliance. Even though greater chairside time would be required for placement of appliance, there is no laboratory cost involved as with a removable appliance. The advantages over this type of appliance are

significant and include bodily movement of teeth if space needs to be created for an instanding incisor or recreated for an impacted late erupting incisor, torque of the incisor roots palatally to decrease the chance of relapse, as well as maximize the aesthetic result by efficient and effective de-rotation of incisors.<sup>14</sup> The functional improvement coupled with the obvious psychological benefit gives this simple and easily placed appliance a significant advantage over the traditional method of treating these potentially challenging mixed dentition problems.<sup>5</sup>

## ACKNOWLEDGEMENT

I am overwhelmed in all humbleness and gratefulness to acknowledge my depth to all those who have helped me to put these ideas, well above the level of simplicity and into something concrete. I would like to express my special thanks of gratitude to my Head of the Department, Dr. Krishna Priya Vellore, as well as our staff Dr. Santosh Kumar CH, Dr. Mayuri Ganesh, Dr. Niharika S, Dr. K Saigeeta, who gave me golden opportunity to do this wonderful case report on the topic "Interceptive Orthodontics in Developing Malocclusion Using 2x4 Appliance", which also helped me in many new things. I am really thankful to them.

Any attempt at any level can't be satisfactorily completed without the support and guidance of my colleague Dr. Prem Shankar Chauhan, my seniors Dr. Divya Banu M and Dr. Milan Singh Mali, and my juniors Dr. Geetika and Dr. Kanchan. Last but not the least I would like to thank my patients and their parents for trusting me and giving me this opportunity.

*Conflict of Interest:* NIL

## REFERENCES

1. Anterior Crossbite Correction in Early Mixed Dentition Period Using Catlan's Appliance: A Case Report. *ISRN Dent.* 2010;2011:298931.
2. Bhola M and Gera T. Orthodontic Intervention in Mixed Dentition: A Boon for Pediatric Patients. *IDA Lud J-le Dent* 2018;2(2):10-16.
3. Kushwah A, Kumar M, Jaiswal A, Shailesh T. An Introduction to interceptive orthodontics. *TUM J Dent* 2017;4(3):118-120.
4. Rohilla M, Bodh M, Kumar A, Namdev R. Early Interception Using 2x4 Appliance: A Case Series. *International Journal of Advances in Case Reports*, 4(7), 2017, 226-229.
5. P. Dowsing and P. J. Sandler. How to effectively use a 2X4 appliance. *Journal of Orthodontics*, Vol. 31, 2004, 248-258.
6. Dr. Parikrama J. Solanki, Dr. Shantanu R. Choudhari, Dr. Chirag M. Vaghela and Dr. Sandip I. Saxena . 2017. "Use of Two by Four Appliance: A Treatment Modality for the Correction of Malaligned Maxillary Anterior Teeth during Mixed Dentition Period.", *International Journal of Development Research*, 7, (12).
7. Loli D. The versatility of the 2X4 appliance. *WebmedCentral > Review articles*.
8. Sandler, Jonathan. (2004). Features section: How to effectively use a 2x4 appliance. *Journal of orthodontics*. 31. 248-58. 10.1179/146531204225020541.
9. E & Tunc, Emine. (2008). Treatment of Anterior Dental Crossbite Using Bonded Resin-Composite Slopes: Case Reports. *European journal of dentistry*. 2. 303-6.
10. Bindayel NA. Simple removable appliances to correct anterior and posterior crossbite in mixed dentition: Case report. *Saudi Dent J.* 2012;24(2):105-13.
11. Savas S, Candabakoglu N, Kucukyilmaz E, Veli I. Management of incomplete transposition of mandibular lateral incisor using removable appliances: Two case reports. *J Pediatr Dent* 2014;2:105-9.
12. Negi KS. Mandibular incisor-canine transposition; an interceptive treatment perspective. *J Indian Orthod Soc* 2015;49:156-60.
13. Watted N, Abu-Hussein M (2016) Dental Transposition of Mandibular Canine and Lateral Incisor. *J Dent Probl Solut* 3(1): 045-049. 10.17352/2394-8418.000034.
14. Ulusoy, A. T., & Bodrumlu, E. H. (2013). Management of anterior dental crossbite with removable appliances. *Contemporary clinical dentistry*, 4(2), 223-6