

Crown Lengthening By Laser Technique: Different Cases

Tanveer Fatima*, Venkatesh Babu D.B.**

Abstract

Crown lengthening procedure often required to enhance the appearance of patient smile. Whether they performed for the purpose of exposing sound tooth structure, or to enhance the appearance of the definitive restorations, these procedures must be planned to satisfy biologic requirements, while simultaneously avoiding deleterious esthetic effects. A variety of laser has been used for hard tissues and soft tissue procedure for crown lengthening in dentistry. This study describe crown lengthening procedure done by using Nd:yag and Er:yag for both hard and soft tissues. Nd:yag (1064nm) was used for soft tissue crown lengthening and Er:yag (2940nm) was used for hard tissue lengthening, and discussing the observed changes with two types of lasers for the period of one month.

Keywords: Laser; Crown Lengthening; Soft Tissue Laser; Hard Tissue Laser; Crown Esthetics.

Introduction

Laser has been in use for many years, especially in medical field since 1980s. But now they have made their advent into dentistry as well, making their presence in a noticeable manner. Various uses of laser in dentistry include gingival curettage, gingival retraction, crown lengthening, root canal disinfection and other procedures. When prosthetic rehabilitation of a tooth is done with the crown, if there is inadequate crown length this requires crown lengthening to be done to increase the length of a crown. Crown lengthening can be done by various procedures such as conventionally with scalpel, electro surgery, orthodontic extrusion, and laser. Laser are fast becoming preferable to conventional crown lengthening methods because they are painless, healing faster, less bleeding, less time in dental chair, reduced risk of infection, minimizing need for suturing, less migration or rebounding gingival tissue coronally.

Author's Affiliation: *Assistant Professor, **PG Student, Department of Prosthodontics and Crown and Bridge, Al-Badar dental college and hospital, Gulbarga, Karnataka.

Reprints Requests: Tanveer Fatima, Assistant Professor, Department of Prosthodontics and Crown and Bridge, Al-Badar dental college and hospital, Gulbarga, Karnataka.

E-mail: tan22@gmail.com

Aims and Objective

Present study was carried out in the department of prosthetic dentistry to evaluate effect of laser crown lengthening specifically Nd:yag, Er:yag on crown lengthening procedure. The study was done to assess the rebounding effect of gingival tissue post operatively.

Materials and Method

The study was performed on ten systemically healthy patients, who required minimum of 2mm crown lengthening. Laser used in the study are Nd:yag(1064nm), Er:yag(2940)

Nd:yag

Wave length-1064nm

Fiber diameter-300mm

Working distance-contact mode

Emission mode-free running pulse

Er:yag

Wave length-2940

Working distance-7mm with a noncontact mode

Spot diameter-0.9mm

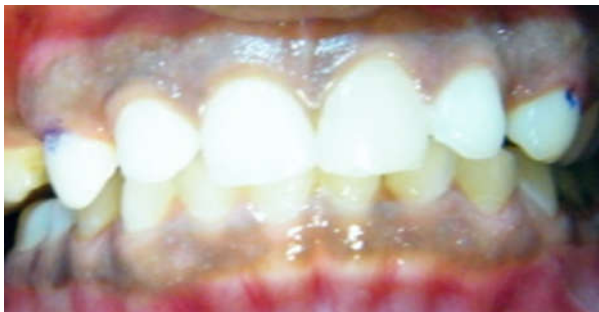Emission mode-free running pulse

Round bur was used with the diameter of 2mm

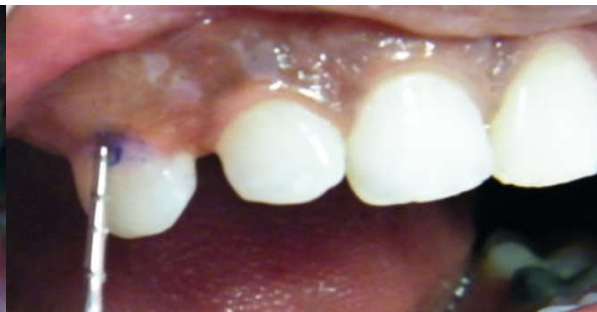Case selection was done depending upon the biological width and in teeth where crown height was less for prosthetic replacement. Informed consent was taken from the patient. Before the start of the crown lengthening procedure by laser, ditch was made on the tooth with the round bur at the gingival level pre operatively and the ditch was marked with methylene blue to evaluate the present condition of gingival. Then the clinical procedure were performed with laser Nd:yag and Er:yag .After crown lengthening one more ditch was made and marked with methylene blue at present position of the gingival.

In total 10 cases for 6 cases crown lengthening was done by soft tissues Nd:yag laser and 4 cases were done by hard tissue Er:yag laser. The patient were recalled weekly for one month and the distance between two ditches with both the procedure were evaluated and no changes or gingival migration was observed in our study .A study by Dent et al concluded that there is considerable tissue instability or rebounding for up to six month following traditional crown lengthening surgery,when compared to the crown lengthening done by erbium for osseous crown lengthening were there less coronal proliferation or gingival recession .After one month tooth preparation was done and fixed partial denture placed.

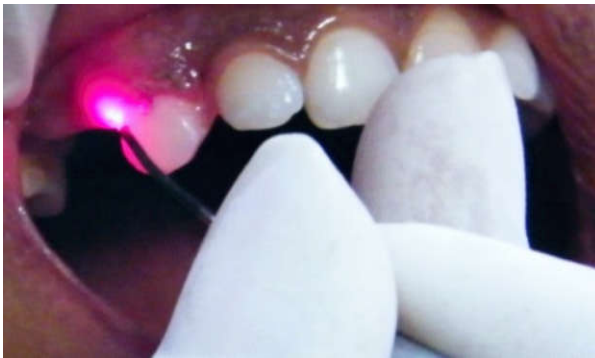Case 1



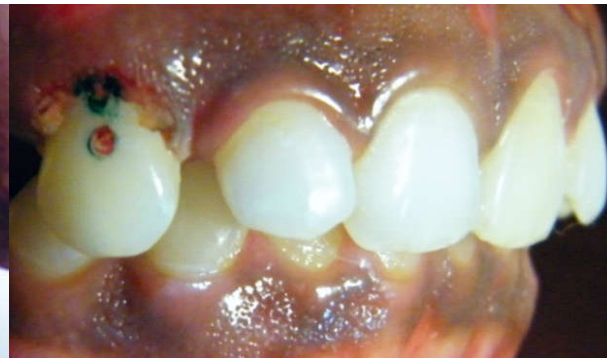Pre-operative



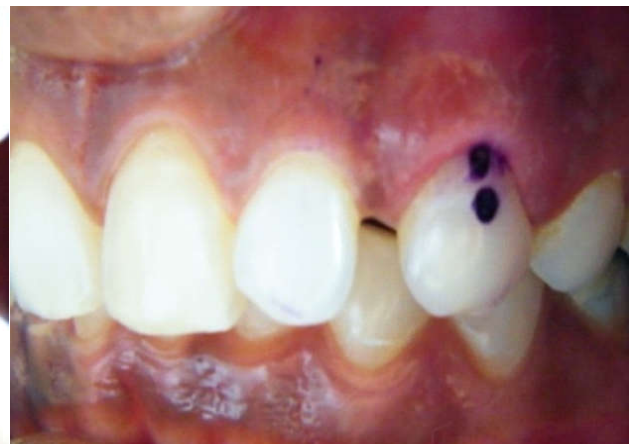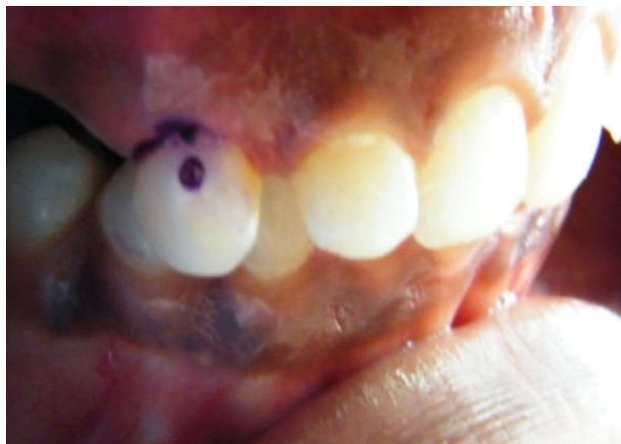Depth of the marginal gingiva



Crown lengthening by laser Nd;YAG

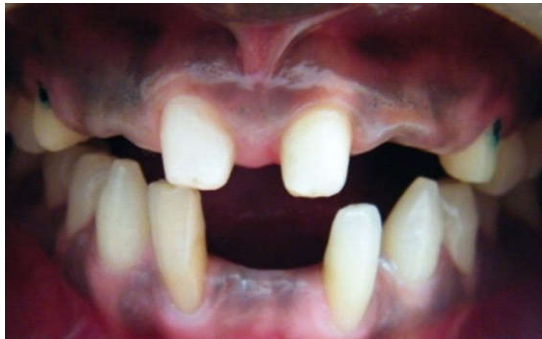

Post Operative

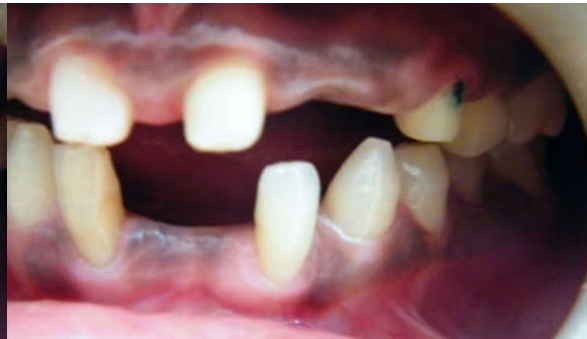

Recall check up

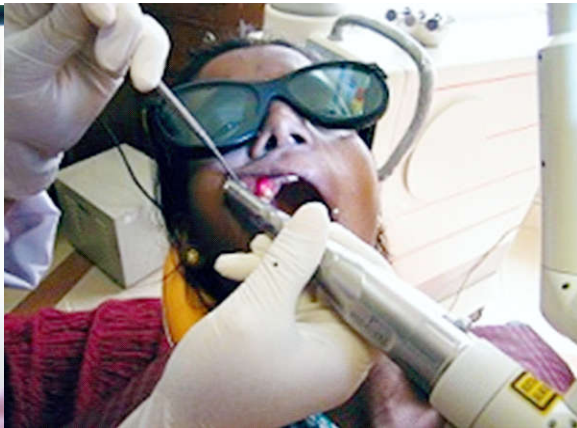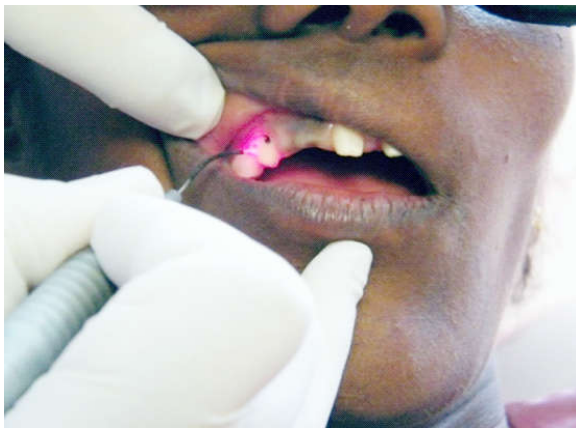Case 2



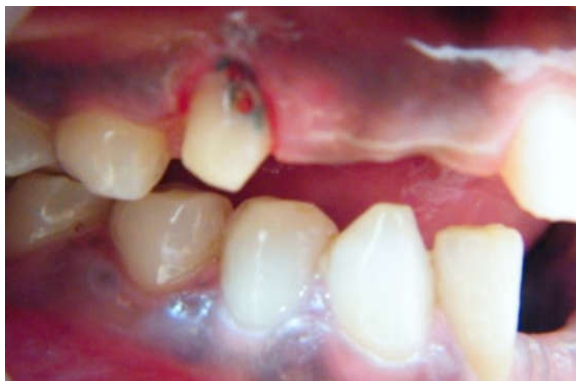Pre-operative



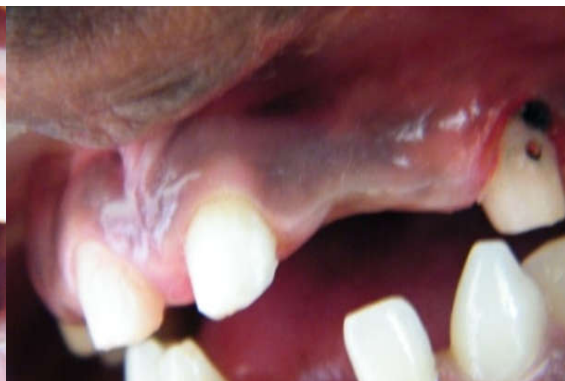Pre-operative



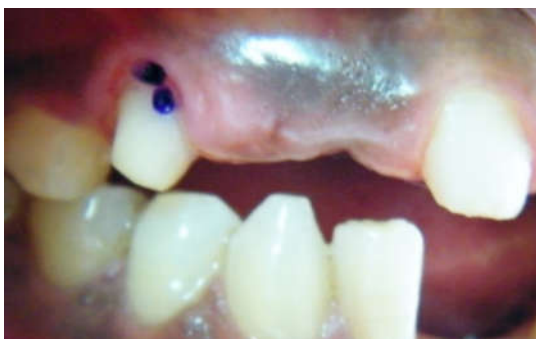Crown lengthening by Er: YAG lasera



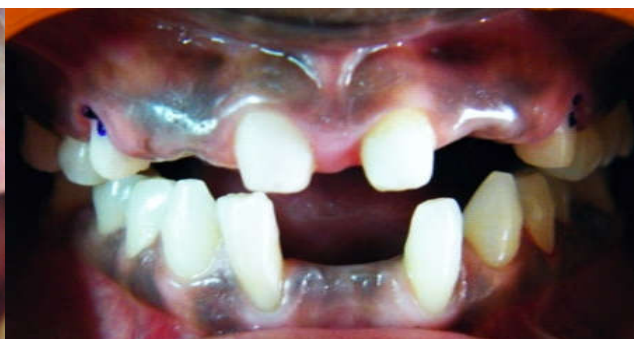Post-operative



Post-operative

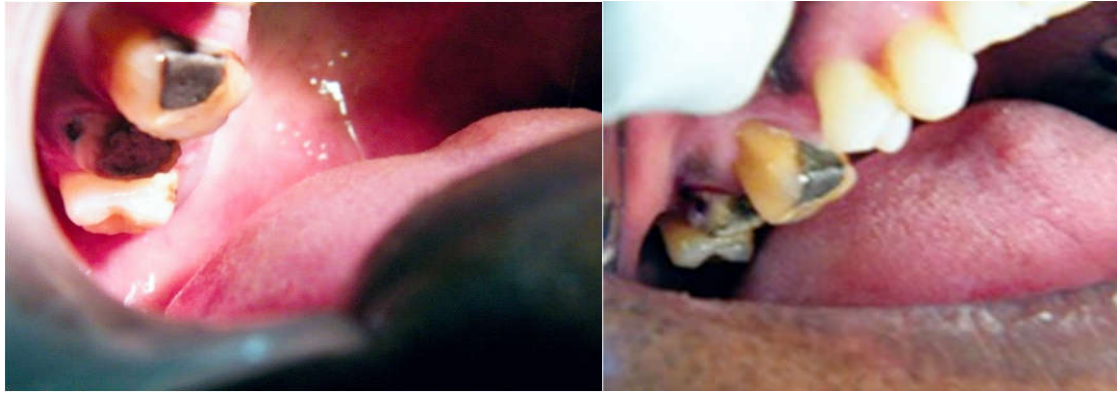

Recall check up



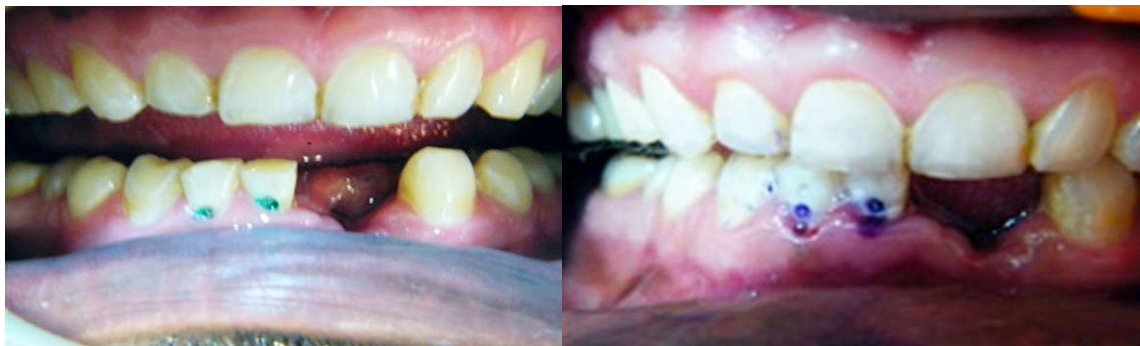Recall check up

Case 3



Pre-operative

Post-operative



Pre-operative

Post-operative

Result

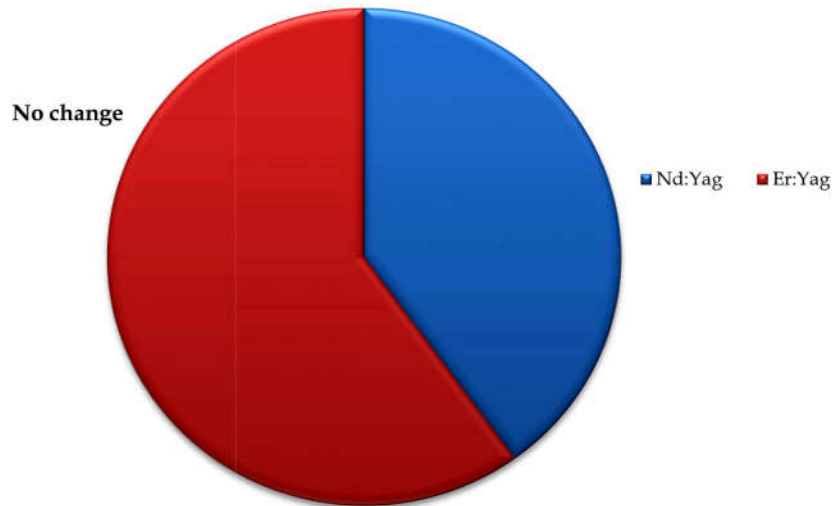
Crown lengthening procedures are traditionally being performed using conventional method. However, with the introduction of lasers in dentistry crown lengthening by lasers are being performed with promising results.

Study was carried using Nd:yag and Er:yag lasers to find out any change in the gingival contour after

crown lengthening by lasers.

Utilizing this we have made an attempt to analyze effect of change in size and shape of gingival contour which has been reevaluated for 4 weeks postoperatively for about one month.

The result shows that there was no change in gingival contour with both Nd:yag and Er:yag laser during recall checkup.



References

1. Coluzzi DJ. Lasers in dentistry: the future is here. *Contemp Esthetics*. 2006; 10(5): 14-17.
 2. Lee EA. Laser-assisted gingival tissue procedures in esthetic dentistry. *Pract Proced Aesthet Dent*. 2006; 18(9): 2-6.
 3. Camargo PM, Melnick PR, Camargo LM. Clinical Crown Lengthening in Esthetic Zone. *C D A Journal*. 2007; 35(7): 487- 498.
 4. Cohen DW. Lecture, Walter Reed Medical Center, 1962 June 3.
 5. Kois J, The restorative-periodontal interface: biological parameters. *Periodontology* 2000, 1996; 11: 29-38.
 6. Wennstrom JL, Heijl L, Linde J. *Periodontal Surgery: Access Therapy*. Clinical Periodontology & Implant dentistry. 4th edition.
 7. Smukler H, Chaibi M. Periodontal and dental considerations in clinical crown extension. A rational basis for treatment. *Int J Periodontics Restorative Dent*. 1997; 17: 464-77.
 8. Minimally Invasive Osseus Crown Lengthening Procedure using Erbium Laser-Brett Dyer
 9. Fundamentals of dental lasers -Science and instruments- Dental Clinics of North America 2004.
 10. Surgical crown lengthening-12 month Clinical wound healing study-Journal of Periodontology 2001.
 11. Osseous surgery for crown lengthening -A 6 months clinical study-Journal of Periodontology 2004.
 12. Padbury A Jr, Eber R, Wang H-L. Interactions between the gingiva and the margin of restorations. *J Clin Periodontol*. 2003; 30: 379-385.
 13. Pick RM. Using lasers in clinical dental practice. *J Am Dent Assoc*. 1993; 124(2): 37-44.
 14. Magid KS, Strauss RA. Laser use for esthetic soft tissue modification. *Dent Clin North Am*. 2007; 51(2): 525-545.
 15. Flax HD, Radz GM. Closed-flap laser-assisted esthetic dentistry using Er:YSGG technology. *Compend Contin Educ Dent*. 2004; 25(8): 622, 626, 628-630, 632, 634.
-