

A Case Report on Root Coverage of Miller's Class 2 (2A) Recession by Coronal Repositioning Flap

Pooja Bharadwaj

Author's Affiliation: Assistant Professor, Rishiraj College of Dental Science & Research Centre, Bhopal 462036, Madhya Pradesh, India.

Corresponding Author: Pooja Bharadwaj, Assistant Professor, Rishiraj College of Dental Science & Research Centre, Bhopal 462036, Madhya Pradesh, India.

Email: bharadwajpooja628@gmail.com

How to cite this article:

Pooja Bharadwaj/A Case Report on Root Coverage of Miller's Class 2 (2A) Recession by Coronal Repositioning Flap/Indian J Dent Educ. 2021;14(2): 51-58.

Abstract

Gingival recession is one of the common feature of Periodontitis. Gingival recession is defined as an apical shift in the position of gingiva. This gingival recession is particularly of concern as in terms of esthetics, hypersensitivity and caries. Various root coverage Procedures are available for the root coverage of the recession defects. One of the Procedure is the coronal repositioning of flap to attain root coverage. Present case report is on a 41 years old male, who was having class 2(2A) recession defect whose concern were particularly hypersensitivity. So root coverage procedure was planned, in order to cover the recession defect so as to eliminate the patient chief complaint of hypersensitivity and to achieve esthetics.

Introduction

Chronic Periodontitis is defined as the inflammation and infection of the supporting structures of the teeth. Periodontitis is identified by many clinical features like presence of pockets, mobility, bone loss, clinical attachment loss and recession. Among them recession is defined as an apical shift in the position of gingiva.¹

Recession is of clinical concern particularly as it leads to hypersensitivity, esthetically unacceptable and caries. There are many clinical causes of recession apart from periodontitis like toothbrushing trauma, tooth malposition (particularly labially), orthodontic treatment, high frenal attachment.² Various classification of recession had been proposed which have undergone modification over the past few years. These recession system classification are as follows:³

1. Sullivans and Atkins(1968): Was based on depth and width of the defect:
 - a. Deep wide
 - b. Shallow wide
 - c. Deep narrow
 - d. Shallow narrow
2. Mlinek et al (1973): Was based upon depth and width of the defect:
 - a. Shallow narrow
 - b. Deep wide
3. Liu and Slot (1980): Based upon marginal tissue recession:
 - a. Visual - Measured from CEJ to soft tissue margin.
 - b. Hidden- Measured from CEJ to apical to tissue margin.

4. Bengue et al (1983): According to coverage prognosis:
 - a. U type: Poor prognosis
 - b. V type: Fair Prognosis
 - c. I type: Good Prognosis
5. Millers Classification (1985): Based upon the final amount of root coverage.

Class 1: Marginal tissue recession that does not extend to the mucogingival junction. There is no soft tissue loss or the interdental bone loss.

Class 2: Marginal tissue recession that extends to the mucogingival junction. There is no soft tissue loss or the interdental bone loss.

Class 2a: Recession in which most apical extension is apical to the mucogingival junction, but there is still a margin of keratinized tissue apically to the exposed root area.

Class 2b: Recession in which apical limit extends into alveolar mucosa. There is no remaining keratinized tissue apical to exposed area.

Class 3: Recession in which the loss of interdental bone or soft tissue is apical to the cemento-enamel junction, but coronal to the most apical extent of recession. Interproximal attachment loss is less than the facial attachment loss. Marginal tissue recession reaches or extends beyond the mucogingival junction. The tooth may be slightly malpositioned/rotated or extruded, and the papillae do not fill the interdental spaces as far as the contact point.

Class 4: Recession in which interproximal bone loss extends apical to the most apical extension of recession. The amount of interproximal bone loss is greater than the facial attachment loss. Marginal tissue recession extends beyond the mucogingival junction. The tooth is severely malpositioned/rotated/extruded. The papillae do not fill the interdental spaces as far as the contact point.

6. Nordland and Tarnow (1998): A classification system for the loss of papillary height:
 - a. *Normal:* Interdental papilla fills the embrasure space to the apical extent of interdental contact point/area.
 - b. *Class 1:* Tip of the interdental papilla lies between the interdental contact point and the most coronal extent of interproximal cemento-enamel junction.
 - c. *Class 2:* Tip of the interdental papilla lies at or apical to the interproximal cemento-enamel junction but coronal to the apical extent of the facial cemento-enamel junction.

- d. *Class 3:* Tip of the papilla lies level with or apical to the facial cemento-enamel junction.
7. Mahajan Classification (2010):
 - a. *Class 1:* Gingival recession defect not extending to the mucogingival junction.
 - b. *Class 2:* Gingival recession defect extending to the mucogingival junction or beyond it.
 - c. *Class 3:* Gingival recession defect with bone or soft tissue loss in the interdental area up to cervical one third of root surface and or malpositioning of the tooth.
 - d. *Class 4:* Gingival recession defect with bone or soft tissue loss in the interdental area greater than cervical one third of the root surface, and or severe malpositioning of the tooth.
8. Kumar and Masamatti (2013): Recession classification for facial surfaces of maxillary teeth, and facial and lingual surfaces of mandibular teeth.

Class 1: There is no loss of interdental bone or soft tissue.

Class 1 a: Gingival margin on the facial/lingual aspect lies apical to cemento-enamel junction but coronal to the mucogingival junction with attached gingiva present between marginal gingiva and mucogingival junction.

Class 1 b: Gingival margin on the facial/lingual aspect lies at or apical to the mucogingival junction with an absence of attached gingiva between marginal gingiva and mucogingival junction.

Class 2: Tip of the interdental papilla is located between interdental contact point and the level of cemento-enamel junction midbuccally/midlingually. Interproximal bone loss is visible on the radiograph. It is divided into three types:

Class 2A: There is no marginal tissue recession on the facial /lingual aspect.

Class 2B: Gingival margin on the facial/lingual aspect lies apical to cemento-enamel junction but coronal to mucogingival junction with attached gingiva present between the marginal gingiva and the mucogingival junction.

Class 2C: Gingival margin on the facial/lingual aspect lies at or apical to mucogingival junction with the absence of attached gingiva between the marginal gingiva and the mucogingival junction.

Class 3: Tip of the interdental papilla is located at or below the level of cementoenamel junction midbuccally/midlingually. Interproximal bone loss is visible on the radiograph.

Class 3A: There is no marginal tissue recession on the facial /lingual aspect.

Class 3B: Gingival margin on the facial/lingual aspect lies apical to cementoenamel junction but coronal to mucogingival junction with attached gingiva present between the marginal gingiva and the mucogingival junction.

Class 3C: Gingival margin on the facial/lingual aspect lies at or apical to mucogingival junction with the absence of attached gingiva between the marginal gingiva and the mucogingival junction.

Among the above mentioned classification, Millers Classification is considered the most appropriate to diagnose type of gingival recession due to the fact that it is easier to understand, and clinically proven.

There are various types of root coverage procedure available for treating the recession. These procedures are classified into two categories.⁴

1. Pedicle flaps: those flaps which maintains an intact blood supply with the donor site. Example: Lateral Pedicle flap, semilunar flap, Coronal repositioning flap.
2. Free soft tissue flaps: those flaps which do not maintain their connection with the donor site after root coverage.

Example: Free gingival graft, connective tissue graft, subepithelial connective tissue graft.

Case Report

Present case report is on a 41 year old male patient, whose chief complaint was hypersensitivity with respect to upper left front and back tooth region. On examination, the patient had non contributing medical history, Millers class 2 (2A) recession defect. So after the clinical examination, coronally repositioned flap was planned.

Non-surgical Periodontal therapy was carried out. After two weeks of non surgical periodontal therapy, patient was recalled for the coronal repositioning flap procedure. Local anaesthesia was given, and the procedure was initiated by giving a crevicular incision and oblique papillary incision. After the incisions full thickness mucoperiosteal flaps were reflected beyond the mucogingival junction. After full thickness flap reflection, root surface debridement was done, and the flap was

sutured by means of 3-0 silk sling suture.⁵

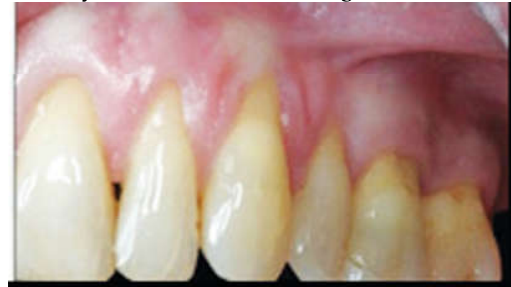

Fig. 1: Preoperative photograph, Showing Millers Class 2(2A).

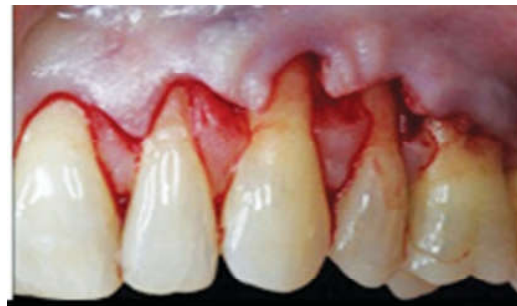

Fig. 2: Crevicular and papillary oblique incision.

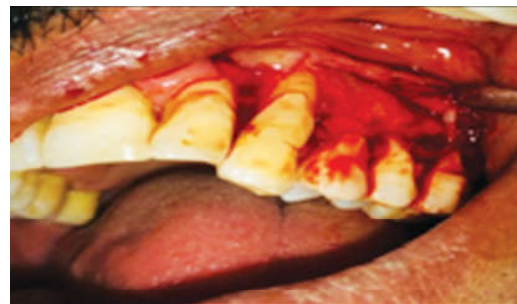


Fig. 3: Flap Reflection

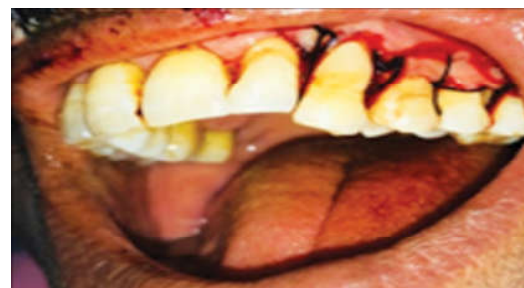

Fig. 4: Flap closure by 3-0, Silk sling suture.

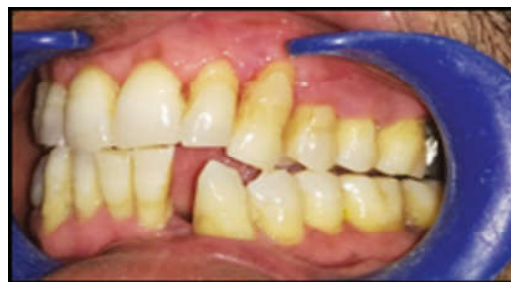

Fig. 5: Follow up 3 months showing, Complete root coverage.

Post Surgical Management

Following coronal repositioning flap procedure, the patient was instructed to avoid brushing over the operated site, for two weeks and to use chemical method of plaque control that is Chlorhexidine mouth wash 0.2% for two weeks, followed by normal resume of toothbrushing after 2 weeks, along with continuation of chlorhexidine mouthwash for four weeks. Toothbrushing should be resumed using soft toothbrush and keep the operated area as much as clean as possible.⁶

Discussion

Recession is one of the characteristic feature of the periodontal disease. There are various causes of recession apart from periodontitis such as toothbrush trauma, orthodontic trauma, occlusal trauma, faulty prosthesis, prominent facial tooth position. Recession is of both clinical and esthetic concern as it can lead to hypersensitivity, esthetically unacceptable, caries.² Various types of gingival recession classification have been given, beginning from 1963 till 2013. Among all these classification given, Millers Classification given in 1985, is followed till date as it is clinically proven and easier to understand.³ There are various procedures for root coverage, and each procedure holds its clinical significance.

Clinically these root coverage procedures are classified into two categories. One is the pedicle flap, which maintains a contact with the donor site. Examples of Pedicle flaps include lateral pedicle flap, coronally repositioning flap, apically displaced flap. The other flap is the free soft tissue flaps, which do not have any contact with the donor site. Examples of free soft tissue flaps include free gingival graft, connective tissue graft, and subepithelial connective tissue graft.⁴ The case which was done was of a coronal repositioning flap on a 41 year old male patient whose chief complaint was hypersensitivity in the upper left front and back tooth region.

The reason for choosing the coronal repositioning flap in this patient was due to the fact that the recession was in a multiple teeth, the thickness, and width of the gingival was adequate, and the excellent color matching of the donor tissue.⁵ According to Haung et al, the presence of vestibular keratinized gingiva with the thickness of at least 1.2 mm, gives the possibility to raise a mucosal flap which after repositioning, guarantees a complete root coverage without the need for connective tissue graft.⁷ In the

study by Cairo et al, evaluating the study of root coverage procedure, using coronally repositioning flap with and without the connective tissue graft, an increase of gingival thickness of about 90% was observed using coronally repositioning flap without connective tissue graft.⁸ In the case report presented, patient had Millers class 2 (2A), recession in maxillary left front and back tooth region with the chief complaint of hypersensitivity, so coronally repositioned flap was planned without vertical releasing incision. The result showed complete root coverage after 3 months.

Conclusion

Recession is one of the findings in the field of periodontology. There are many causes of recession. It is the duty of the clinician to thoroughly evaluate patients periodontal status as well as the general health status and should confirm the cause of recession so as to treat it accordingly. Various procedures for root coverage are available. Among them one of them is coronal repositioning of flap, with or without vertical incisions. This flap serves as an excellent predictor for complete root coverage, provided that there is an adequate thickness of gingiva and most better suitable if the recession defect involves multiple teeth, if there is not much clinical attachment loss, and the recession comes under Millers Class 1 or Class 2 recession defect.

References

1. Fermin A, Michael G. Clinical Periodontology. Eight edition.
2. Zucchelli G. Mucogingival Esthetic Surgery.
3. Guttiganur N et al. Classification systems for gingival recession and suggestion of new classification system. Indian J Dent Res 2018;29:233-7.
4. Lindhe J. Clinical Periodontology and Implant Dentistry. Fifth Edition.
5. Rose L. Periodontics Medicine, Surgery, and Implants.
6. Cohen E. Atlas of Cosmetic and Reconstructive Periodontal Surgery. Third Edition.
7. Haung L et al. Factors affecting the outcome of coronally advanced flap root coverage Procedure. J Periodontal 2005;76,1729-1734.
8. Cairo F et al. Clinical efficacy of coronally advanced flap procedure with or without connective tissue graft for the treatment of multiple adjacent gingival recession in the esthetic area: A randomized control clinical trial. J Clinical Periodontal .2016;43,849-856.