

An Ayurvedic Approach for Low Back Ache with Congenital Deformity: A Case Report

Shreelaxmi Chaganti¹, Manjiri Nitin Patil²

Author Affiliation: ¹Physician, ²Assistant Professor, Department of Panchakarma, Shri Acharya Deshbhushan Ayurvedic Medical College, Bedkihal, Belgaum, Karnataka 591214, India.

Corresponding Author: Manjiri Nitin Patil, Assistant Professor, Department of Panchakarma, Shri Acharya Deshbhushan Ayurvedic Medical College, Bedkihal, Belgaum, Karnataka 591214, India.

E-mail: vdnagasri@gmail.com

Abstract

A male patient aged 41yrs visited OPD with chief complaints of low back pain, increased stiffness and associated with constipation since 3yrs. Past history revealed congenital deformity of short right leg and flat feet. The patient had low back pain since 18 years for which surgery was advised, aggravated since 3 yrs. Radiological assay (MRI) revealed postero central disc protrusion at L4-L5, diffuse disc bulge at L2-S1 level causing compression on anterior thecal sac. The case diagnosed as katigraha (Lumbar spondylosis) and treated with anulomana (normalising the movement of vata), Tiktaksheera basti (type of therapeutic enema), external Sthanika Abhyanga (local oleation) and Patrapinda sweda (type of sudation therapies). These measures resulted in significant relief of 75% in pain, stiffness and numbness even on prolong sitting. Patient had follow-up of 3 months and presented with further improvement in the condition.

Keywords: Kati graham; Tikta ksheera basti; Disc protrusion; Disc bulge; Lumbar spondylosis.

How to cite this article:

Shreelaxmi Chaganti, Manjiri Nitin Patil. An Ayurvedic approach for low back ache with congenital deformity: A Case Report. Indian J Ancien Med Yog. 2020;13(3):145-148.

Introduction

This case is considered to be special, as the patient had low back ache with congenital deformity of short right leg and flat feet. The gait with difference in length of limbs was maintained by mild limping and had impact on low back i.e lumbar spine. Stiffness and pain proceeded with structural changes in lumbar vertebrae of the patient. Here, this pathology differs from regular spinal pathologies as continuous pressure is exerted on lumbar spine because of wrong posture, travelling and gait due to congenital deformity which he had mild limping gait from childhood. Ayurveda treatments were able to relieve these symptoms significantly in a chronic case with 18 years duration where surgical rectification was the prime choice.

Pain and stiffness in lumbar region is considered under katigraha type of Vatavyadhi (musculoskeletal disorder). In ayurveda kati refers

to low back region and graha to stiffness which presents symptoms of pain, stiffness, restricted and painful movements.¹ The above condition treated on the principles of Vatavyadhi in which oleation therapy (internal and external routes) is the prime modality.² Administration of Internal oleation by therapeutic enema is a choice of treatment in these disorders. External oleation is administered in the form of different local therapies along with sudation therapies³ which have ability to relieve pain and stiffness.⁴ Hence it is a case treated with above principles and was found to be effective clinically.

Case History

A 41 year old male vegetable merchant complaining of low back pain, increased stiffness, associated with constipation and occasional mild numbness in feet after prolonged sitting, aggravated since

3 yrs was approached Panchakarma OPD. Past history reveals occurrence of symptoms from 18 years which was increased since three years. Occupational history reveals travel of 50-60 km by riding two wheeler vehicle on uneven surface every day for past 18 years.

Investigation: Radiological investigation revealed that Postero central disc protrusion of L4-L5 causing compression on the anterior thecal sac and traversing nerve roots. Diffuse disc bulges at L2-L3, L3-L4, and L5-S1 with focal annular tear at L2-L3 L5-S1 causing compression on anterior thecal sac.

On Physical Examination: Inspection revealed GALS as

Gait- Mild limping

Arms-Normal

Legs- Short right leg and flat feet

Spine-increased lumbar lordosis

Patient was able to perform complete forward flexion, extension and painful bilateral flexion reaching his fingertips to the level of knee.

On palpation grade II tenderness was appreciated at the level of L3-L5, with minimal swelling in the same area. SLR and Flip test were found negative. The patient had normal deep tendon and superficial reflexes.

Treatment (Panchakarma procedures): After ascertaining nirama lakshanas⁵ (corrected state of metabolism), Anulomana (Proper evacuation of urine, stools and flatus) was administered with trivrit Lehya⁶ 25gm (major ingredient is Operculina terpenhium) with warm water as Koshtashodhana (aiming for cleansing of Gastro Intestinal tract) and for normalising the movement of Vata on first day.

Second day external oleation in the form of mild sthanika abhyanga (local massage) performed by

Mahanarayantaila⁷ from lumbar region to soles. Local sudation was followed with patra pinda sweda (bolus of leaves) made out of nirgundi (Vitexnigundo Linn.), eranda (Ricinuscommunis Linn.), chincha (Tamarindusindica Linn.) and coconut scrapings.

Local oleation was administered with katibasti (oil retention on lumbar region) followed by sthanika abhyanga and patrapinda sweda from low back to both lower limbs from third day.

Internal oleation was started from fourth day in the form of yoga Basti (sequential administration of two types of enema) medicated oil enema and medicated milk decoction enemas and the external treatments were continued.

Table 1 shows Sequential Administration of Basti.

Anuvasanabasti (nourishing retention enema) was administered with *sahacharaditaila*⁸ (major ingredient *Barleriapronitis* Linn.) 40ml + *dhanwantara taila*⁹ (major ingredient *Sidacordifolia* Linn.) 40ml in the afternoon after food. Alternative administration of ksheerabasti (evacuation enema with milk infusion processed by herbal drugs) performed on empty stomach in the morning.

Table 2 shows the contents of decoction enema.

Results

The patient had 3 bouts of purgation with administration of thivrit lehya 25 gm on first day. This was resulted in mild reduction of stiffness. Significant improvement was found in the stiffness and pain after starting external oleation and sudation therapies

Profound increase in relief of stiffness and pain was evident in the patient during the course of

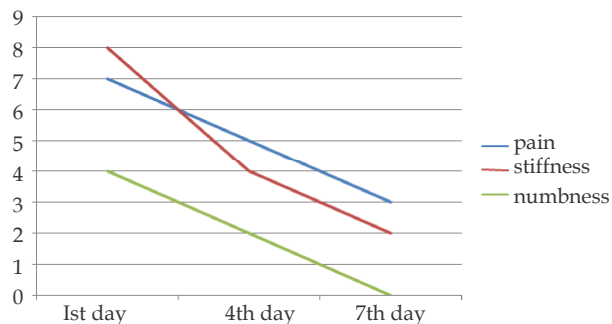
Table 1: Sequential Administration of Basti.

| | | | | | |
|-----------------------|---------------------|---------------------------------|---------------------------------|---------------------------------|---------------------|
| Morning-Empty Stomach | | Milk decoction evacuating enema | Milk decoction evacuating enema | Milk decoction evacuating enema | |
| Afternoon-After food | Oil retention enema | Oil retention enema | Oil retention enema | Oil retention enema | Oil retention enema |

Table 2: The contents of decoction enema.

| Name of the ingredient | Quantity |
|--|---------------------------|
| Honey (Madhu) | 60ml |
| Rock salk (Saindhavalavana) | 5 gm |
| Panchatiktaghtita (preparation of five bitterherbs with ghee base) + Lakshaditaila (LaceiferlaccaKer.) | Each 40ml (Total 80ml) |
| Shatapushpa (Anethumsowa Kurz.) Arjuna (Terminaliaarjuna Rohb.) | 30 gms |
| Milk decoction of Balamoola (Sidacordifolia Linn.), Aswagandha (Withaniasomnifera Linn.) | 300ml |
| Yastimadhu(Glycyrrhizaglabra Linn.) | |

therapeutic enema. His walking distance increased from ½ km to 2 km without any discomfort.



The Fig. 1 demonstrates overall relief of stiffness, pain and numbness assessed by VAS scoring on first, fourth and seventh day of the treatment.

Conclusion

The lumbar pathologies commonly seen include degeneration of disc, disc bulge and protrusion, herniation etc. Disc degeneration is where chemical changes associated with aging cause weakening of discs. These changes cause variation in the form or position of the disc with slight impingement into the spinal canal called a bulge or protrusion. Protrusion of the nucleus posteriorly causes pressure over the nerve roots, spinal cord and other internal contents, which causes pain in the limbs, motor and sensory deficit.¹⁰ The above deficits are related with musculoskeletal disorder called katigraha (stiff painful low back) in Ayurveda. The condition has causative factors like heavy work, excess driving, walking with heavy weights.¹¹ In conventional system of medicine treatment being administration of muscle relaxants, NSAIDS, corticosteroids, physiotherapy etc. gives transient relief. In advance stages surgical intervention is suggested, which is expensive with enormous neurological deficits.¹² Here Ayurveda intervention plays major role and is also non-invasive. The approach of treatment is combination of external oleation, internal oleation (therapeutic enema), and different sudation therapies and mild purgation.¹³

Mild purgation was advised on first day for relieving stiffness and painful condition. This medicine (trivrit lehya) exerts profound anti-inflammatory, anti-spasmodic and detoxifying effect which favours tissue regeneration¹⁴ apart from its purgative action.

External oleation performed in the form of mild local massage with medicated oil (mahanarayana taila) soothes the muscle. Ingredients mentioned in this formulation are established for analgesic¹⁵

with anti-inflammatory effect.¹⁶ The local sudation posted following oleation with bolus of medicinal leaves increases circulation acting as anti-spasmodic. This relieves guarding of muscle further reducing stiffness. The specific duration of massage for 30 minutes expected to reach the Majja dhatu (bone marrow tissue).¹⁷

Katibasti (Retention of oil on lumbar region) is a modality exerting both effect of oleation and sudation. It exerts both mechanical and physiological effects. Mechanical effect is understood by vasodilation in the region due to retention of hot oil for stipulated time with uniform temperature. Lymphatic vessels also dilated which enhances the collection and removal of local debris occurred during the wear and tear of the muscle. This favours the patency of channels facilitating for pool of fresh blood, triggering healing process. Physiological effect is because of the nature of disc. It is made up of soft gelatinous materials which are lipid based and nourished by osmosis phenomenon from the above vertebrae. The oils used for oleation procedure are lipid based and absorbed by osmosis. The availability of the substances with common properties (lipid based disc and oil), favours the regeneration and repair of the same tissue (disc). After the disc regaining its structure and consistency sets in position and pressure on the nerve root is released relieving pain, stiffness and tension of muscle.

Basti (therapeutic enema) is prime line of treatment for vatavyadhis (musculoskeletal and neurological disorders).¹⁸ Because of profound vasculature in the rectum, drugs administered through trans rectal route can cross the rectal mucosa like other lipid membrane and bypass first drug degradation. Thus unionized and lipid soluble substances are readily absorbed from the rectum.¹⁹ The oil administered during retention type of enema possess major ingredients like (sahachara), Sidacordifolia Linn. (bala) have been proven efficacious for acute and sub-acute anti-inflammatory activities.²⁰

Ksheerabasti (evacuation enema) is a formulation specified for asthimajjavikaras (bone tissue disorders).²¹ The preparation of enema is by sequential triturating of the following ingredients like honey, salt, oil (lipid base), paste of herbal powders, water based milk infusion of Withaniasomnifera Linn. (aswagandha), Sidacordifolia Linn. (balamoola), Glycyrrhizaglabra Linn. (yastimadhu), Terminaliaarjuna (arjuna) drugs. The amalgamation formed is lipophilic and hydrophilic in nature similar to the histology

of rectum. Bulk administration of enema creates osmotic gradient and expels toxins, cleanses bowel favouring for the absorption of the potency of the drugs in short period. As the drug comes in direct contact with haemorrhoidal plexus, potency of drug is believed to reach systemic circulation. *T. cordifolia* used in the formulation has ability to down regulate the expression of COX-2 gene and inhibit platelet aggregation²² which relieves inflammation and pain and indicated as good therapeutic potential. *Aswagandha* is popular drug established for rejuvenating activity that favours the regeneration of the tissue.²³ This complete formulation possesses drugs of anti-arthritic, anti-inflammatory and anti-spasmodic which may help in disc bulge and protrusion.

References

1. Dr. Sajitha K. An Insight to Katigraha (Low back ache). *Ancient science of life*. 2001; 21(1):16-17.
2. Trikamji AJ, editor. *Charaka Samhita*. Varanasi: Chaukhambha Surbharati Prakashan; 2011. "28th Adhyaya" Chikitsa sthana; p. 621.
3. Hari Sadasiva Saatri Paradakara, editor. *Ashtanga Hrudaya*. Varanasi: Chaukhambha Surbharati Prakashan; 2010. "4th Adhyaya" Sutra sthana; p. 211.
4. Trikamji AJ, editor. *Charaka Samhita*. Varanasi: Chaukhambha Surbharati Prakashan; 2011. "22nd Adhyaya" Sutra sthana; p. 120.
5. Hari Sadasiva Saatri Paradakara, editor. *Ashtanga Hrudaya*. Varanasi: Chaukhambha Surbharati Prakashan; 2010. "13th Adhyaya" Sutra sthana; p. 216.
6. Hari Sadasiva Saatri Paradakara, editor. *Ashtanga Hrudaya*. Varanasi: Chaukhambha Surbharati Prakashan; 2010. "2nd Adhyaya" Kalpa sthana; p. 742.
7. Prof. Siddhi Nandan Mishra, editor. *Bhaishajya Ratnavali*. Varanasi: Chaukhambha Surbharati Prakashan; 2007. "26th Adhyaya" Vativyadhi rogadohikara; p. 547.
8. Hari Sadasiva Saatri Paradakara, editor. *Ashtanga Hrudaya*. Varanasi: Chaukhambha Surbharati Prakashan; 2010. "21st Adhyaya" Chikitsa sthana; p. 727.
9. Hari Sadasiva Saatri Paradakara, editor. *Ashtanga Hrudaya*. Varanasi: Chaukhambha Surbharati Prakashan; 2010. "2nd Adhyaya" Sharira sthana; p. 383.
10. <http://www.spinecareindia.in/What-is-Disc-Prolapse.html>.
11. <http://www.spinecareindia.in/What-is-Disc-Prolapse.html>.
12. http://www.chirogeek.com/001_Tutorial_Birth_of_HNP.htm#Treatment.
13. Hari Sadasiva Saatri Paradakara, editor. *Ashtanga Hrudaya*. Varanasi: Chaukhambha Surbharati Prakashan; 2010. "4th Adhyaya" Sutra sthana; p. 211.
14. Kohli K.R, Nipanikar S.U, Kadbhane K.P. A Comprehensive Review on Trivrit [*Operculina Turpethum* Syn. *Ipomoea Turpethum*]. *International J. of Pharma and Bio Sciences*. 2010; 1(4): 443-52.
15. RK Sutradhar, AKM. Motior Rahman, MU Ahmad, B.K. Datta, SC Bachar, A Saha. Analgesic and anti-inflammatory activities of *Sida Cordifolia* Linn. *Indian J. Pharmacol*. 2006; 38(3):207-08.
16. Shailender S, Praveen P, Siddappa D. Evaluation of Anti-inflammatory activities of *Sidacordifolia* Linn in Albino rats. *J. Chem. Pharm. Res*. 2011; 3(6):136-142.
17. Trikamji AJ, editor. *Susruta Samhita*. Varanasi: Chaukhambha Surbharati Prakashan; 2010. "24th Adhyaya" Chikitsa sthana; p. 488.
18. Trikamji AJ, editor. *Charaka Samhita*. Varanasi: Chaukhambha Surbharati Prakashan; 2011. "25th Adhyaya" Sutra sthana; p. 131.
19. Dr. M.R. Vasudevan Nampoothiri, Dr. L. Mahadevan, first edition. *Principles and Practice of Vasti*; p. 173-74.
20. Shailender S, Praveen P, Siddappa D. Evaluation of Anti-inflammatory activities of *Sidacordifolia* Linn in Albino rats. *J. Chem. Pharm. Res*. 2011; 3(6):136-142.
21. Trikamji AJ, editor. *Charaka Samhita*. Varanasi: Chaukhambha Surbharati Prakashan; 2011. "28th Adhyaya" Sutra sthana; p. 180.
22. Jaijesh P, Srinivasan KK, Arunachalam K, Sreejith, Govindan, Ciraj AM, Raju SK, et. al. Anti-Arthritic Activity of the plant *Tinospora Cordifolia* Willd. *J of Herbal Medicine and Toxicology*. 2011; 5(1): 11-16.
23. Venil N Sumantra, Asavarikul Karni, Sanjay Boddul, Trushna Chinchwade, Soumya J Koppikar, Abhay Harsulkar, et. al. Chondroprotective potential of root extracts of *Withania somnifera* in osteoarthritis. *J. Biosci*. 2007; 32(2): 299-307.

