

A Prospective Randomised Study Comparing Placement of I-Gel and ProSeal LMA by Fiberoptic Bronchoscopy in Anaesthetised Adults undergoing Elective Surgery

Shristi Srivastava¹, Pallavi Ahluwalia², Sangeeth S³

Author's Affiliation:

^{1,3}Resident, ²Professor, Department of Anesthesiology, Teerthanker Mahaveer Medical College, Moradabad, Uttar Pradesh 244001, India.

Abstract

Context: Supraglottic airway devices (SGAs) are tools used for airway management in anaesthesia and provide a good alternative to tracheal intubation. Comparison of I-gel and ProSeal LMA (PLMA) was done because of time taken for insertion, fiberoptic view of the larynx, ease of Ryle's tube insertion, and post-operative sore throat assessment.

Methods and Material: In the present prospective, randomized study instead of manner, 60 adult patients of the American Society of Anaesthesiologists I-II of either gender between 18 and 60 years presenting for an elective surgical procedure, under general anaesthesia were enrolled. The airway was secured using either the I-gel or PLMA. An experienced non-blinded anaesthesiologist inserted appropriate sized I-gel or PLMA in patients using standard insertion technique and compared both devices in terms of time taken for insertion, effective seal, fibre optic view of the larynx, number of attempts, and hemodynamic changes during insertion.

Results: The time required for insertion of I-gel was lesser (14.32 ± 1.23 and 20.23 ± 1.82 s in Group I and Group P, respectively; $P < 0.001$). The numbers of attempts for successful insertions were comparable and in the majority, the device was inserted in the first attempt. The fiber optic view of glottis was better with I gel (p -value=0.048), hemodynamic changes and incidence of complications were comparable in both groups.

Conclusions: The time required for successful insertion of I-gel was shorter in adult patients undergoing a surgical procedure under general anesthesia on controlled ventilation. The fibre optic view of the glottis was better with the proseal indicating better utility as a conduit for intubation.

Keywords: I-gel; PLMA; Time for insertion; Fiberoptic scoring.

How to cite this article:

Shristi Srivastava, Pallavi Ahluwalia, Sangeeth S/A Prospective Randomised Study Comparing Placement of I-Gel and ProSeal LMA by Fiberoptic Bronchoscopy in Anaesthetised Adults undergoing Elective Surgery/Indian J Anesth Analg. 2021; 8(5): 495-502.

Corresponding Author: Pallavi Ahluwalia, Professor, Department of Anesthesiology, Teerthanker Mahaveer Medical College, Moradabad, Uttar Pradesh 244001, India.

Email: drpallaviahlwalia@yahoo.com

Introduction

Extraglottic airway devices (EADs) – synonyms may be supraglottic airway devices (SADs, SGAs) or supralaryngeal airways (SLA) – are an integral part of modern anaesthetic practice.^{1,2} They are helpful in certain situations outside the operating room.³ Supraglottic airway devices (SADs) have been widely used as an alternative to tracheal intubation during GA.⁴ They are easy to place, better tolerated, with decreased hemodynamic changes, have favorable respiratory mechanics, and decreased airway morbidity.⁵ The recent guidelines on CPR also recommend the use of SADs as a substitute for tracheal intubation.⁶

ProSeal LMA (PLMA; Laryngeal Mask Company, Henley-on-Thames, UK), was developed with a modified cuff. The dorsal cuff helps to form a better seal over the peri-laryngeal area.⁷ PLMA also possesses a gastric tube running simultaneously with the airway tube through which gastric content. The I-gel supraglottic airway device was designed for overcoming the limitations of PLMA.⁸

The I-gel airway (Intersurgical Ltd, Wokingham, Berkshire, UK) is a recent supraglottic airway device composed up of a thermoplastic elastomer (SEBS, styrene-ethylene butadiene styrene) with a soft durometer (hardness) and gel-like feel. The mask of the I-gel is developed anatomically to fit the perilaryngeal and hypopharyngeal structures without the use of an inflatable cuff, thereby avoiding compression trauma related to the cuff.⁹

Fibreoptic scoring is used as a measure of anatomic position in studies on laryngeal mask airway devices and higher scores may be associated with an improved seal, reduced work of breathing, and easier intubation. Hence, we designed this study with the primary aim to compare the placement of the two devices (ProSeal LMA and I-gel) via fiberoptic assessment.

Subjects and Methods

This prospective randomized clinical study was conducted after clearance from the Board of Studies and Ethical committee, in the Department of Anesthesiology, tertiary teaching institute in central India, during the period 2018-2019.

The study change to sample was calculated by using G-power software with 80% of the power and 5% of the significance level. The total sample size was determined to be 58; we enrolled 60 subjects [10] to account for any dropouts. All patients were

selected as per inclusion and exclusion criteria. We included ASA grade I/II patients, aged 18-60yrs, with body mass index 18.5-22.9kg/m² undergoing short elective surgery (less than 120mins). Patients with anticipated difficult airway and pre-operative sore throat were excluded from the study. These 60 patients were allocated into two groups of 30 each by closed envelope technique. Randomisation was done using the chit method and was divided into two groups i.e. Group I: I-gel, Group P: ProSeal LMA. A detailed history, complete physical examination, and routine & appropriate investigations were done for all patients.

All patients were given Tablet alprazolam 0.5 mg orally at bedtime on the previous night of surgery and were kept nil per oral for 8 h before surgery. On operating table standard monitoring using multipara monitor such as pulse oximeter, noninvasive blood pressure, and five lead electrocardiogram was connected. Intravenous (IV) access with 18 gauge cannula and Ringer's lactate infusion was started. Patient was pre-medicated with Injection Glycopyrrolate 0.01 mg/kg IV, Injection Midazolam 0.05 mg/kg IV, Injection Fentanyl 1.5µg/kg IV, Injection Ondansetron 0.1mg/kg IV and then preoxygenation was done with 100% oxygen for 3 min.

Induction was done with Injection Propofol 2.5 mg/kg IV and Injection Rocuronium 0.6mg/kg IV was used to achieve neuromuscular blockade. The patient was kept in a sniffing position before device insertion.

Patients were ventilated and after the adequate depth of anaesthesia has been achieved, each device was inserted by an experienced anaesthesiologist after lubrication of the posterior surface with water-based jelly. Depth was assessed by assessing jaw relaxation, loss of verbal contact, at a minimal alveolar concentration of Isoflurane of 1. Size of SGA was calculated according to patient's body weight (size 3: Bodyweight between 30 and 60 kg; size 4: 50-90 kg; size 5: >90 kg).

ProSeal LMA was inserted (prior lubricated with water-based jelly) using a smooth circular rotating movement until the device reached the hypopharynx and definite resistance was felt. Then the cuff was inflated with an adequate amount of air and the pressure of the cuff adjusted till 60 cm H₂O. I-gel was inserted with the concavity of the I-gel facing the mandible using a pen-holding grip and inserting the device till it fits over the larynx. An effective airway was confirmed by bilateral symmetrical chest movement on manual

ventilation, square wave capnography, the absence of audible leak of gas, and lack of gastric insufflations and ingress and egress of gases by auscultation in front of the neck of the patient. Three attempts of insertion were taken. The factors considered for the failure of the proper placement of the device were failure to introduce into the pharynx, ineffective ventilation (inadequate chest rise, abnormal capnogram), and drop in SpO₂. If placement failed even after three attempts, the airway was secured through other airway devices as suitable and the case was excluded from our study. After securing the device in place, a well-lubricated 16 F gastric tube was introduced into the stomach through the gastric drainage port.

Time for the successful placement of the device, number of attempts for placement, fiberoptic grading of the larynx, and ease of Ryle's insertion was assessed and noted by the anaesthesia consultant. During the insertion of the device, the number of attempts for the successful insertion and time taken for successful insertion of the device (timed from picking up the device till the appearance of the capnographic trace) was recorded. After successful ventilation is established, a 3.5 mm flexible fiberscope (Richard Wolf) was inserted into the SAD using a bronchoscopy adapter by an examiner.

The bronchoscope was advanced to the distal orifice of the SGA and a picture of the best possible glottic view was taken and graded by an observer according to the following grading system, introduced by Brimacombe and Berry.¹¹

- a. Full glottis view - Grade 1
- b. Glottic aperture partially visible - Grade 2
- c. Glottic aperture not visible- Grade 3

Anesthesia was maintained with nitrous oxide, oxygen mixture (N₂O: O₂ 70:30), and Isoflurane 1% connected to Drager Fabius machine and put on volume mode and intermittent boluses of Rocuronium was administered IV. Paracetamol infusion IV 15 mg/kg was given intraoperatively. At the end of the surgery, anaesthetic agents were discontinued, and the neuromuscular block was reversed with Injection Glycopyrrolate 0.01 mg/kg IV, Injection Neostigmine 0.05 mg/kg IV allowing smooth recovery of consciousness. The device was removed after the patient regained consciousness and breathes spontaneously and responded to the verbal command to open the eye.

Various Parameters were assessed like the fiberoptic view of glottis according to

Brimacombe and Berry grading, hemodynamic parameters (pulse rate, systolic, diastolic BP, MAP, SPO₂). The number of attempts for successful LMA insertion, time is taken for LMA insertion, and complications if any. Data were analyzed using SPSS version 19.0 for Windows. The time for successful insertion of the device was compared between the groups using independent samples 't' test.

The number of attempts for the successful device was compared using the chi-square test. Fiberoptic view through the device, ease of Ryle's tube insertion, blood on device after removal, and postoperative sore throat assessment were analyzed using Fisher's exact test. A P value <0.05 was regarded as significant.

Results

Patient characteristics like age, sex, BMI were comparable between the two groups [Table 1]. The comparison of mean HR and SpO₂ was done and no significant difference was observed [Figure-1]. The MAP and at 10 minutes was significantly more among the ProSeal LMA group in comparison to the I-gel group (Figure 2). The number of attempts of successful insertion was significantly more with ProSeal as compared with I-gel (p-value = 0.038) (Figure 3).

The mean time (in seconds) taken for insertion was significantly more among ProSeal LMA (p-value <0.001) (figure 4). Full glottis view with fiberoptic bronchoscope was better in the I gel group in comparison to ProSeal LMA (p-value-0.048) Table 2. There was no significant difference in post-op complications like airway trauma (p-value= 0.185). The distribution of Gastric distension was compared between I gel and ProSeal LMA using the Chi-square test.

Gastric distension was found to be significantly more among I gel in comparison to ProSeal LMA (p-value-0.045) Chi-square value = 2.667.

Table 1: Patient Characteristics: data are expressed as mean (standard deviation) for age, BMI, and an absolute number of gender.

Variables	Group I (N=30)	Group P (N=30)	P Value
Age in years	36.43(10.121)	34.60 (10.603)*	0.547
BMI in kgm ⁻²	22.17 (3.11)	23.45(3.33)	0.440
Gender (M/F)	22/38	28/32	

(Independent samples 't' test*, BMI = Body mass index, F = Female, M = Male).

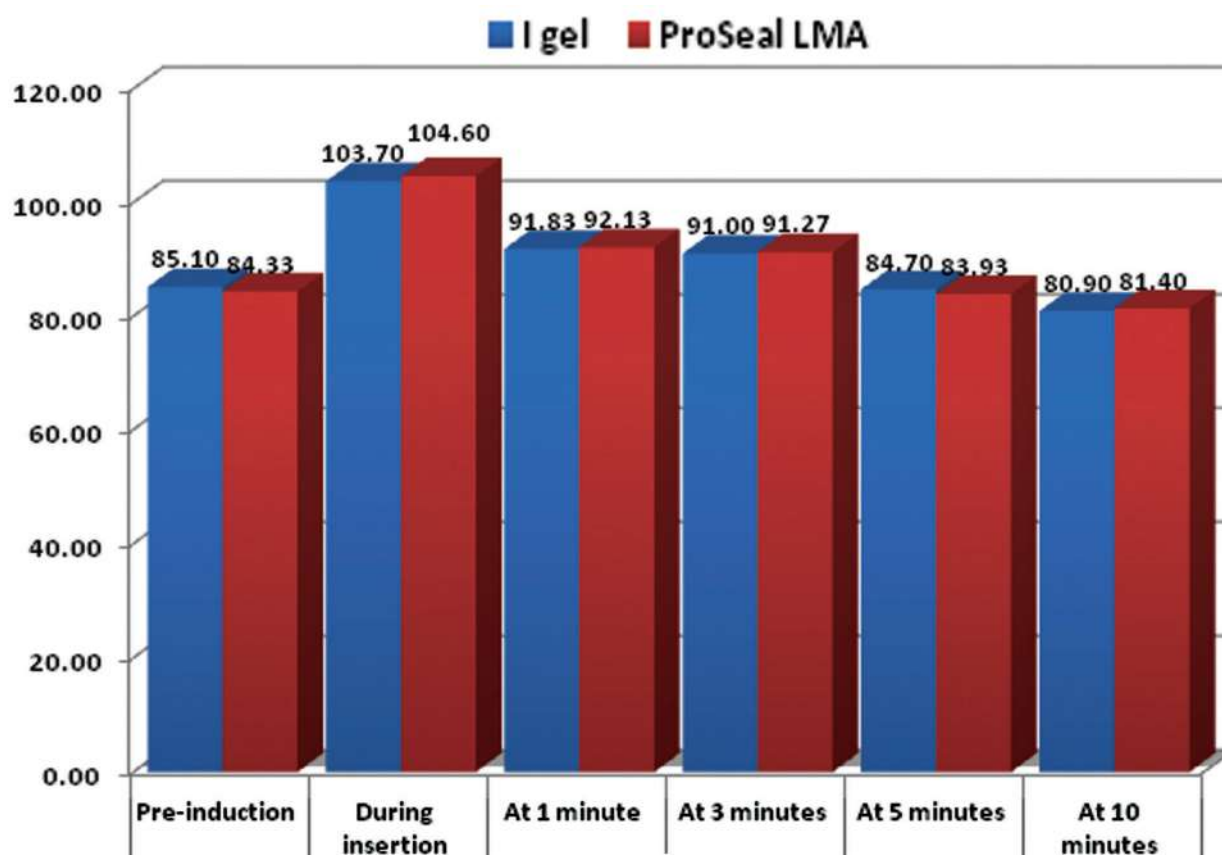


Fig. 1: Comparison of mean Heart rate between I gel and ProSeal LMA groups at Pre-induction, during insertion, at 1 minute, at 3 minutes, at 5 minutes, and 10 minutes after placement of device.

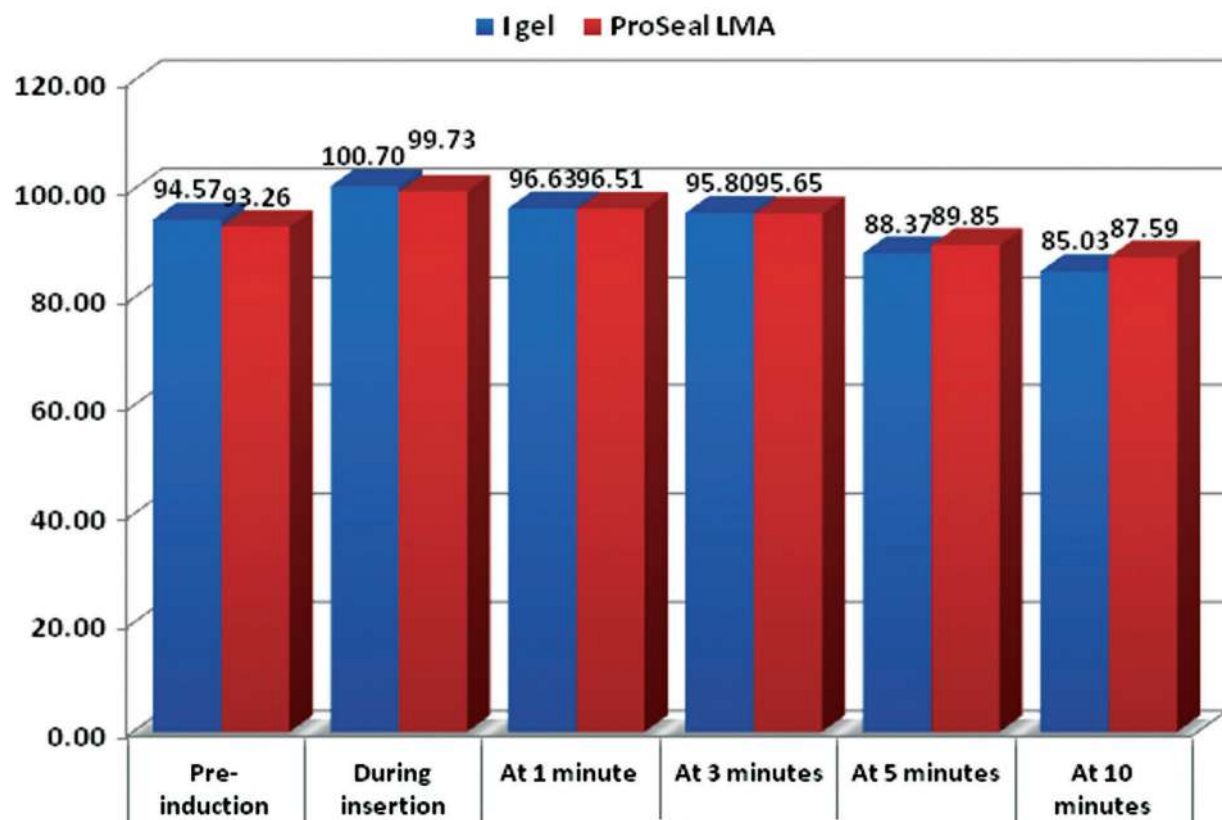


Fig. 2: Comparison of MAP between I gel and ProSeal LMA groups at Pre-induction, during insertion, at 1 minute, at 3 minutes, at 5 minutes, and 10 minutes after placement of the device.

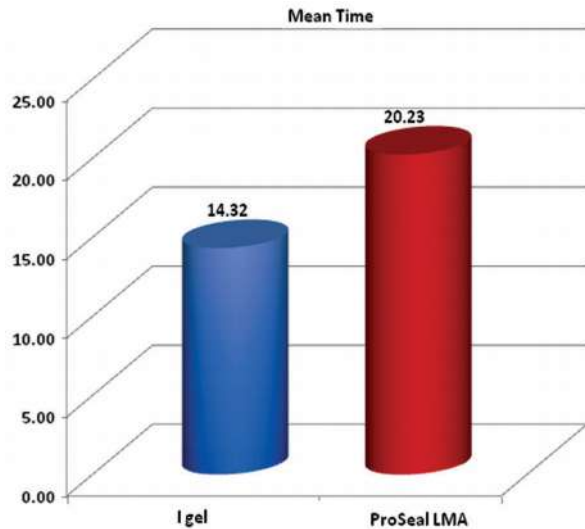


Fig. 3: Comparison of mean Time taken for insertion between I-gel and ProSeal LMA groups.

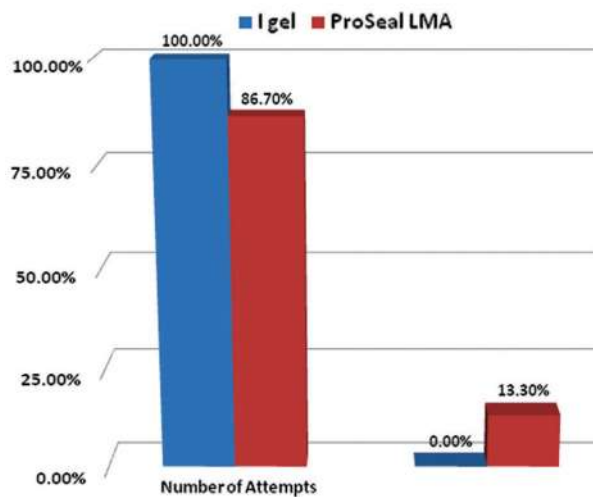


Fig. 4: Number of Attempts between I-gel and ProSeal LMA group.

Table 2: Fiberoptic view of glottis according to Brimacombe and Berry grading.

Fiberoptic view of glottis according to Brimacombe and Berry grading	I-gel	ProSeal LMA	Total
Full glottis view - I	56	50	106
	93.3%	83.3%	88.3%
Glottic aperture partially visible - II	3	7	10
	5.0%	11.7%	8.3%
Glottic aperture not visible - III	1	3	4
	1.7%	5.0%	3.4%

Chi-square value = 4.109, p-value = 0.048*

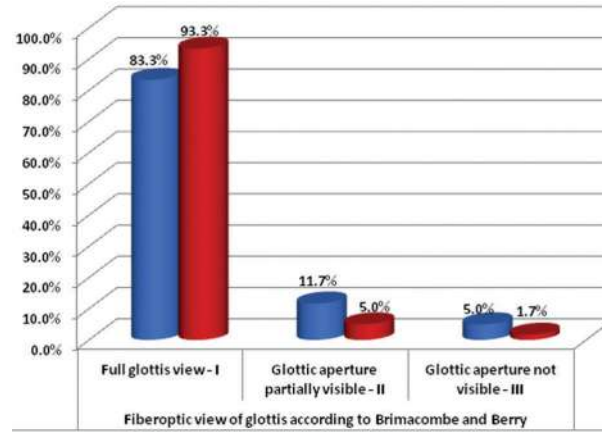


Fig. 5: Fiberoptic view of glottis.

Discussion

The present study was conducted to compare the placement of I-gel and ProSeal with help of fiberoptic bronchoscopy, and the clinical performance of I-gel and ProSeal in anaesthetised patients undergoing elective surgeries. Both groups were comparable in terms of age, BMI, and sex distribution ($p > 0.05$), in the present study which was quite similar to other studies performing similar comparisons. Hayashi et al.¹² in a study on 100 patients had similar results with the mean duration of surgery was almost comparable in both the groups with no significant statistical difference.

The mean time required for inserting the I-gel and ProSeal LMA in our study was 13.52 ± 1.06 seconds and 19.43 ± 1.56 seconds respectively with a significantly higher time of insertion for ProSeal LMA. This could be due to the time required for cuff inflation of PLMA after insertion. This was similar to the studies by Das et al.¹ the mean time required for inserting the I-gel and PLMA was 14.9 ± 2.6 seconds and 20.0 ± 3.1 seconds respectively, Chauhan et al.¹³ meantime for insertion of PLMA was 15.13 ± 2.91 seconds in comparison with I-gel which was 11.12 ± 1.81 seconds which had a statistically significant difference and Kini et al.¹⁰ the mean time required for successful insertion of I-gel (21.98 seconds) was significantly shorter than PLMA (30.60 seconds). In the study by Pratheeba et al.¹⁴ the duration of insertion time was significantly longer with LMA Classic™ compared to I-gel™. The median insertion time of 16 seconds has been reported with I-gel™. Helmy et al.¹⁵ observed significantly lower insertion times with I-gel™.

The distribution of the number of attempts was compared between I-gel and ProSeal LMA using the Chi-square test. Two attempts were found to

be significantly more among ProSeal LMA whereas one attempt to be significantly more among the ProSeal LMA group (Chi-square value = 4.286, p-value = 0.038). The comparable insertion rates were also reported by Goyal et al [16] with size 2, in which 38 of 40 insertions were successful on the first attempt with I-gel, and 36 of 40, with LMA ProSeal. The first attempt rate with 2.5 size and overall insertion success over 3 attempts was comparable between the 2 devices.

In our study, there were no differences in the mean Heart Rate (beat/min) between group LMA-ProSeal and group I-gel at baseline, before insertion, immediately after insertion and at 1, 2, 3, 5, 10 minutes. No significant difference in heart rate was found between the two groups as reported by Helmy.¹⁵

The present study showed that there was a significant increase in systolic as well as diastolic blood pressure on the insertion of airway devices. This significant increase in systolic and diastolic blood pressure at insertion persists till 3 minutes after insertion and again at removal, while a significant increase in diastolic blood pressure on insertion persists till 5 minutes following insertion. This was similar to the study by Das et al¹ there was a significant increase in systolic blood pressure at insertion that persists till 3 minutes after insertion and again at removal, while a significant increase in diastolic blood pressure on insertion persists till 5 minutes following insertion.

In the study by Helmy et al¹⁵ regarding the hemodynamic stability and effect of each of the supraglottic devices, no statistically significant difference was reported when comparing heart rate, systolic, and diastolic arterial blood pressure throughout the surgery. In our study, there were no episodes of desaturation ($SpO_2 < 95\%$) with both the groups during insertion, maintenance, and removal of the airway device. This was similar to the study by Pratheeba et al.¹⁴ In a study published by Helmy et al¹⁵ on comparative study between I-gelTM and LMA ClassicTM in eighty patients who were scheduled for surgery under general anesthesia maintaining spontaneous ventilation, there was no significant difference between both the groups SpO_2 .

In our study, it was observed that both the devices were easy to insert in two attempts, with a success rate of the first attempt to be 100% with I-gelTM and 83.3% with LMA ProSeal, which was statistically significant ($P = 0.003$). Singh et al. and

Siddiqui et al. also reported similar findings for I-gelTM.^{17,18}

Richez et al.¹⁹ evaluated the I-gel and found that the insertion success rate was 97%. Insertion was easy and was performed at the first attempt in every patient. I-gel was easily and rapidly inserted, providing a reliable airway in over 90% of cases.

In the study by Shin et al²⁰ there were no significant differences in the success rate among the I-gel, ProSeal laryngeal mask airway (PLMA), and classic laryngeal mask airway (CLMA) groups.

In the current study, there were 3 cases of postoperative sore throat or air trauma among ProSeal and 1 case among I-gel. In the study by Kini et al,¹⁰ patients did not have a postoperative sore throat which could be due to the high success rate in first insertion attempts in both groups. The causes of postoperative sore throat after general anesthesia using SADs are dependent on the depth of anesthesia, the method of insertion, number of insertion attempts, the mode of ventilation used, and the duration of anesthesia, and on the type of postoperative analgesia provided.¹⁹

In the study by Kini et al¹⁰ only two patients in Group ProSeal had blood-stained devices and none in the I-gel group. Chauhan et al¹³ reported a significantly higher rate of blood staining, sore throat, and dysphagia with the LMA ProSeal.

This can be attributed to the relative requirement of more manipulations with the LMA ProSeal. This may be due to the gel-filled cuff causing less trauma and or pressure damage to the oropharyngeal mucosa and the first successful attempt for most of the insertions. In our study, no such cases were reported.

A good laryngeal view may be helpful for fiberoptic intubation through these devices. We followed the grading system by Brimacombe and Berry and found a significant difference in glottic view ($p 0.048$) in the I gel group. Most of the patients had grade 1 view (56 vs. 50; Group I vs. Group P), but only three patients in group P had grade III view even though we could successfully ventilate these patients. This could be due to the folding of the PLMA cuff while insertion.

The results of the present clinical trial have shown ample advantages of I-gel including high success rate at the first attempt, easy insertion, shorter insertion time, and features designed to separate the gastrointestinal tract and respiratory tract which allows a gastric tube to be passed

easily into the stomach as it has a separate gastric channel.²¹

Limitations: Although the sample size of the present study was relatively small, it elucidates that I-gel appears to be efficacious in insertion characteristics. The limitation of the present study could be that only low-risk patients (ASA I and II) who had normal airways were studied which were mostly not obese. Also, one of the limitations was the inability to blind the anaesthesiologist inserting the device to group allocation.

Conclusion

Both I-gel and LMA ProSeal are useful airway devices for short-duration surgeries under general anesthesia. Although, the LMA ProSeal takes longer to insert, the quality of airway seal achieved and ease of insertion is comparable to that of I-gel, with minimal complications. I-gel had a better fiberoptic view and better haemodynamic stability (both Heart Rate and Blood Pressure). It requires no cuff inflation, so securing an airway is rapid in patients.

The present study showed that I-gel could be an effective alternative as a supraglottic airway device.

References

1. Das A, Majumdar S, Mukherjee A, Mitra T, Kundu R, Hajra BK, et al. I-gel™ in Ambulatory Surgery: A Comparison with LMA – ProSeal™ in Paralyzed Anaesthetized Patients. *J Clin Diagn Res.* 2014;8(3):80–4.
2. Timmermann A, Russo SG. Which airway should I use? *Curr Opin Anaesthesiol.* 2007;20:595–9.
3. Gal TJ. Airway management. In: Miller RD, Textbook of anaesthesia. 6th ed. Philadelphia: Elsevier; 2005:1617-52.
4. Hernandez MR, Klock PA Jr, Ovassapian A. Evolution of extraglottic airway: a review of its history, applications, and practical tips for success. *Anesth Analg.* 2012;114(2):349-68.
5. Goldmann K, Roettger C, Wulf H. The size 1(1/2) Proseal laryngeal mask airway in infants: A randomized, crossover investigation with the classic laryngeal mask airway. *Anesth Analg* 2006;102:405-10.
6. Bhatt SB, Kendall AP, Lin ES, Oh TE. Resistance and additional inspiratory work imposed by the laryngeal mask airway. A comparison with tracheal tubes. *Anesthesia.* 1992;47:343-7.
7. Keller C, Brimacombe J, Kleinsasser A, Brimacombe L: The Laryngeal Mask Airway ProSeal(TM) as a temporary ventilatory device in grossly and morbidly obese patients before laryngoscope-guided tracheal intubation. *Anesth Analg.* 2002;94:737-40.
8. Lu PP, Brimacombe J, Yang C, Shyr M. ProSeal versus the Classic laryngeal mask airway for positive pressure ventilation during laparoscopic cholecystectomy. *Br J Anaesth.* 2002;88:824-7
9. Chattopadhyay S, Goswami S. A comparative study of two disposable supraglottic devices in diagnostic laparoscopy in gynecology. *J South Asian Feder ObstGynae.* 2013;5(3):124-8.
10. Kini G, Devanna GM, Mukkapati KR, Chaudhuri S, Thomas D. Comparison of I-gel with proseal LMA in adult patients undergoing elective surgical procedures under general anesthesia without paralysis: A prospective randomized study. *J Anaesthesiol Clin Pharmacol.* 2014;30:183-7.
11. Brimacombe J, Keller C, Boehler M, Puhlinger F. Positive pressure ventilation with the Proseal versus classic laryngeal mask airway: A randomized, crossover study of healthy female patients. *Anesth Analg.* 2001;93:1351-3.
12. Hayashi K, Suzuki A, Kunisawa T, Takahata O, Yamasawa Y, Iwasaki H. A comparison of the single-use i-gel with the reusable laryngeal mask airway ProSeal in anesthetized adult patients in the Japanese population. *Masui.* 2013;62(2):134-9.
13. Chauhan G, Nayar P, Seth A, Gupta K, Panwar M, Agrawal N. Comparison of clinical performance of the I-gel with LMA proseal. *J Anaesthesiol Clin Pharmacol.* 2013;29(1):56-60.
14. Pratheeba N, Ramya GS, Ranjan RV, Remadevi R. Comparison of i-gel™ and laryngeal mask airway Classic™ in terms of ease of insertion and hemodynamic response: A randomized observational study. *Anesth Essays Res.* 2016;10(3):521-5.
15. Helmy AM, Atef HM, El-Taher EM, et al. Comparative study between I-gel, a new supraglottic airway device, and classical laryngeal mask airway in anesthetized spontaneously ventilated patients. *Saudi J Anesth.* 2010;4:131-6.
16. Goyal R, Shukla RN, Kumar G. Comparison of size 2 i-gel supraglottic airway with LMA-ProSeal™ and LMA-Classic™ in spontaneously breathing children undergoing elective surgery. *Paediatr Anaesth.* 2012;22(4):355-9.
17. Singh J, Yadav MK, Marahatta SB, Shrestha BL. Randomized crossover comparison of the laryngeal mask airway classic with i-gel laryngeal mask airway in the management of the difficult airway in post-burn neck contracture patients. *Indian J Anaesth.* 2012;56:348–52.
18. Siddiqui AS, Raees US, Siddiqui SZ, Haider S, Raza SA. Comparison of performance and safety of I-gel with laryngeal mask airway (classic) for general

- anaesthesia with controlled ventilation. *Anaesth Pain Intensive Care*. 2010;14:17-20.
19. Richez B, Saltel L, Banchereau F, Torrielli R, Cros AM. A new single-use supraglottic airway device with a noninflatable cuff and an esophageal vent: an observational study of the i-gel. *AnesthAnalg*. 2008;106:1137-9.
 20. Shin HW, Yoo HN, Bae GE, Chang JC, Park MK, You HS. Comparison of oropharyngeal leak pressure and clinical performance of LMA ProSeal™ and i-gel® in adults: Meta-analysis and systematic review. *J Int Med Res*. 2016;44:405-18.
 21. Peirovifar A, Eydi M, Mirinejhad MM, Mahmoodpoor A, Mohammadi A, Golzari SE. Comparison of postoperative complication between laryngeal mask airway and endotracheal tube during low-flow anesthesia with controlled ventilation. *Pak J Med Sci*. 2013;29:601-5.

