

A Randomized Comparative Study of Ropivacaine 0.5% in Brachialplexus Block with Adjuvant as Dexamethasone vs Fentanyl

E S Sravani Gurajapu¹, C N Chandra Sekhar²

Author's Affiliation:

¹Senior Resident, ²Consultant, Head of the Department, Department of Anesthesiology, Intensive Care and Pain Medicine, Yashoda Hospital, Hyderabad 500073, Telangana, India.

Abstract

Background and Aim: Supraclavicular brachial plexus block is a well-known technique of giving analgesia and anaesthesia for upper limb, our study is aimed at comparing the efficacy of dexamethasone 8mg versus fentanyl 50µg in blockade characteristics and postoperative analgesia when added to 0.5% ropivacaine 30 ml in supraclavicular brachial plexus block. During the study we want to compare the sensory and motor block achieved.

Methods: This was a prospective randomized double blind study of 60 cases. The selection of patients was carried out randomly, depending on the lists of operations submitted by the surgical team. A written informed consent was obtained from all patients. Groups were Randomized into Ropivacaine+Fentanyl group (RF) and Ropivacaine + Dexamethasone (RD) groups.

Results: Duration of motor blockade was longer in RD group 793.67 ± 75.143 compared to RF group 455.5 ± 27.429 . P value was 0.001 which is statistically significant. Duration of sensory blockade was longer in RD group 1181.67 ± 75.59 compared to RF group 508.83. p value was 0.0001 which is statistically significant.

Conclusion: Role of Ultrasonography in regional block need not be emphasized, Addition of dexamethasone prolongs the duration of motor block, enhances the duration of analgesia significantly when compared with fentanyl in supraclavicular brachial plexus block and dexamethasone group has 0 VAS scores for longer period compared to fentanyl group.

Keywords: Supra clavicular Brachial Plexus; Ultrasound; Ropivacaine; Fentanyl; Dexamethasone.

Introduction

Brachial plexus block is commonest procedure done in day to day practice in anaesthesia. It is performed to get anaesthesia or analgesia for upper limb for various indications. Brachial plexus block can be performed by Interscalene, supraclavicular, Infraclavicular and Axillary approaches. Though Supraclavicular block is the commonest and popular

technique it is still associated with complications like Pneumothorax. Ultrasound guided technique make this block very safe and 100% successful. Achieving block is usually done by using local anaesthetic drugs. Depending on the type of local anaesthetic used the duration of the block varies. Adding few additives to the local anaesthetic solution gives an addition advantage in onset, duration and density of the block. Considering these factors this study is

How to cite this article: E S Sravani Gurajapu, C N Chandra Sekhar. /A Randomized Comparative Study of Ropivacaine 0.5% In Brachialplexus Block With Adjuvant As Dexamethasone Vs Fentanyl. / Indian J Anesth Analg, 2021; 8(3): 339-348.

Corresponding Author: C N Chandra Sekhar, Consultant, Head of the Department, Department of Anesthesiology, Intensive Care and Pain Medicine, Yashoda Hospital, Hyderabad 500073, Telangana, India.

Email: cncschandu@gmail.com

formulated to compare the effect of Fentanyl and Dexamethasone as additives to our local anaesthetic solution Ropivacaine.

Material and Methods

After obtaining approval from the ethical committee clearance from our institution this prospective randomized double-blind study of 60 cases was conducted. 60 patients aged between 18yrs and 60 yrs of physical status ASA grade I and ASA grade II undergoing elective upper limb surgeries were randomly divided into two groups. Each group consisting of 30 patients to receive supraclavicular brachial plexus block.

GROUP RD (N=30) - 30 ml of 0.5% ropivacaine plus 2 ml of 8mg dexamethasone

GROUP RF (N=30) - 30 ml of 0.5% ropivacaine plus 50 µg fentanyl made to 2 ml.

Informed written consent is taken from all the participants. Patients who refused regional block, with coagulation problems, local site infection were excluded from the study. An informed written consent was obtained from all the patients enrolled in the study.

Method

Pre-anaesthetic evaluation

During pre-operative visit patients detailed history, general physical examination and systemic examination were carried out. Basic demographic data like age, sex, height, weight was recorded.

During pre-anaesthetic check-up the visual analogue scale was explained to all patients using 10 cm scale (Fig.1). Informed consent was obtained from all the 60 patients after detailed explanation of the procedure to be performed.

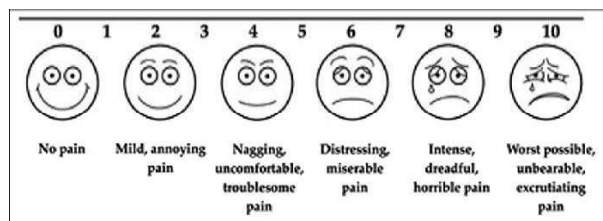


Fig. 1: VAS score by visual analogue scale.

Procedure

The basal parameters pulse rate, respiratory rate, blood pressure and spo2 were recorded before starting the case. Peripheral venous cannulation was done with 20G IV cannula in opposite arm

and infusion of ringerlactate was started. Each patient would be given 0.03 mg/kg of midazolam intravenously (IV) as a premedication 15 mins before beginning the block technique. Under strict aseptic precautions all the patients received brachial plexus block through the supraclavicular approach.

All the necessary equipment and drugs needed for administration of general anaesthesia and resuscitation will be kept ready in order to manage failure of block and any complications.

One of the anaesthesiologists not involved in the care or monitoring of the patient, prepared the local anaesthetic study solutions.

The patients and the observing anaesthesiologist as well as the physicians and nurses of the acute pain service were blinded to the study drug used.

Position of the Patient

Patient was made to lie supine with head turned opposite to side of intended block and arm adducted & pulled down gently. A small pillow or folded sheet was placed below the shoulder to make the field more prominent.

Technique

The supraclavicular space then was prepared using aseptic technique with povidone iodine (Betadine) solution, and the subclavian artery was identified by palpation. The linear high frequency 10-15 MHz transducer of ultrasound machine was initially placed in midline to identify trachea and later it was slid laterally till ultrasound image displayed posterior border of sternocleidomastoid. The roots of brachial plexus were identified as round hypoechoic structures emerging between origins of scalenus anterior and scalenus Medius. These structures were traced caudally till supraclavicular space and subclavian artery was identified as a pulsatile structure. The brachial plexus at this level appeared as a bunch of hypoechoic round structures lying postero-laterally in ultrasound image. The skin was anaesthetized with 1 ml of 1% lidocaine solution. The brachial plexus as approached using a nerve locator needle by in plane approach, the locator end point was distal motor response with output lower than 0.6mA. Negative aspiration of blood was confirmed and the anaesthetic was administered in 5-mL increments following aspiration.

Assessment

Ending of injection time was recorded as 0 hour.

In the two groups the following parameters are noted.

1. Onset of sensory blockade
2. Onset of motor blockade
3. Duration of motor blockade
4. Duration of analgesia
5. VAS scores
6. Side effects

Assessment of sensory block and motor block was done at each minute after completion of drug injection in corresponding dermatomes till complete sensory and motor blockade. Motor block was assessed at 2nd hour and every 2nd hourly there after post-operatively till patient regained normal power.

To evaluate duration of analgesia and motor block duration. Patients were asked to inform the time when incisional discomfort as a sensation of pain began and also the time when full power returned to the shoulder.

Duration of analgesia was assessed using visual analogue scale (VAS). During preoperative visit patients were explained about VAS

- 0 - no pain
- 2 - mild pain
- 5 - moderate pain
- 8 - severe pain
- 10 - Unbearable pain

The maximum pain scores i.e., VAS scores at different time intervals 0,5,10,15,20,25,30,45 minutes, 1st hr, 2nd hr and thereafter every second hourly till 24 hrs in postoperative period for each patient were recorded.

Assessment of motor blockade was done by Bromage three-point score

0 - normal motor function with full flexion and extension of elbow, wrist and fingers.

1 - decrease motor strength with ability to move fingers and/or wrist only

2 - complete motor blockade with inability to move fingers.

Any hypersensitivity reaction for the drugs, evidence of pneumothorax, and other adverse events were also monitored.

In the post-operative period, when the patient complained of pain, VAS>3 at the operative site, Injection Diclofenac 75 mg slow iv infusion was given. Patients were followed up for 24 hrs for any side effects.

Statistical Analysis

Data were expressed as mean values ± standard deviation/ standard error, percentages (%), and numbers (n). The statistical analysis was performed by a statistician using Windostat Version 9.2 in Hyderabad, Telangana. Two statistical tests were primarily used to analyze the data.

- t-tests were used to analyze differences between two groups
- Differences in VAS score over a period of time were analyzed using ANOVA (analysis of variance)

Consideration of P values

P value: <0.05 = significant >0.05 = Not significant.

Observation and Results

Table 1: Demographic profile of patients.

		Descriptive						P value
		N	Mean	Std. Deviation	Std. Error	Min.	Max.	
Age	RD	30	34.53	9.705	1.772	18	56	0.174
	RF	30	38.33	11.615	2.121	24	59	
	Total	60	36.43	10.783	1.392	18	59	
Wt. (kg)	RD	30	64.37	9.125	1.666	41	80	0.560
	RF	30	62.97	9.349	1.707	49	80	
	Total	60	63.67	9.187	1.186	41	80	
Ht (cm)	RD	30	159.67	3.854	.704	154	166	0.325
	RF	30	158.50	5.158	.942	150	170	
	Total	60	159.08	4.552	.588	150	170	

ANOVA is applied. P value <0.05 is significant

Our study was conducted on 60 patients who were randomly allocated into group-RD and group-RF consisting of 30 patients each. Minimum age recorded in our study was 18 years and maximum age was 59 years. The mean age of patient in group-RD was 34.53 years while the mean age of patient in group-RF was 38.33 years (Table.1). The P value was 0.174 which signifies that the two groups were comparable with regards to age.

Mean weight of patients in group-RD was 64.37Kgs and mean weight of patients in group-RF was 62.97Kgs (Table.1). The P value was 0.560 which is not significant showing that the groups are comparable with regards to Weight.

Mean height of patients in group-RD was 159.67cms while mean height of patients in group-RF was 158.50 (Table. 1).The P value was 0.325

which was again insignificant showing that the two groups are comparable with regards to height.

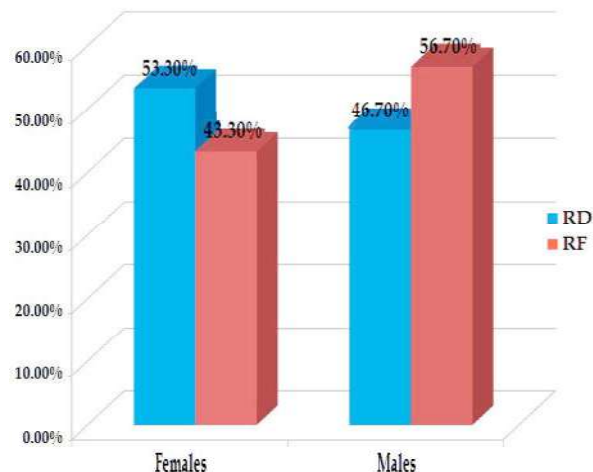
Thus, the patients in our study group were comparable with respect to Age, Weight and Height eliminating bias (if any) which can occur due to these factors.

Table 2: Gender Comparison in two Groups.

Group *Sex Crosstabulation				
Group		Sex		Total
		F	M	
RD	Count	16	14	30
	% within group	53.3%	46.7%	100.0%
RF	Count	13	17	30
	% within group	43.3%	56.7%	100.0%
Total	Count	29	31	60
	% within group	48.3%	51.7%	100.0%

Chisquare Value: 0.601, Df: 1, P Value: 0.606, Statistically Not Significant.

Graph.1: Gender Comparison in two groups.



In group-RD 53.3% were females and 46.7% were males. In group-RF, 43.3% were females and 56.7% were males (Table. 2)(Graph. 1). Difference between them was comparable in both groups thus eliminating bias if any.

In group-RD, 56.67% patients were ASA I and the remaining 43.33% cases were ASA II. In group-RF 56.67% cases were ASA I and 43.33% cases were ASA II. There was statistically no difference between two groups (Table. 3) (Graph. 2). Thus, the patients in our study groups were comparable with respect to ASA eliminating bias if any.

Table 3: Comparison of ASA in two Groups.

Group *ASA Crosstabulation				
Group		ASA		Total
		I	II	
RD	Count	17	13	30
	% within group	56.7%	43.3%	100.0%
RF	Count	17	13	30
	% within group	56.7%	43.3%	100.0%
Total	Count	34	26	60
	% within group	56.7%	43.3%	100.0%

Chisquare Value: 0.001, Df: 1, P Value: 1, Statistically Not Significant

Graph. 2: Comparison of ASA in two Groups.

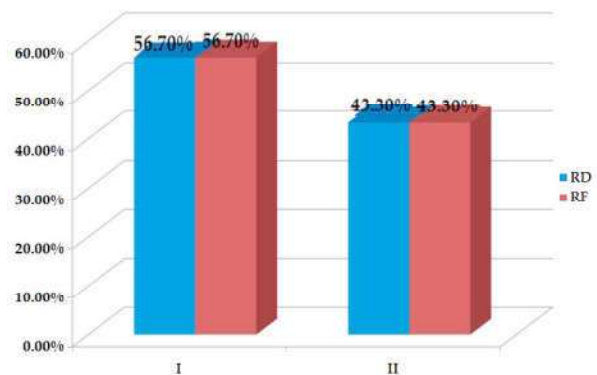
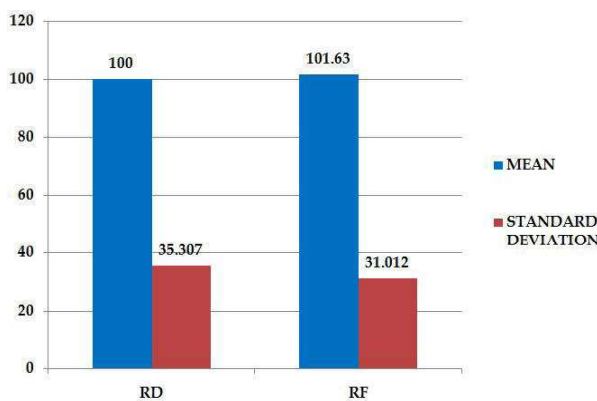


Table 4: Comparison of duration of surgery.

Group Statistics					
Group	N	Mean	Std. Deviation	Std. Error Mean	P Value
DOS	RD	30	100.00	35.307	0.850
	RF	30	101.63	31.012	

T- Test is applied. P value is significant if <0.05

Graph. 3: Comparison of duration of surgery.



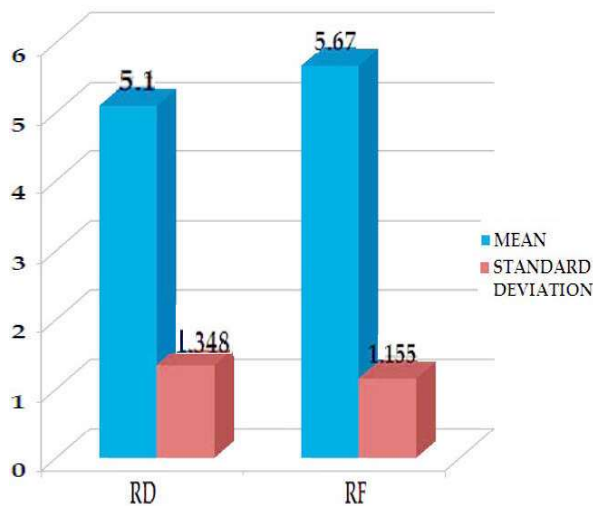
The total duration of surgery was comparable in both groups with mean duration in group-RD 100.00 ± 35.307 and group-RF 101.63 ± 31.012 mins. The P value was 0.850 which was insignificant (Table.4)(Graph.3).

Table 5: Comparison of onset of sensory block.

Group Statistics						
	Group	N	Mean	Std. Deviation	Std. Error Mean	P Value
SOT	RD	30	5.10	1.348	.246	0.086
	RF	30	5.67	1.155	.211	

T- Test is applied. P value is significant if <0.05 .

Graph. 4: Comparison of onset of sensory block.



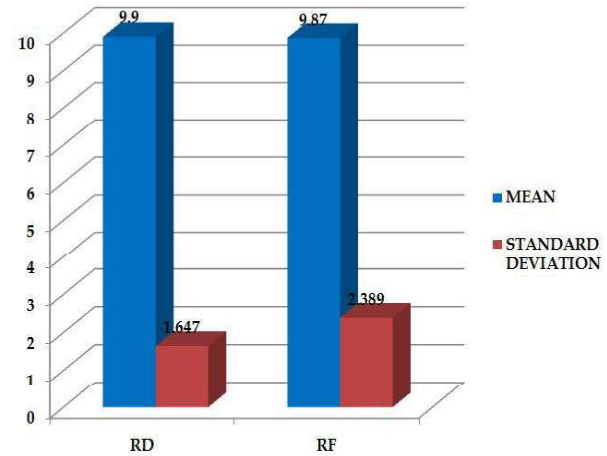
Onset time is the time from the completion of injection of study drug to first loss of pinprick sensation in any of the dermatomes C5-T1. In group-RD, it was 5.10 ± 1.348 min and 5.67 ± 1.155 min in group-RF (Table.5)(Graph.4). This shows that onset of sensory block was comparable in both groups with no statistical significance.

Table 6: Comparison of onset of motor block.

Group Statistics						
	Group	N	Mean	Std. Deviation	Std. Error Mean	P Value
MOT	RD	30	9.90	1.647	.301	0.950
	RF	30	9.87	2.389	.436	

T- Test is applied. P value is significant if <0.05 .

Graph 5: Comparison of onset of motor block.



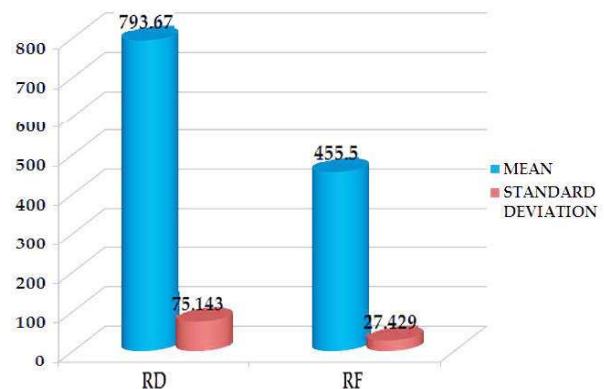
The total time required to achieve complete paralysis of the upper limb was considered as onset of motor block. In group-RD, it was 9.9 ± 1.647 min and 9.87 ± 2.389 min in group-RF. P value is 0.950 which is not significant (Table.6)(Graph.5). This shows that onset of motor block was comparable in both groups with no statistical significance.

Table 7: Comparison of Duration of motor block.

Group Statistics						
	Group	N	Mean	Std. Deviation	Std. Error Mean	P Value
DOMB	RD	30	793.67	75.143	13.719	0.001*
	RF	30	455.50	27.429	5.008	

T- Test is applied. P value is significant if <0.05 .

Graph 6: Comparison of Duration of motor block.

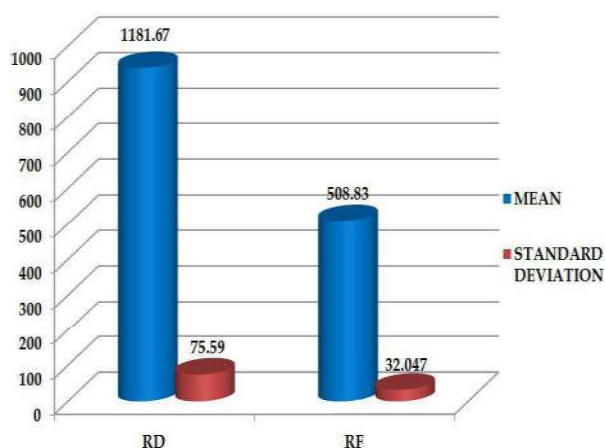


Duration of motor blockade was longer in RD group 793.67 ± 75.143 compared to RF group 455.5 ± 27.429 . P value was 0.001 which is statistically significant (Table.7)(Graph.6).

Table 8: Comparison of Duration of Sensory block.

Group Statistics						
Group	N	Mean	Std. Deviation	Std. Error Mean	P Value	
DOSB	RD	30	1181.67	75.59	13.8	0.0001*
	RF	30	508.83	32.047	5.851	

T- Test is applied. P value is significant if <0.05.

Graph 7: Comparison of Duration of Sensory block.

Duration of sensory blockade was longer in RD group 1181.67 ± 75.59 compared to RF group 508.83 . p value was 0.0001 which is statistically significant (Table.8)(Graph.7).

Discussion

Use of ultrasound in our study

Ultrasound guidance for supraclavicular brachial plexus block is clinically useful for accurate nerve localization and also minimizes the number of needle attempts. Ultrasound can determine the size, depth, and exact location of the brachial plexus and its neighbouring structures and avoids vascular and pleural punctures.

In our study we used in plane approach of needle insertion with one hand holding the probe, the other advancing the block needle from the outer end of the probe in a lateral to medial direction for two main reasons. First, when positioned in the supraclavicular fossa, the probe leaves limited space on the medial side for needle manoeuvring. Second, the brachial plexus is situated lateral to the subclavian artery; thus, the lateral approach is most logical and direct.

The needle is advanced intentionally in the same plane as the ultrasound beam, i.e., along the

along axis of the probe, where the linear array of ultrasound crystals is situated. With proper needle probe alignment, movement of the needle shaft and tip (a hyper echoic line seen) can be tracked continuously during the block procedure.

When the needle does not trespass the first rib or pleura on ultrasound, the risk of pneumothorax is virtually eliminated. However, without proper alignment, the needle tip cannot be fully visualized, and penetration can be deeper than anticipated, as with the case of unrecognized pleural puncture in this study. Ultrasound imaging shows nerves as mobile structures that move away from the needle or local anaesthetic injection to the periphery, suggesting circumferential spread.

In our study, because of correct needle position and the distention of the plexus sheath which was visualised by ultrasound in all patients, relatively small volumes of local anaesthetics, less than the potentially toxic dose, were necessary to produce satisfying motor and sensory block in nearly all patients. Also the onset of sensory and motor blocks were faster in our study as compared to the studies in which this block was performed by conventional or nerve stimulator technique.

Stephan R Williams et al (2003) assessed the quality, safety, and execution time of supraclavicular block of the brachial plexus using ultrasonic guidance and nerve stimulation compared with a supraclavicular technique that used anatomical landmarks and nerve-stimulation. They used equal volumes (0.5ml/kg) of 0.5% bupivacaine and 2% lidocaine, with 1:200000 epinephrine. The duration of post block analgesia was (Group US: mean 846 ± 531 min, median 662 min; Group NS: mean 652 ± 473 min, median 511 min; P not significant). In Group US, 85% of blocks achieved surgical anaesthesia without supplementation, compared with 78% in Group NS. General anaesthesia was required in 0% and 8% of US and NS patients, respectively. They concluded that ultrasound-guided nerve stimulator-confirmed supraclavicular block is more rapidly performed and provides a more complete block than supraclavicular block using anatomic landmarks.

Vincent. W. S. Chan et al² (2003), studied Ultrasound-Guided Supraclavicular Brachial Plexus Block in 40 outpatients. The block technique aligned the needle path with the ultrasound beam. The block was successful after one attempt in 95% of the cases. They summarised that ultrasound imaging confers confidence and accuracy of needle placement for nerve localization and examines the pattern of local anaesthetic spread.

Drugs selected for the study

The three commonly used local anaesthetics are lignocaine, bupivacaine and ropivacaine. Lignocaine is short acting with no added benefit on postoperative analgesia when given in brachial plexus block. Bupivacaine is long acting with more cardiotoxic effects. Ropivacaine is similar to bupivacaine in terms of blockade characteristics but, with lesser cardio and neurotoxicity than bupivacaine. Hence ropivacaine was selected.

Casati A et al³(2000) conducted a prospective randomized double blind study to compare intra- and postoperative clinical properties of interscalene brachial plexus block performed with either 0.5% ropivacaine or 0.5% bupivacaine. This study confirmed that 0.5% ropivacaine has clinical properties similar to those of 0.5% bupivacaine, providing similar long duration of postoperative pain relief. Compared with bupivacaine, ropivacaine has the further advantage of a lower potential for central nervous system and cardiovascular toxicity.

Rosemary Hickey et al⁴ (1991) conducted a randomized double blind study to compare the effectiveness of 0.5% Ropivacaine and 0.5% Bupivacaine for brachial plexus block. They concluded that both were similar in terms of onset of sensory and motor block, duration of sensory and motor block, incidence of analgesia, anaesthesia, paresis and paralysis and need for supplementation.

Fentanyl is commonly used potent opioid in our institution. We use fentanyl as adjuvant to spinal anaesthesia and brachial plexus block. My interest is brachial plexus blockade. This enhanced antinociception may have been mediated via activation of peripheral opioid receptors. There are also reports that Fentanyl may have local anaesthetic like action.

Tejwant Rajkhowa, et al⁵ (2016) conducted a randomized study in 66 patients to compare the analgesic efficacy of Fentanyl used as an adjuvant to ropivacaine for supraclavicular brachial plexus block

Soman c, et al⁶ (2015) compared the effects of fentanyl and dexmedetomidine in supraclavicular brachial plexus block achieved with ropivacaine in 90 patients.

Siamak Yaghoobi, et al⁷ (2013) conducted a randomized study in 78 patients to compare the analgesic efficacy of dexamethasone and fentanyl added to lidocaine using axillary block.

karakaya d, et al⁸ (2001) studied effect of fentanyl

added to bupivacaine in axillary brachial plexus block in 60 patients.

Dexamethasone is cheap and commonly available steroid with studies showing marked prolongation of postoperative analgesia. Prolongation of duration of sensory and motor blockade after perineural administration of dexamethasone may be secondary to its local action on nociceptive C fibers mediated via membrane associated glucocorticoid receptors.

Amit agarwal, et al⁹ (2015) studied effect of dexamethasone in interscalene brachial plexus block for shoulder arthroscopic surgery in 100 patients

Gildasio S. De Oliveira Jr. et al¹⁰ (2014) Nine randomized trials with 760 subjects were included. They concluded that perineural dexamethasone seems to improve analgesia duration when used as an adjunct to brachial plexus blocks.

Dr. Feroz Ahmad Dar, et al¹¹ (2013) studied effect of addition of Dexamethasone to Ropivacaine in Supraclavicular brachial plexus block in 80 patients.

Concentration and doses of the drugs selected

A faster onset of action could be achieved by increasing concentration of ropivacaine to 0.75%, but was kept to 0.5% in present study since increasing concentration failed to improve blockade characteristics and that the risk of increasing total mg dose of local anaesthetic may not be warranted.

Stephen M Klein et al¹² (1998) conducted a trial in 75 patients to compare 0.5% Bupivacaine and 0.5% and 0.75% Ropivacaine for interscalene brachial plexus block. They concluded that there was no clinically important difference in times of onset and recovery of interscalene block for all 3 drug concentrations when injected in equal volumes.

Various authors have used different volumes of Ropivacaine for brachial plexus block. Stephen M Klein et al¹², Soman c et al⁶, tejwant et al⁵ and kumud et al¹³ used 30 ml of local anaesthetic solution for brachial plexus block.

Hence 0.5 % Ropivacaine 30 ml volume was selected for our study and only 8 milligrams of dexamethasone used as this much dose does not cause complications.

Various authors have used 50 mcg of fentanyl as adjuvant. Tejwant et al⁵, Ravi madhusudhan et al¹⁴, Soman C et al⁶.

Several authors have used 8mg dexamethasone as adjuvant. K. C. Cummings et al¹⁵, Dr. Feroz et al¹⁰, Siamik et al⁶, Kumud s et al¹³, Santosh kumar et al¹⁶.

Onset of sensory block

Sensory onset time is the time from the completion of injection of study drug to first loss of pinprick sensation in any of the dermatomes C5-T1. In group-RD, it was 5.10 ± 1.348 min and 5.67 ± 1.155 min in group-RF. This shows that onset of sensory block was comparable in both groups with no statistical significance.

The sensory onset time of RF group in our study was 5.67 ± 1.155 min well matches with study conducted by Ravi Madhusudhana¹⁴ et al⁵ ± 0 min. They compared efficacy of supraclavicular block of brachial plexus with ropivacaine, ropivacaine and tramadol, ropivacaine and fentanyl in terms of onset, quality and duration of sensory and motor block for patients undergoing surgery for the upper limb.

In study conducted by Tejwant Rajkhowa et al⁵ where they used fentanyl as adjuvant to ropivacaine in supraclavicular block, sensory onset time in RF group was 8.15 ± 1.22 min not matching with our study. onset time was less in our study. Reason could be they used nerve stimulator in their study and in our present study we used ultrasound guided nerve stimulator technique, where local anaesthetic is deposited closer to the nerve resulting in faster onset.

Leslie c et al¹⁷ found that using Ultrasound in guiding the interscalene approach to the brachial plexus significantly shortened the duration of intervals in conduction of the block and onset of anaesthesia when compared with Nerve stimulator.

The sensory onset time of RD group in our study was 5.1 ± 1.34 min. correlating to the study Conducted by Dr R. G. Pathak, et al¹⁸ who studied the effect of Supraclavicular brachial plexus block with and without Dexamethasone in 50 patients. The mean onset of sensory block was 5.92 ± 2.827 min in dexamethasone group.

Compared to other studies conducted by Amit Agarwal, et al⁹, Kumud S, et al¹³ sensory onset time in our study was less, which was probably due to ultrasound guided nerve stimulator technique in our study, where local anaesthetic is deposited closer to the nerve resulting in faster onset.

In our present study by adding adjuvant, fentanyl or dexamethasone to ropivacaine there was no significant difference in sensory onset times. p value was >0.05 .

Onset of motor block

In our present study motor onset time of RF

group was 9.87 ± 2.3 min. In study conducted by Ravi madhusudhana¹⁴ et al motor onset time was 11.5 ± 2.41 min. In study conducted by Tejwant Rajkhowa et al⁵ motor onset time was 13.2 ± 1.64 min. onset time was less in our study. Reason could be they used nerve stimulator in their study and in our present study we used ultrasound guided nerve stimulator technique, where local anaesthetic is deposited closer to the nerve resulting in faster onset.

Leslie c et al¹⁷ found that using Ultrasound in guiding the interscalene approach to the brachial plexus significantly shortened the duration of intervals in conduction of the block and onset of anaesthesia when compared with Nerve stimulator

In our study motor onset time of RD group was 9.9 ± 1.64 min matching with study by Kumud S, et al¹³ where they studied the efficacy of dexamethasone added as an adjuvant to ropivacaine (0.5%) for brachial plexus block. Motor onset time in kumud study was 13.07 min.

In our present study by adding adjuvant, fentanyl or dexamethasone to ropivacaine there was no significant difference in sensory onset times. p value was >0.05 .

Duration of motor block

Motor block duration of RF group in our study was 455.5 ± 27.42 min (7-8 hrs). This observation well matches with study conducted by Soman c, et al⁶ where they compared the effects of fentanyl and dexmedetomidine in supraclavicular brachial plexus block achieved with ropivacaine. A prospective clinical trial where 90 patients were randomly allocated to either receive 30 ml ropivacaine 0.5% (Group R), 30 ml ropivacaine 0.5% with fentanyl 50 mcg (Group RF) or 30 ml ropivacaine 0.5% with dexmedetomidine 50 mcg (Group RD) in Supraclavicular brachial plexus. The motor block duration in RF group was 458.15 ± 20.62 min.

In study conducted by Tejwant Rajkhowa et al⁵ duration of motor blockade of RF group was 6.56 ± 0.43 hrs, comparable with our present study.

Motor block duration of RD group in our study was 793.67 ± 75.14 min (12-14.5 hrs). This observation was comparable with that of Kumud S, et al¹³ where they studied the efficacy of dexamethasone added as an adjuvant to ropivacaine (0.5%) for brachial plexus block. Total duration of motor blockade was 13.07 hrs.

There was a significant increase in duration of

motor blockade in dexamethasone group compared to fentanyl group and the difference was shown statistically significant. P value was 0.001.

Duration of analgesia (duration of sensory block)

Duration of analgesia of RFgroup in our study was 508.83 ± 32.047 min (8-9 hrs). This observation well matches with study conducted by Soman c, et al⁶ where duration of analgesia of RF group was 569 ± 36.04 min.

In study conducted by Tejwant Rajkhowa et al⁵ duration of analgesia of RFgroup was 7.75 ± 0.47 min which was comparable with our present study.

Duration of analgesia of RDgroup in our study was 1181.67 ± 75.59 min (18.5-21hrs)

The present study correlates well with study conducted by Amit Agarwal, et al⁹. They studied in 100 patients with 2 groups received 30 ml of 0.5% ropivacaine plus 2 ml normal saline and 30 ml of ropivacaine 0.5% plus 2 ml dexamethasone 8 mg. Duration of analgesia in dexamethasone group was 1103.72 ± 296.027 min. Dexamethasone (8 mg) significantly prolonged the duration of analgesia.

In another study by K. C. Cummings III, et al¹⁵ 218 patients were divided into 4 groups. (i)0.5% ropivacaine only (ii)0.5% bupivacaine only (iii)0.5% ropivacaine mixed with dexamethasone 8 mg (iv)0.5% bupivacaine mixed with dexamethasone 8mg. They concluded that Dexamethasone prolongs analgesia from interscalene blocks using ropivacaine or bupivacaine, with the effect being stronger with ropivacaine. Median duration of analgesia with ropivacaine and dexamethasone was 22hrs well comparable with our study.

In study conducted by Santhosh Kumar et al¹⁶ Comparative evaluation of ropivacaine and ropivacaine with dexamethasone in supraclavicular brachial plexus block was done. Duration of sensory blockade was 1179.4 ± 108.6 min. This correlate well with our study.

There was a significant increase in duration of sensory blockade/duration of analgesia in dexamethasone group compared to fentanyl group and the difference was shown statistically significant. P value was 0.0001.

To date there is one study conducted by Siamak Yaghoobi, et al⁷ comparing fentanyl with dexamethasone added to lidocaine in axillary block in patients undergoing operation of forearm fracture. They concluded that addition of dexamethasone to lidocaine significantly prolonged the duration

of analgesia compared with fentanyl & lidocaine mixture or lidocaine alone.

Adverse effects

There was no incidence of haematoma, pneumothorax, accidental intravascular injection, post block nausea and vomiting, convulsions, neuralgia, neuropathies, increased rate of infections in both the groups. No patients in either group required any interventions.

The results in our study showed that dexamethasone 8 mg can be used safely as an adjuvant to Ropivacaine to prolong the duration of sensory blockade analgesia.

Conclusion

Use of ultrasound for performing brachial plexus block allows accurate nerve localization, reduces complications, shortens onset time of sensory and motor blockade.

Addition of dexamethasone prolongs the duration of motor block, enhances the duration of analgesia significantly when compared with fentanyl in supraclavicular brachial plexus block.

Also, dexamethasone group has 0 vas scores for longer period compared to fentanyl group.

References

1. Stephan R. Williams, Philippe Chouinard, et al, Ultrasound Guidance Speeds Execution and Improves the Quality of Supraclavicular Block. *Anesth. Analg.* November 1, 2003; 97:1518-1523.
2. Vincent W. S. Chan, Anahi Perlas, Regan Rawson. Ultrasound-Guided Supraclavicular Brachial Plexus Block. *Anesth Analg* 2003; 97:1514 -7
3. Casati A, Fanelli G, Albertin A, Deni F, Anelati D, Antonino FA, et al. Interscalene brachial plexus anaesthesia with either Ropivacaine 0.5% or Bupivacaine 0.5%. *Minerva Anaesthesiol* 2000;66:39-44.
4. Hickey R, Hoffman JRN, Ramamurthy MSNS. A comparison of Ropivacaine 0.5% and Bupivacaine 0.5% for Brachial plexus block. *Anaesthesiology* 1991; 74:639-42.
5. Rajkhowa T et al. *Int J Clin Trials*. 2016 May;3(2):64-67
6. Soma C. Cham, Medha A. Sangawar, Umesh L. Ramtani, Bhupendra S. Chavan, Chandrashekharam Cham. Comparison of the Effects of Fentanyl & Dexmedetomidine in Supraclavicular Brachial Plexus Block Achieved with Ropivacaine. *Journal of Evolution of Medical and Dental Sciences* 2015; Vol.4, Issue 54, July 06; Page: 9427-9436.

7. Yaghoobi S, Seddighi M, Yazdi Z, Ghafouri R, Khezri MB. Comparison of Postoperative Analgesic Effect of Dexamethasone and Fentanyl Added to Lidocaine through Axillary Block in Forearm Fracture. *Pain Research and Treatment*. 2013;2013:761583.
8. Karakaya D, B'uy'ukg'oz F, Baris S, G'uldo'gus F, T'ur A. Addition of Fentanyl to Bupivacaine prolongs anaesthesia and analgesia in axillary brachial plexus block. *Reg Anesthes Pain Med*.2001; 26(5):434-8.
9. Amit Agarwal, Swasthika Chakraborty, Shreya Dixit, Ashok Jadon, Sunil Kr Kedia, Neelam SinhaInterscalene brachial plexus block for shoulder arthroscopic surgery: Prospective randomized controlled study of effects of 0.5% ropivacaine and 0.5% ropivacaine with dexamethasone *Indian Journal of Anaesthesia*, Vol. 59, No. 3, March, 2015
10. Gildasio S. De Oliveira Jr., Lucas J. Castro alves et al Perineural Dexamethasone to Improve Postoperative Analgesia with Peripheral Nerve Blocks: A Meta-Analysis of Randomized Controlled Trials-Pain Research and Treatment Volume 2014 (2014), Article ID 179029
11. Dr. Feroz Ahmad Dar Dr. Neelofar Jan63 Randomized double blinded study Effect of Addition of Dexamethasone to Ropivacaine in Supraclavicular brachial plexus block *IOSR Journal of Dental and Medical Sciences* Volume 10, Issue 4(Sep-oct,2013)
12. Klein SM, Roy A, Grass G, Steele SM, Ercloe FJD, Speer KP, et al. A comparison of 0.5% Bupivacaine, 0.5% Ropivacaine and 0.75% Ropivacaine for interscalene brachial plexus block. *Anaesth Analg* 1998; 87:1316-9.
13. Kumud S. Ganvit1, Akshay H.M., Isha Singhal,62 The efficacy of dexamethasone added as an adjuvant to ropivacaine (0.5%) for brachial plexus block A prospective ranmozed study. *Int J Res Med*. 2014; vol- 3; issue 1
14. Ravi Madhusudan, Krishna Kumar, Ramesh Kumar, Somasekharam Potli, Dinesh Karthik, Manu Kapil. Supraclavicular brachial plexus block with 0.75% ropivacaine and with additives tramadol, fentanyl- a comparative pilot study. *International Journal of Biological & Medical Research* 2011; 2(4): 1061-1063
15. Cummings KC, 3rd, Napierkowski DE, Parra-Sanchez I, Kurz A, Dalton JE, Brems JJ, et al. Effect of dexamethasone on the duration of interscalene nerve blocks with ropivacaine or bupivacaine. *Br J Anaesth*. 2011; 107:446-53.
16. Santhosh Kumar, Urmila Palaria, Ajay Sinha, D.C. Punera and Vijita Pandey; Comparative evaluation of ropivacaine and ropivacaine with dexamethasone in supraclavicular brachial plexus block for postoperative analgesia, a prospective, randomized, double blinded study *Anaesthesia essay and researches may-aug 2014 vol-8; issue -2*
17. Leslie C. Thomas, Sean K. Graham, Kristie D. Osteen, Heather Scuderi Porter, Bobby D. Nossaman Ochsner J. 2011 Fall; 11(3): 246-252
18. Dr R. G. Pathak Dr Anand P. Satkar, Dr Rajendra N. Khade66-Supraclavicular brachial plexus block with and without Dexamethasone; a comparative Study.; *International Journal of Scientific and Research Publications*, Volume 2, Issue 12, December 2012.

