

## Rebound Intracranial hypertension: A Complication of Epidural Blood Patch as Treatment for Intracranial Hypotension

Shashank Rane<sup>1</sup>, Vaishali Shende<sup>2</sup>, Vijay Shetty<sup>3</sup>, Rajesh Benny<sup>4</sup>

**Author's Affiliation:** <sup>1,2</sup>Consultant Anesthetist, <sup>3</sup>Head of the Department, Department of Anaesthesia, Fortis Hospital, Mumbai 400078, Maharashtra, <sup>4</sup>Consultant Neurologist, Department of Neurology, Fortis Hospital, Mumbai 400078, Maharashtra, India.

### Abstract

Rebound intracranial hypertension is a known complication of epidural blood patch. An elderly male presented with nausea, vomiting and poor GCS. The MRI brain showed subdural haematoma with sagging of brain matter suggestive of intracranial hypotension secondary to CSF leak resulting from multiple recent sessions of intrathecal chemotherapy. The patient underwent a lumbar epidural blood patch followed by burr hole procedure under general anaesthesia. The patient had a brief period of complete improvement and subsequently reintubated as his GCS deteriorated. The MRI brain shows mild dilatation of ventricles. The diagnostic lumbar puncture showed a high opening pressure confirming the diagnosis of Intracranial Hypertension. The patient completely resolved symptomatically with oral acetazolamide.

**Conclusion:** Anaesthesiologists must be aware about this condition and efforts at adequate monitoring to detect Intra Cranial Hypertension after an Epidural Blood Patch.

**Keywords:** Epidural blood patch; Rebound intracranial hypertension; Intracranial hypotension.

### Introduction

Epidural blood patch (EBP) is the treatment of choice in cases of post dural puncture headache (PDPH).<sup>1</sup>

Rebound intracranial hypertension (RIH) is a complication of epidural blood patch (EBP) for treatment of intracranial hypotension. It is characterized by headache, vomiting and blurring of vision.<sup>2</sup>

The symptoms of intracranial hypotension due to persistent CSF leak & Rebound intracranial hypertension secondary to the epidural blood patch bear some similarity. It is therefore vital that

these two diametrically opposite clinical conditions with different management strategies are identified early.

We report a case where epidural blood patch administered for treating Refractory Intracranial hypotension with Sub Dural Hematoma caused Rebound Intracranial Hypertension.

### Case History

A 64-year-old male patient was admitted with slurring of speech, drowsiness, upper motor weakness and Glasgow Coma Scale.8

He was a case of Non-Hodgkin's lymphoma

### How to cite this article:

Shashank Rane, Vaishali Shende, Vijay Shetty, Rajesh Benny/Rebound Intracranial hypertension: A Complication of Epidural Blood Patch as Treatment for Intracranial Hypotension/Indian J Anesth Analg. 2021;8(3):413-415.

**Corresponding Author:** Shashank Rane, Department of Anesthesia, Fortis Hospital, Mumbai 4000478, India.

**Email:** shankrane81@gmail.com

and showed excellent remission after receiving six sessions of intrathecal chemotherapy with the last dose given four months prior to the admission. A month before presenting complaint, he had orthostatic hypotension. Intracranial hypotension was suspected due to post dural puncture. The MRI brain shows bilateral smooth dural enhancement, engorged venous sinuses, subdural collection and mild sagging of brainstem was suggestive of intracranial hypotension. He responded well to conservative management.

Following admission to our hospital, the repeat MRI brain showed bilateral subdural haematoma (SDH) with sagging of brain matter. (Figure 1) In view of the borderline GCS the plan was to perform epidural blood patch first followed by the burr hole procedure under general anaesthesia.

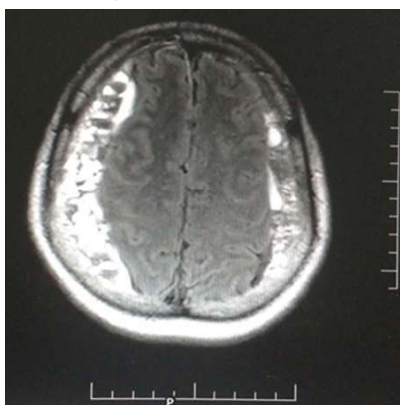


Fig. 1: MRI scan showing massive bilateral subdural hematoma.

Epidural blood patch done in prone position, at L3- L4 spine level, under C arm guidance with 20 ml autologous blood and omnipaq dye 5 ml mixture use to confirm the spread of EBP under C arm. (Figure 2)

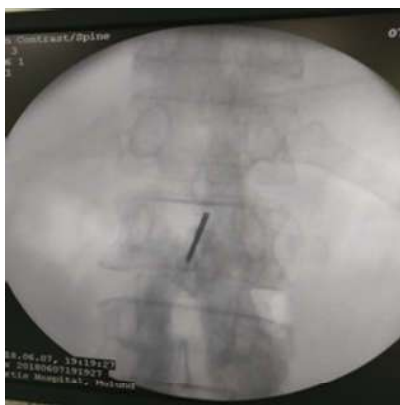

Fig. 2: Epidural blood patch under C ARM.

After epidural blood patch the Neurosurgeon conducted the Burr hole procedure to drain bilateral SDH. Patient improved neurologically

and was extubated after 36 hours of the procedure. However, on day 3, the patient's GCS deteriorated to 7/15 necessitating reintubation.

MRI Brain with contrast showed resolution of the bilateral subdural hematoma, some expansion of the ventricular system and no meningeal enhancement.

The Neurologist suspected intracranial hypertension secondary to epidural blood patch and suggested a diagnostic lumbar puncture.

On day 4, lumbar puncture was done at L3-4 interspace with 22 g spinal needle in lateral decubitus. The opening pressure was 25 cm of water. A diagnosis of Rebound Intracranial Hypertension was made.

He was started on medical management with Acetazolamide at a dose of 250 mg b.d. Patient improved neurologically and was extubated the next day. He was discharged with complete neurological recovery on 22<sup>nd</sup> day.

## Discussion

Rebound intracranial hypertension is a clinical entity characterized by an increase in the absolute or relative ICP leading to severe headache, nausea and vomiting. It can occur secondary to EBP administered for Intracranial hypotension. Our case report intends to sensitize anaesthesiologists to the possibility of RIH following a blood patch. Multiple factors may be responsible including persistence of the compensatory changes to Intracranial hypotension or anatomical abnormalities like transverse sinus stenosis.<sup>3</sup> Misdiagnosing RIH as an Intracranial Hypotension may lead to potentially dangerous interventions such as a second blood patch and worsening of the RIH.

In the present case, the patient had multiple lumbar punctures as part of Intrathecal Chemotherapy for his Lymphoma. He presented with neurological deterioration with a SDH. Takahashi et al have recommended the Epidural blood patch as first line of treatment in stable patients with Spontaneous intracranial hypotension (SIH) presenting with SDH.<sup>4</sup> In his series of SIH with SDH, 45% and 35% of patients had CSF leaks in the lumbar area and thoracic region respectively. Correcting the low intracranial pressure with the EBP often leads to spontaneous resolution of the SDH.<sup>5</sup> In patients with poor GCS, Takhashi has suggested Burr hole evacuation following an EBP. We decided upon a similar course for our patient.

CSF myelography is the gold standard to identify

CSF leak.<sup>5</sup> It was not carried out in this patient in view of bilateral SDH. C-ARM guided EBP with radiopaque dye confirmed epidural space and extent of spread of the injectate as recommended by White et al.<sup>1</sup>

As the patient deteriorated neurologically after a temporary improvement, rebound intracranial hypertension due to epidural blood patch was suspected. RIH was then confirmed by the opening pressure of the CSF by lumbar puncture of 25 cm of water mandating medical therapy.

Kranz et al, in their series of RIH, however have warned that the absolute opening pressure may be less important in this situation and the relative rise in pressure compared to the low baseline pressure may play a significant role.<sup>2,3</sup>

The type of headache may help to differentiate RIH and Refractory Intracranial hypotension. The frontal and peri-orbital headache in RIH have characteristics similar to those seen in raised ICP and is worse in supine with associated vomiting with a morning prevalence.

In intracranial hypotension, the evening headache is occipital in distribution and worse in upright position.<sup>2,3</sup>

The volume of blood for the EBP correlated poorly with the likelihood of developing RIH Kranz et al, in their series of 9 patients had used between 5ml to 40 ml of blood in his patients who subsequently developed RIH.<sup>2</sup> It is important to note that RIH should be kept as a part of the differential diagnosis as the time frame in the series varied between 2 hours to days and with one case presenting after one year.

Treatment for RIH is decreasing CSF pressure by CSF drainage with carbonic anhydrase inhibitor acetazolamide 250 mg BD and IV glycerol may be added.<sup>6</sup>

## Conclusion

Rebound intracranial hypertension is a lesser known complication of epidural blood patch. Any post epidural blood patch complaints of front orbital headache, vomiting, blurring of vision should elicit a strong suspicion of this condition. Anaesthesiologists must be aware about this condition and efforts at adequate monitoring to detect and report this entity after an EBP. The possible occurrence of this condition must be discussed with the patient and family. As in our case, a good outcome is assured by timely diagnosis and medical management.

## References:

1. White B, Lopez V, Chason D, Scott D, Stehel E, Moore W. The lumbar epidural blood patch: A Primer. *Appl Radiol.* 2019;48(2):25-30.
2. Kranz P.G., Amrhein T.J, Gray L. Rebound intracranial hypertension: a complication of epidural blood patching for intracranial hypotension. *AJNR Am J Neuroradiol.* 2014 Jun;35(6):1237-40.
3. Wouter I. Schievink, M. Marcel Maya, Stacey Jean-Pierre, Franklin G. Moser, Miriam Nuño, Barry D. Pressman. Rebound high-pressure headache after treatment of spontaneous intracranial hypotension MRV study. *Neurol Clin Pract Apr* 2019, 9 (2) 93-100; DOI: 10.1212/CPJ.0000000000000550.
4. Koichi TAKAHASHI, Tatsuo MIMA, and Yoichi AKIBA. Chronic Subdural Hematoma Associated with Spontaneous Intracranial Hypotension: Therapeutic Strategies and Outcomes of 55 Cases. *Neurol Med Chir (Tokyo).* 2016 Feb; 56(2): 69-76.
5. Cebeci H, Cem Bilgin. Spinal Cerebrospinal Fluid Leakage in Spontaneous Intracranial Hypotension: An Intrathecal Gadolinium Enhanced MR-Myelography Study. *Journal of the Belgian Society of Radiology.* 2020; 104(1): 6, 1-7.
6. Meibodi, R., Abolqasem, Ali, M.A., Mohammad, S., Mansouri, Mehrdad, Akbarian, Abolfazl. 2018. The effect of topiramate and acetazolamide in patients with idiopathic intracranial hypertension compared to acetazolamide alone. *Bali Medical Journal* 7(1): 201-204.

