

A Morphological Study of Placenta in Patients of Eclampsia

Ashutosh Gupta¹, Manoj Kumar Sharma², Varsha Porwal³,
Hemlata Sharma⁴, Manju Agarwal⁵

How to cite this article:

Ashutosh Gupta, Manoj Kumar Sharma, Varsha Porwal, *et al.* / A Morphological Study of Placenta in Patients of Eclampsia / Indian J Anat. 2023;12(2):53-59.

Abstract

Objective: Eclampsia frequently complicates pregnancy, which in turn affects the placenta's macroarchitecture and functions as well as the prenatal health of both the mother and the unborn child. Hence, this study was conducted to assess the morphological changes in the placenta among eclamptic and normotensive pregnant mothers.

Methods: A Case control study was performed. Detailed clinical history was taken and placenta were collected from both 33 eclamptic and 33 normotensive mothers delivered in the labour room or operation theatre. Gross morphological analysis was performed. Results were noted and statistically analysed.

Results: The average weight, diameter, placental thickness and number of cotyledons were 427.88±65.88 grams, 15.79±1.56 centimetre, 1.87±0.50 centimetre and 11.97±2.73 in patients of eclampsia and 502.57±64.12 grams, 16.77±1.64 centimetre, 2.15±0.35 centimetre and 16.64±3.21 in normotensive patients respectively. The average weight, diameter, placental thickness, systolic blood pressure, diastolic blood pressure, number of cotyledons and presence of retroplacental hematoma in cases versus controls was found to be statistically significant. The variation in shape of placenta and umbilical cord insertion was statistically insignificant.

Conclusion: Effects of eclampsia in pregnancy are reflected in gross findings of placenta, which may contribute to the further management of mother and baby.

Keywords: Placenta; Eclampsia; Morphology; Pregnancy.

Author's Affiliation: ¹PG Resident, ²Senior Professor, ³Assistant Professor, ⁴Associate Professor, Department of Anatomy, ⁵Senior Professor, Department of Obstetrics and Gynecology, Jhalawar Medical College, Jhalawar 326001, Rajasthan, India.

Corresponding Author: Ashutosh Gupta, PG Resident, Department of Anatomy, Jhalawar Medical College, Jhalawar 326001, Rajasthan, India.

E-mail: ashugupta8993@gmail.com

Received on: 11.03.2023

Accepted on: 14.04.2023

INTRODUCTION

Hypertensive disorders complicating pregnancy are common and form one of the deadly triad, along with hemorrhage and infection that contribute greatly to maternal morbidity and mortality.¹ They include:

- **Gestational hypertension:** BP \geq 140/90 mmHg for the first time in pregnancy after 20 weeks, without proteinuria.

- **Preeclampsia:** Gestational hypertension with proteinuria.
- **Eclampsia:** Women with preeclampsia complicated with grand mal seizures and/or coma.
- **Chronic hypertension:** Known hypertension before pregnancy or hypertension diagnosed first time before 20 weeks of pregnancy.
- **Superimposed pre eclampsia or eclampsia:** Occurrence of new onset of proteinuria in women with chronic hypertension.

Changes in placenta in hypertensive disorders

In hypertensive disorder, resistance to flow in utero-placental circulation is found to be increased. It also affects the growth of placenta in terms of:

- Reduction in diameter^{2,4}
- Decreased weight^{2,3,5}
- Reduced thickness²
- Decreased no of cotyledons^{3,4,6,7}
- Reduced surface area²
- Reduction in volume^{2,4}
- Increased incidence of placental hematoma²

*Eclampsia*⁸

Eclampsia is classified according to the time of onset:

- **Antepartum eclampsia:** (50%) convulsions occurring before the onset of labour.
- **Intrapartum eclampsia:** (30%) convulsions occurring for the first time during labour.
- **Postpartum eclampsia:** (20%) convulsions occurring for the first time in puerperium, usually within 48 hours of delivery convulsions occurring beyond 7 days of delivery rules out eclampsia.
- **Intercurrent eclampsia:** when convulsions are controlled in antepartum eclampsia and pregnancy continues for at least 10 days after cessation of convulsions, foetus being alive.

The hospital incidence of eclampsia in India ranges from 1 in 500 to 1 in 30. It is more common in primigravidae (75%), five times more common in twins than in singleton pregnancies and occurs between the 36th week and term in more than 50% cases.⁹

OBJECTIVES

The placenta can be examined to provide information that may be useful for both immediate and long-term management of the mother and the child. In the event of a poor mother or foetal result, this information can also be crucial for safeguarding the attending physician. With this background the study was carried out with the following objectives:

1. To assess the morphological changes in placenta in eclampsia.
2. To compare these findings with those of human placentae of normal pregnancies.

MATERIALS AND METHODS

Study site, population and period: The study was conducted in the Department of Anatomy, Pediatrics and Gynecology, Jhalawar Medical College and attached hospitals, Jhalawar. Women who came for delivery (normal and eclamptic) in Shrimati Heera Kunwar Ba Mahila Hospital attached to Jhalawar Medical College, Jhalawar. Duration of study was one year, from February 2022 to January 2023.

Study design: Case control study

Sampling: Simple randomised sampling was done. Sample size for this study was calculated using Cochran formula. With 95% confidence interval and margin of error as 0.05 the sample size was 33 cases and 33 controls.

Inclusion criteria: All the patients delivered either by vaginal route or by caesarian section were considered in the study. Age between 18-40 yrs; cases of: eclampsia, superimposed eclampsia; singleton pregnancy; gestational age between 28-42 weeks.

• **Signs and symptoms of Eclampsia included:**

- ◇ Headache
- ◇ Epigastric or right upper quadrant pain: particularly in HELLP syndrome due to liver dysfunction.
- ◇ Visual symptoms: scotomas progressing to blurred vision, even blindness.
- ◇ CNS irritability / grand mal seizure.

• **Laboratory findings of Eclampsia included:**

- ◇ Hemoconcentration leads to false high Hb.
- ◇ Thrombocytopenia
- ◇ RFTs: Serum Uric Acid >4.5mg/dl, BUN, serum creatinine derange only in severe cases.

- ◇ LFTs: raised liver enzymes in severe cases.
- ◇ Increased fibrinogen, it is decreased in abruption.

Exclusion criteria: Gestational age < 28 weeks & > 42 weeks; multiple pregnancies; cases of: gestational hypertension, pre-eclampsia, chronic hypertension; other medical or surgical illness; patients whose blood report, urine report, consent were not available.

Study techniques:

1. Case history and clinical examination
2. Collection of the specimen
3. Examination of the specimen
4. Statistical Analysis

Detailed obstetric and medical histories were taken for all cases, clinical examination done and they were subjected to various investigations. Just after delivery all the placentae were collected in a clean tray. The membranes and cord at their attachment to the placenta were cut off. The placenta was gently expressed so as to remove its blood content and then washed thoroughly under tap water and mopped with dry cotton pad. The following parameters were used for comparison among various study groups: weight, diameter, thickness, number of cotyledons, shape of placenta, insertion of umbilical cord & presence of retroplacental hematoma.

Statistical analysis: All data was collected

Table 1: Comparison of macroscopic changes

Gross Changes	Eclampsia	Controls	T value	p-value
Weight (gm)	427.88±65.88	502.57±64.12	4.6671	<0.0001*
Average diameter (cm)	15.79±1.56	16.77±1.64	2.4872	0.0155*
Thickness (cm)	1.87±0.50	2.15±0.35	2.6354	0.0105*
Maternal Cotyledons	11.97±2.73	16.64±3.21	6.3663	<0.0001*

#Unpaired t test, *Significant

number of maternal cotyledons in placenta among the groups. The average number of maternal cotyledons in placenta in cases and controls were 11.97±2.73 & 16.64±3.21 respectively. The unpaired t test revealed that there was significant ($p < 0.0001$) difference in number of maternal cotyledons in placenta among the groups, with cases having a fewer number of maternal cotyledons.

through predesigned performa and entered in MS-Excel. Data was analysed with the help of SPSS 26.0 (trial version) and all applicable statistical tests were used for data analysis. p value less than 0.05 was considered as significant.

RESULTS

Table 1 shows the comparison of the mean weight of placenta among the groups. The average weight of placenta in cases and controls were 427.88±65.88 & 502.57±64.12 gm respectively. The unpaired t test revealed that there was significant ($p < 0.0001$) difference in weight of placenta among the groups, with cases having a lower weight.

Table 1 shows the comparison of the average diameter of placenta among the groups. The average diameter of placenta in cases and controls were 15.79±1.56 & 16.77±1.64 cm respectively. The unpaired t test revealed that there was significant ($p < 0.05$) difference in diameter of placenta among the groups, with cases having a lesser diameter.

Table 1 shows the comparison of the thickness of placenta among the groups. The average thickness of placenta in cases and controls were 1.87±0.50 & 2.15±0.35 cm respectively. The unpaired t test revealed that there was significant ($p < 0.05$) difference in thickness of placenta among the groups, with cases having a lesser thickness.

Table 1 shows the comparison of the average

Table 2 shows the comparison of umbilical cord insertion among the groups. Eccentric insertion was seen in 48.48% cases and 36.39% controls. Central cord insertion was seen in 39.39 & 60.61%, whereas marginal was seen in 12.12 & 3% of cases and controls respectively. There was no significant difference in the variation of attachment of umbilical cord between case & controls.

Table 2: Comparison of umbilical cord insertion

Umbilical cord insertion	Eclampsia		Controls		Chi sq.	p-value#
	No.	%	No.	%		
Central	13	39.39	20	60.61		
Eccentric	16	48.48	12	36.39	3.856	0.1454
Marginal	4	12.12	1	3		

#Chi-Square test

Table 3 shows the comparison of the shape of placenta among the groups. Oval placenta was present in 72.73 & 69.7%, while circular placenta was present in 27.27 & 30.3% of cases and controls

respectively. Oval was in majority of the placenta in all the groups with an insignificant difference between the groups.

Table 3: Comparison of the shape of placenta

Shape	Eclampsia		Controls		Chi sq	p-value#
	No.	%	No.	%		
Circular	9	27.27	10	30.3	0.074	0.7856
Ovoid	24	72.73	23	69.7		

#Chi-Square test

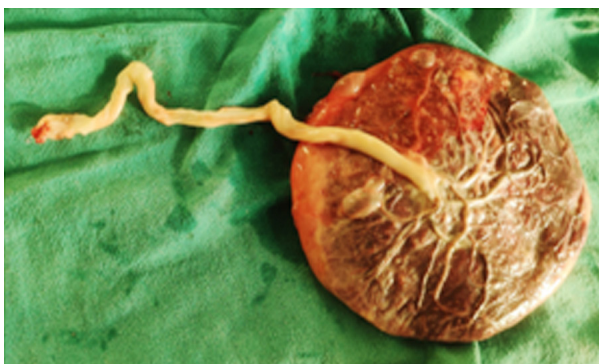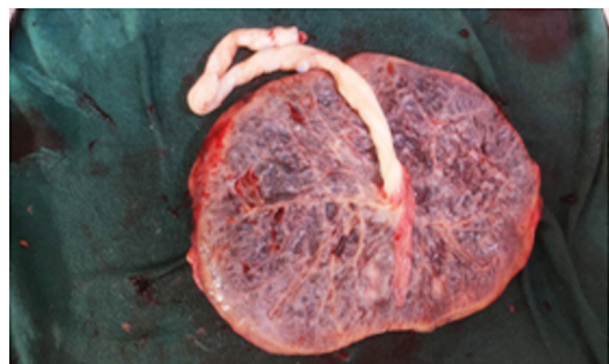
Table 4 shows the comparison of retroplacental hematoma among the groups. Retroplacental hematoma was present in 48.48% of eclamptic patients and 9.1% of normotensive patients. The Chi-

Square tests showed that presence of retroplacental hematoma was significantly ($p < 0.001$) lower in controls as compared to cases.

Table 4: Comparison of retroplacental hematoma

Retroplacental hematoma	Eclampsia		Controls		Chi sq	p-value#
	No.	%	No.	%		
Present	16	48.48	3	9.1	12.49	0.0004*
Absent	17	51.52	30	90.9		

#Chi-Square test, *Significant

**Fig. 1:** Circular shape of placenta**Fig. 2:** Oval shape of placenta

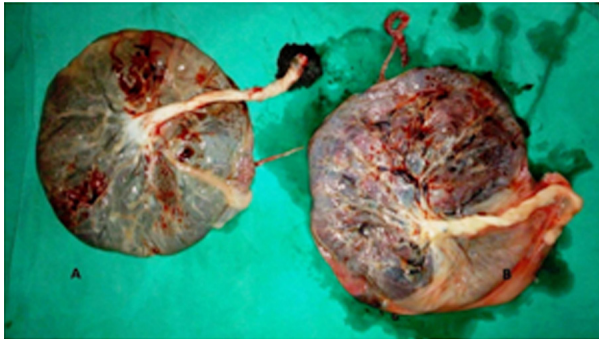


Fig. 3: Umbilical cord insertion: A- Central insertion, B- Eccentric insertion

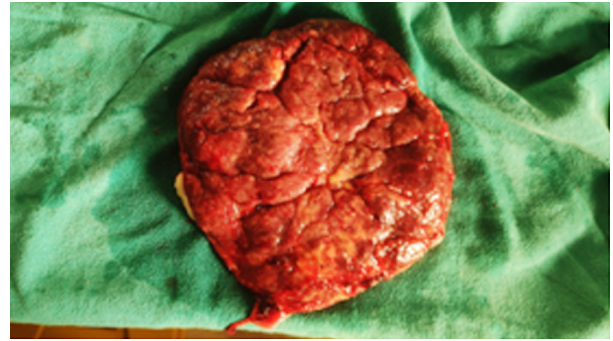


Fig. 4: Maternal surface showing cotyledons of placenta

DISCUSSION

In a study (*Ranga et al, 2017*)¹⁰, the mean placental weight of hypertensive group was 455.7±59.9 gms and in the normal group was 516.7±25.7 gms which was statistically significant ($p < 0.01$). In another study by *Nahar L et al (2014)*¹¹ mean placental weight in the PIH group was 419.50gm and in the control group was 477.50gm which was statistically significant ($p < 0.001$). *Usman et al (2015)*¹² in a study revealed that mean placental wt. in (grams) was 485.24 ± 47.29 & 397.08 ± 89.32 in normal and hypertensive groups which was statistically significant ($p < 0.01$). The findings of all the above mentioned studies were in line with the finding of this study in which it was observed that mean weight of placenta in eclampsia was significantly (< 0.0001) lower as compared to normal pregnancies.

In this study the average diameter of cases and controls are 15.79 ± 1.56 & 16.77 ± 1.64 cm respectively. The decrease in placental diameter in cases was significant as compared to controls which was similar to the study conducted by *Ranga et al (2017)*¹⁰ in which he found that the mean placental diameter 14.1 ± 0.7 & 19.1 ± 0.9 cm in PIH and normal pregnancy respectively and the difference was significant. *Suchithra et al (2015)*¹³ in her study found 26/50 placental diameter less than 15 cm and 24/50 placental diameter more than 15 cm in mild PIH and 41/50 placental diameter less than 15 cm & 09/50 placental diameter more than 15 cm in severe PIH. Whereas less than 15 cm placental diameter in 17/50 and more than 15 cm placental diameter in 33/50 in normal placenta. She concluded that the size of the placenta decreases in PIH.

In this study the mean placental thickness of cases and controls are 1.87 ± 0.50 & 2.15 ± 0.35 cm respectively. The decrease in placental thickness in cases was significant as compared to controls which was similar to the study conducted by *Ranga et al*

(2017)¹⁰ in which he found that the mean placental thickness 1.9 ± 0.9 & 2.4 ± 0.1 cm in PIH and normal pregnancy respectively and the difference was significant. *Thakur C et al (2018)*¹⁴ in their study also concluded that the mean placental thickness significantly decreases in hypertensive group as compared to the control group. *Bar P K et al (2019)*² observed that the difference in mean placental thickness was found to be statistically significant ($p < 0.05$) with lower thickness in hypertensive group.

In this study the mean number of cotyledons in cases and controls are 11.97 ± 2.73 & 16.64 ± 3.21 respectively. The decrease in placental diameter in cases was significant as compared to controls which was similar to the study conducted by *Thakur C et al (2018)*¹⁴ in which he concluded that the mean number of cotyledons significantly decreases in hypertensive group as compared to the control group. *Wubale Y et al (2017)*⁶ observed in their study that the number of cotyledons in placenta was 17.24 ± 1.06 in preeclamptic and 18.66 ± 1.21 in normotensive mothers. Number of cotyledons of placenta was significantly ($p < 0.001$) decreased in preeclamptic mothers as compared to normotensive mothers.

The present study revealed that the commonest site of insertion of the umbilical cord was eccentric in eclamptic pregnancies and central in normal pregnancies. In this study, we also found that the prevalence of marginal cord insertions was more in pre-eclamptic pregnancies as compared to normal pregnancies, however these findings were not significant. These findings are in accordance with *Divya J A et al (2018)*¹⁵ *Udaina A et al (2014)*¹⁶ described that the normal site of insertion of the umbilical cord is eccentric in both normal and pre-eclamptic pregnancies.

In this study it was observed that there was no significant relation between the shape of placenta and eclampsia. In a study conducted by *Bar P K et*

al (2019)² most common shape found was round, in 62.5% of the placenta in normotensive mothers and 57.5% of the placenta in hypertensive mothers. Shapes of the placenta have got no statistical significance (p value=0.648). *Agarwal GC et al* (2015)¹⁷ concluded in their study that the shape of placentae did not show significant variation in PIH vs normal patients.

In our study Incidence of retroplacental hematoma was significantly higher (p<0.001) in the eclamptic group (48.48%) vs normal group (9.1%). In their study *Bar P K et al* (2019)² found the incidence of retroplacental hematoma was significantly higher in hypertensive groups with a relative risk of 4. *Fox H* (1997)¹⁸ found 3 fold increase of retroplacental hematoma in placenta of pre-eclamptic mothers which mimics observation of our study.

CONCLUSION

This study revealed that the morphometric parameters of placenta like mean thickness, weight, diameter and number of maternal cotyledons are found to be significantly reduced, while the number of cases of retroplacental hematoma were significantly increased in eclamptic pregnancy as compared to normal pregnancy. The shape of placenta and the location of umbilical cord insertion are not significantly affected in patients of eclampsia. Eclampsia causes many adverse macroscopic changes in placenta. These findings may help in the treatment of eclamptic mothers and their offsprings. How these morphological and histopathological changes affect the maternal and perinatal outcome needs to be studied separately. Additionally, these could defend the medical staff in the event that a patient goes into labour in an emergency and does not have a proper history of prenatal checkups.

REFERENCES

- Cunningham, F. Gary,, et al. Williams Obstetrics. 22nd edition. New York: McGraw-Hill Education, 2005.; 51-82,762.
- Bar PK, Ghosh S, Gayen P, Mandal S, De A. Morphological study of placenta in hypertensive disorders in pregnancy. Trop J Path Micro 2019;5(6):366-373. doi:10.17511/jopm.2019.i06.06.
- Khan NA, Nahid N, Choodhury M, Islam K, Mehzabin S. Morphological study of placenta in selected normotensive and preeclamptic women in Bangladesh. J Dhaka Med Coll. 2020; 29(2): 171-177.
- Goswami PR, Shah SN. Placenta in Normal and Pregnancy Induced Hypertension in Relation to its Clinical Significance: A Gross Study. Int J Sci Stud 2016;4(7):58-61.
- Gore CR, Pandey A, Shetty A, Rao R, Paranjape S. A study on histopathological changes in placenta in pre-eclampsia/eclampsia: A case-control study in a tertiary care centre, western India. Ind J Pathol Oncol, 2018;5(3):385-390.
- Wubale Y, Tolera A. Gross morphological study of placenta in preeclampsia mothers. Anatomy Journal of Africa. 2017. 6 (2): 977 -981.
- Salmani D, Purushothaman S, Somashekara SC, Gnanagurudasan E, Sumangaladevi K, Harikishan R, et al. Study of structural changes in placenta in pregnancy-induced hypertension. J Nat Sc Biol Med 2014;5:352-5.
- Mudaliar and Menons. Hypertensive disorders of pregnancy. Clinical Obstetrics, Chapter 18; Chennai Orient Longman Ltd, 1997 p.133-154.
- DC Dutta's Textbook of obstetrics including perinatology and contraception.8th Ed. New Delhi; Jaypee Brothers Medical Publishers (P) Ltd.; 2015: 268.
- Ranga M K Siva Sree, Kumar K V, Thangam Adaline, Mallika M C Vasantha. Morphological Variations of Human Placentae in Preterm Labor, Pregnancy-induced Hypertension, and Gestational Diabetes Mellitus. International Journal of Scientific Study 2017; 4 (11).
- Nahar L, Nahar K, Hossain MI, Jahan S, Rahman MM. Placental changes in pregnancy induced hypertension. Mymensingh Med J 2013;22(4):684-93.
- Usman JD, Bello A, Musa MA et. al. Morphometric assessment of the placenta in women with gestational hypertension: findings from a rural community in Sokoto, Nigeria. Int J Health Sci Res. 2015; 5(3):70-74.
- Suchithra A. Shetty, Ashwini Kolar. Placenta in Normal Pregnancy vs. Placenta in Pregnancy in Induced Hypertension: A Morphological and Histopathological Study. Journal of Evidence based Medicine and Healthcare 2015; 2 (45): 8142-8145.
- Thakur C, Singh T, Shankar B, Sharma S, Bindra GS. Morphometric and Morphological Study of Human Placenta in Hypertensive Females of West U. P. India. Ann Int Med Dent Res. 2018;4(3).
- Divya J. A., Ramdas N., Ajay U. Variations in placental attachment of umbilical cord and vascular pattern of chorionic blood vessels in pre-eclamptic pregnancies. International Journal of Advances in Science Engineering and Technology, ISSN(p): 2321 -8991, ISSN(e): 2321 -9009 Vol-6, Iss-1, Spl. Issue-1 Feb.-2018,13-17.
- Udania A,mehta CD,Chauhan K,Suthur K,Chauhan K.Relation between umbilical cord insertion and

- foetal outcome in pregnancy induced hypertension. International Journal of Basic and Applied Medical Sciences .2014 Jan;4(1):332-7.
17. Agarwal Gyan C, Pandey N, Jain A. Morphological study of placenta in normal and hypertensive pregnancies. IAIM 2015; 2(5): 121-128.
18. Fox H. Pathology of the Placenta. 2nd ed. W B: Saunders, London; 1997.

