

Role of Indigenous Modified Splint for Management of Stiffness of finger during the Covid-19 Crisis

Neljo Thomas¹, Ravi Kumar Chittoria², Nishad K³, Barath Kumar Singh⁴,
Jacob Antony Chakiath⁵

How to cite this article:

Neljo Thomas, Ravi Kumar Chittoria, Nishad K, et al./Role of Indigenous Modified Splint for Management of Stiffness of finger during the Covid-19 Crisis/Indian J Anat. 2023;12(1):31-34.

Abstract

Stiff finger is a common condition found among the elder population due to various types of arthritis. In the younger age group it occur ususally as a sequel of trauma. It siaadifficult condition to treat and follow up. Patient cooperation and strict adherence to exercise routines in paramount for success of treatment of stifffinger. The ideal treatment includes release of the adhesions, active physiotherapy. However because of the covid 19 crisis, the usual treatments of the various disease have been compromised due to lack of travel, transport, need to maintain social distancing etc. We devised our own splint managment for stiff finger and found it to useful.

Keywords: Stiff finger; COVID-19; Corona pandemic.

INTRODUCTION ????????????????????

0000000000000000

Author's Affiliation: ^{1,3-5}Senior Resident, ²Professor, Department of Plastic Surgery, Jawaharlal Institute of Postgraduate Medical Education and Research (JIPMER) Pondicherry-605006, India.

Corresponding Author: Ravi Kumar Chittoria, Professor, Department of Plastic Surgery, Jawaharlal Institute of Postgraduate Medical Education and Research (JIPMER) Pondicherry-605006, India.

E-mail: drchittoria@yahoo.com

Received on: 13.12.2023

Accepted on: 26.12.2023

METHODOLOGY

This study was conducted during the COVID -19 pandemic in a tertiary care center in the department of plastic surgery with departmental committee ethical approval. 48 year old gentle man with history of the hit of cricket ball on the tip of ring finger and had difficulty in movement of proximal interphalangeal joint (PIPJ) of ring finger with pain and edema of the finger 1 month back. Patient consulted the nearby indigenous treatment centre and treatment was done with massaging treatment. The patient developed pain on moving the finger and discontinued treatment after 1 week, the patient continued with daily activities and started noticing difficulty in movements of the ring finger, the patient showed to Dept. of Plastic Surgery and was diagnosed with injury to central slip and PIPJ capsule, with flexion contracture of the PIPJ and splinting and physiotherapy was planned for the patient. However in view of the COVID crisis, only

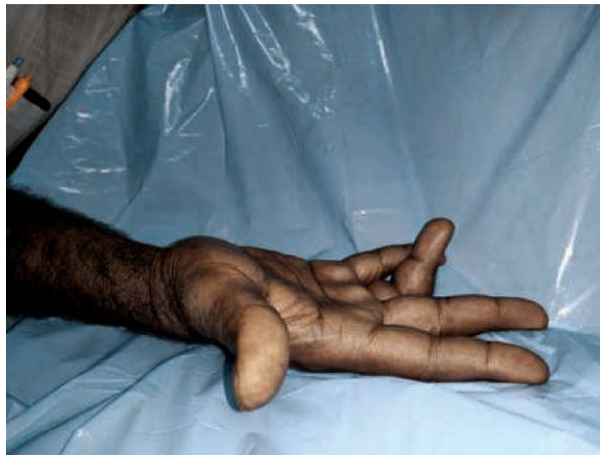

Fig. 1: Patient with flexion contracture of PIPJ of right ring finger

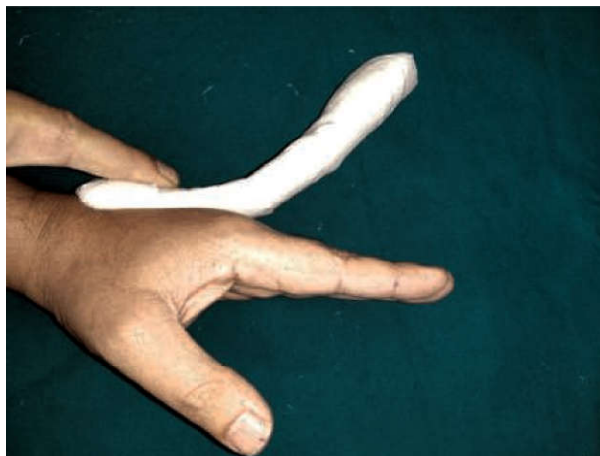

Fig. 2: Thermoplastic material modified into indigenous splint

emergency services were rendered in our hospital, hence we resorted to our own indigenous dynamic splint for the patient made from materials easily available in hospital. The splint was made with thermoplastic material which was given an angle of about 45 degree, a hammock made from rubber gloves, dynaplast, Velcrostraps, scissors. The splint was made and gave an extension vector at the PIPJ. The patient was advised to continue with the splint during day time and give rest during the night time. Patient was advised to be on follow up and definitive therapy once the COVID crisis resolves or when elective OPD restarts.

RESULTS

The dynamic splint provided extension pull on the PIPJ of the ring finger, which allowed for stopping the progression of the contracture till definitive procedure was given.

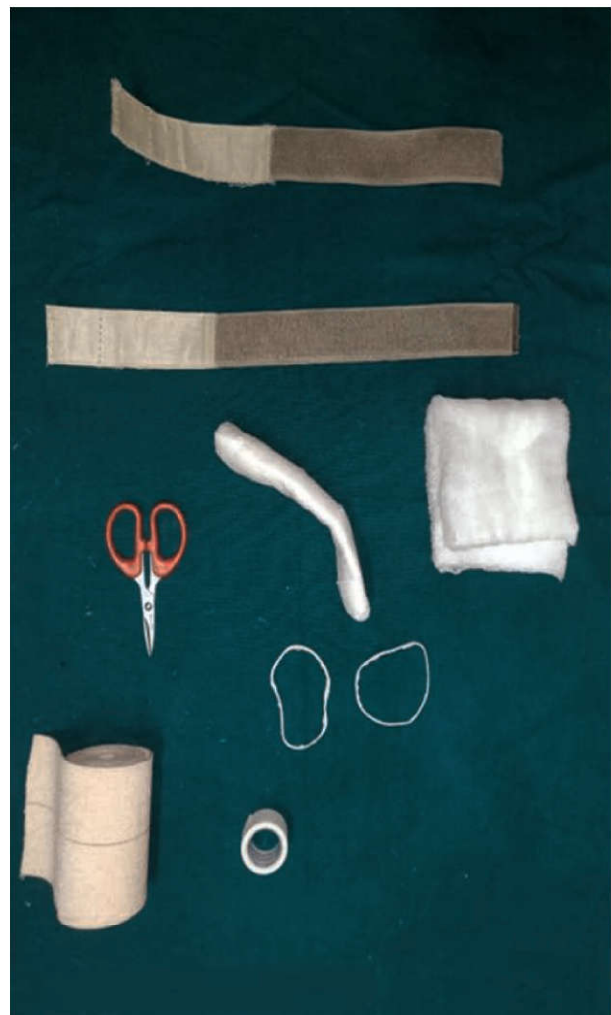


Fig. 3: Materials needed to make the dynamic splint

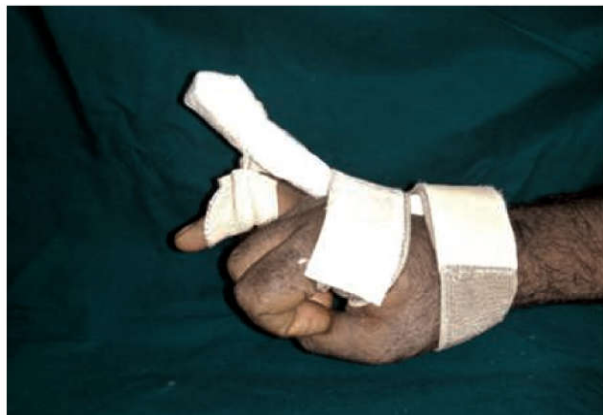

Fig. 4: Dynamic indigenous splint applied to patient

DISCUSSION

In December 2019 World Health Organization declared COVID-19 (Corona Virus Disease-2019) as a pandemic involving various countries including India. WHO has advised social distancing to prevent the spread of disease from health care workers to patients, between patients, from patient to his/her attendant, from attendant to another attendant. The high risk procedures like intubation, cauterization which are aerosol generating procedures have to be kept to a minimum to avoid exposure to the disease.

Stiff finger," defined as a finger with decreased range of motion in single or multiple joints, is found after hand injury and is classified into flexion or extension deformities. The initial response to any injury is inflammation, with pain and edema. By 7 days leukocytes and mediators surround the injury resulting in proliferation phase, which lasts for approximately 3 weeks. Collagen get deposited initially in a disorganized way, causing adhesions. The final stage of the response to injury is remodeling of disorganized collagen. At completion of this phase, complete healing with supple skin and soft tissue, and resolution of edema.

The initial treatment consists of program aimed at softening and stretching scar tissue as well as maximizing passive range of motion (ROM).^{1,2,3} Exercises are often supplemented with splinting: dynamic, static-progressive, or serial static splints. All types of splints apply mechanical force to the joints at its end of motion to improve stretching of contracted tissues. Static and static-progressive splinting apply inelastic forces to the joint to position it with maximal stretch, but needs adjusted frequently. Dynamic splints apply a preset force across the joint using springs or elastics to position the joint at maximal stretch. Both type

of splinting regimen has been demonstrated to be equally effective.³In a series of 212 stiff joints, therapy alone successfully treated 87% of PIP joint and MCP joint contractures.⁴ The groups of Flowers and Glasgow 5-7 demonstrated that passive ROM gains are function of increasing the splint time and force applied. However, the optimal intensity and duration of therapy is ill defined. Excessive external force can cause damage from tearing of soft tissues and ligaments or articular subluxation. Time spent splinting reach a practical maximum based on the limits of patient tolerance.^{5,7} Numerous researchers have investigated external splints for mobilizing a PIP joint flexion contracture.^{8,9,10,11} These devices, which needs to be fixed by surgery apply skeletal traction across the PIP joint by gradual extension or distraction as the device gets adjusted. These devices stretch the deeper capsuloligamentous tissues and musculotendinous units but also stretch the soft tissue and fascia, like in Dupuytren contracture. Institutional results from these devices have shown promising improvements in PIP joint arc of motion, with a mean of 67 over long-term follow-up.¹⁰

CONCLUSION

The splint allowed to provide continuous extensor pull on the PIPJ finger and stopped the aprogression of the contracture. Patient was asked to be on regular follow up till COVID crisis settles for definitive procedure.

DECLARATIONS

Acknowledgment

Authors' contributions: All authors made contributions to the article

Availability of data and materials: Not applicable.

Financial support and sponsorship: None.

Conflicts of interest: None.

Consent for publication: Not applicable.

Copyright: © The Author(s) 2020.

REFERENCES

1. Young VL, Wray RC, Weeks PM. The surgical management of stiff joints in the hand. *Plast Reconstr Surg* 1978;62:835-41. Houshian S, Jing SS, Chikkamuniyappa C, et al.
2. Management of posttraumatic proximal interphalangeal joint contracture. *J Hand Surg Am*

- 2015;40:2081-4.
3. Michlovitz SL, Harris BA, Watkins MP. Therapy interventions for improving joint range of motion: a systematic review. *J Hand Ther* 2004;17(2):118-31.
 4. Weeks PM, Wray RC, Kuxhaus M. The results of nonoperative management of stiff joints in the hand. *PRS* 1978;71:58-63.
 5. Glasgow C, Wilton J, Tooth L. Optimal daily total endrange time for contracture: resolution in hand splinting. *J Hand Ther* 2003;16(3):207-18.
 6. Flowers KR, La Stayo P. Effect of total end range time on improving passive range of motion. *J Hand Ther* 1994;7(3):150-7.
 7. Flowers KR. A proposed decision hierarchy for splinting the stiff joint, with an emphasis on force application parameters. *J Hand Ther* 2002;15(2):158-62.
 8. Agee JM, Goss BC. Use of skeletal extension torquein reversing Dupuytren contractures of the proximalinterphalangeal joint. *J Hand Surg* 2012;37:1467-74.
 9. Houshian S, Chikkamuniyappa C, Schroeder H. Gradual joint distraction of post-traumatic flexioncontracture of the proximal interphalangeal joint by a mini-external fixator. *J Bone Joint Surg Br* 2007;89(2):206-9.
 10. Houshian S, Jing SS, Kazemian GH, et al. Distraction for proximal interphalangeal joint contractures: long-term results. *J Hand Surg Am* 2013;38:1951-6.
 11. Houshian S, Chikkamuniyappa C. Distraction correction of chronic flexion contractures of PIP joint: comparison between two distraction rates. *J Hand Surg* 2007;32(5):651-6

