

Study of Anatomical Variants of the Temporal Bone Pen Process during Eagle's Syndrome

Mar Ndeye Bigué¹, Loum Birame², Niang Ibrahima³, Yacouba Garba Karim⁴, Deme Hamidou⁵, Akpo Géraud Léra⁶, Diop Mamadou⁷, Diallo Bay Karim⁸, Ndiaye Assane⁹

How to cite this article:

Mar Ndeye Bigué, Loum Birame, Niang Ibrahima, *et al.* / Study of Anatomical Variants of the Temporal Bone Pen Process during Eagle's Syndrome / Indian J Anat. 2023;12(1):23-29.

Abstract

Anatomical variations of the pen process (PS) and ossification of the pen-hyoid ligament constitute Eagle syndrome. This is a rare syndrome, often bilateral, that summarizes the clinical manifestations due to an excessive length of the pen process that is greater than 25mm. Other important morphometric and topographical variations are associated with this anomaly.

Taking these anatomical data into account is essential for the etiopathogenic analysis and surgical treatment of Eagle syndrome. The purpose of this work was to investigate anatomical variations of the pen process during Eagle syndrome.

Materiel and method: This was a retrospective study over a period of 07 months from December 2020 to June 2021 inclusive. It concerned 32 patients, received in the radiology and medical imaging department of the National Pikine Hospital for suspicion of Eagle syndrome confirmed by scanner without and with injection. Patients who had a normal scanner were not included in the study. We used SPSS 24.0 and Excel 2016 to analyze the data.

Resultats: 24 women (75%) and 8 men (25%), a sex ratio of 0.33. The average age of patients was 39 years, a standard deviation of 12 years and extremes of 21 to 71 years. The age range of 30-40 was 34% and 41-50 was 33%. Examination found pharyngeal foreign body sensation in 65% of cases, dysphagia in 67% of cases, headache in 71% of cases and cervical neuralgia. Brachial in 95% of cases. At CT, the average length of all pen processes was 39.2 mm (extremes: 21-76 mm). The elongation of the pen process was bilateral in 68%, unilateral right in 7% of cases, unilateral left in 25% of cases. Morphologically, the PS consisted of a single long fragment

in 78% of cases (Langlais types 1), or two fragments articulated either by fibrous tissue or by a pseudoarticulation with an angular shape in 19% of cases (Langlais types 2), or several fragments (3% Langlais types 3).

Conclusion: Eagle syndrome is a radioanatomical entity with several variants whose knowledge is essential to its management.

Keywords: Styloid process; Eagle; morphometry; CT scan:

Author's Affiliation: ¹Laboratory of Anatomy s/c UMRED UFR of the sciences of health, Iba THIAM University of Thies, Thiès, Senegal, ^{2,8}Department of otorhinolaryngology of the Albert Royert Hospital in Fann-Senegal, ^{3,5,6,9}Department of Radiology and Medical Imaging of Dantec-Senegal, ^{5,6}UFR of Health Sciences, Assane Seck University of Ziguinchor-Senegal, ^{4,7}Laboratory of Anatomy and Organogenesis, Faculty of Medicine, Pharmacy and Odontology UCAD, Dakar, Senegal.

Corresponding Author: Mar Ndeye Bigué, Laboratory of Anatomy s/c UMRED UFR of the sciences of health, Iba THIAM University of Thies, Thiès, Senegal.

E-mail: biguemarmbaye@yahoo.fr

Received on: 21.10.2023

Accepted on: 24.11.2023

INTRODUCTION

Anatomical variations in the styloid process of the temporal bone or ossification of the stylohyoid ligament (LSH) or both, define Eagle Syndrome (SE) according to Dr. Watt Weems Eagle since 1937.^{1,2}

It is characterized by an abnormality in the length of the pen process, the measurement of which is greater than 25 mm, associated with very heterogeneous clinical signs.³⁻⁷

According to the literature, this is a rare, clinically poorly known syndrome that can present a multitude of symptoms affecting the cerebral and cervical regions^{7,8}, which can occur at any age.^{9,10} Its symptomatology is bilateral in most cases.^{10,11}

Surgery has been shown to be effective in its management but the results are influenced by several factors including clinical signs, type and projection area of the pen process. This underlines the importance of the morphology of the pen process and its anatomical relationships in the selection of surgical candidates.¹²

It is in this context that we undertook this work in order to describe the anatomical variants of the pen process that can enter Eagle syndrome and to understand their locoregional complications.

MATERIAL AND METHOD

We selected patients referred for clinical suspicion of Eagle syndrome confirmed by the cervical scanner whose images were analyzed through a Syngo Acquisition Workspace post-processing console in bone window (FO) and small parts (PM) with MPR, MIP, and Volume Rendering (VRT) reconstructions.

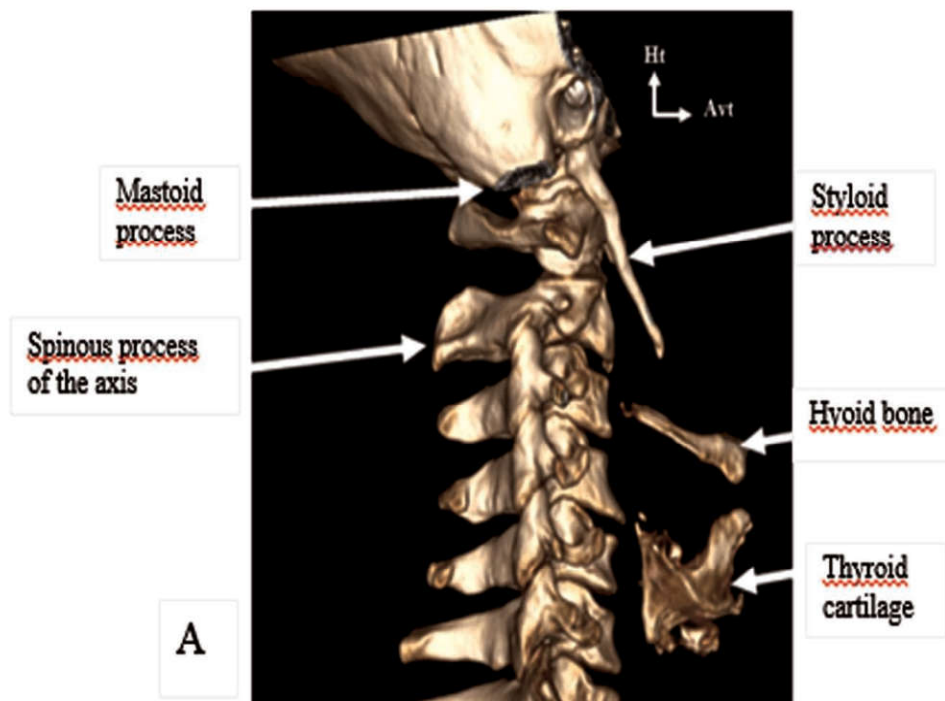
The measurement of the process was carried out from its implantation base at the level of the temporal bone to its tip which constitutes its termination and includes the ossified part of the pen-hyoid ligament. For each patient, age, sex, clinical signs and the cardiovascular complication of the sample were recorded.

RESULTS

These were 32 patients of which 24 women (75%) and 8 men (25%) hence a sex ratio of 0.33.

The average age of patients was 39 years with a median of 37 years, a standard deviation of 12 years and extremes of 21 to 71 years. The age group of [21-29] represented 18% of the population, that of [30-39] was 34%, followed by the group of [40-49] whose percentage was 33 and the age group over 51 years old which were 15%.

The average size of the pen processes was 39.2 mm with extremes of 26 and 76.6 mm example Figure (1)



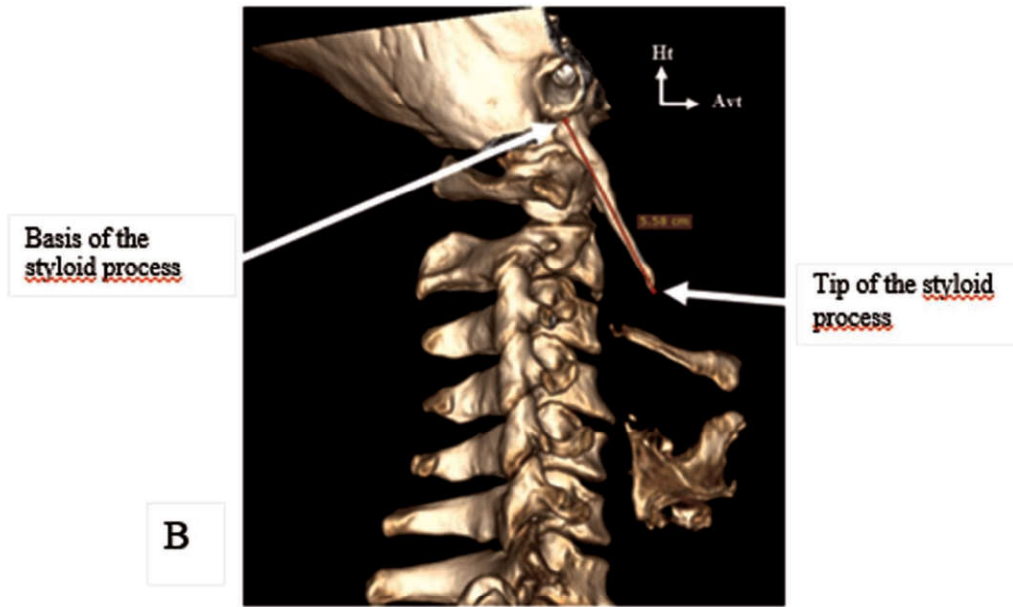


Fig. 1: A; Highlighting of styloid process and surrounding structures, B ; Styloid process measurement method from volume rendering

On the right, the average size was 36 mm with 26 and 71 mm (Figure 2) extremes and on the left, it was 38 with 26 and 76.6 mm extremes.

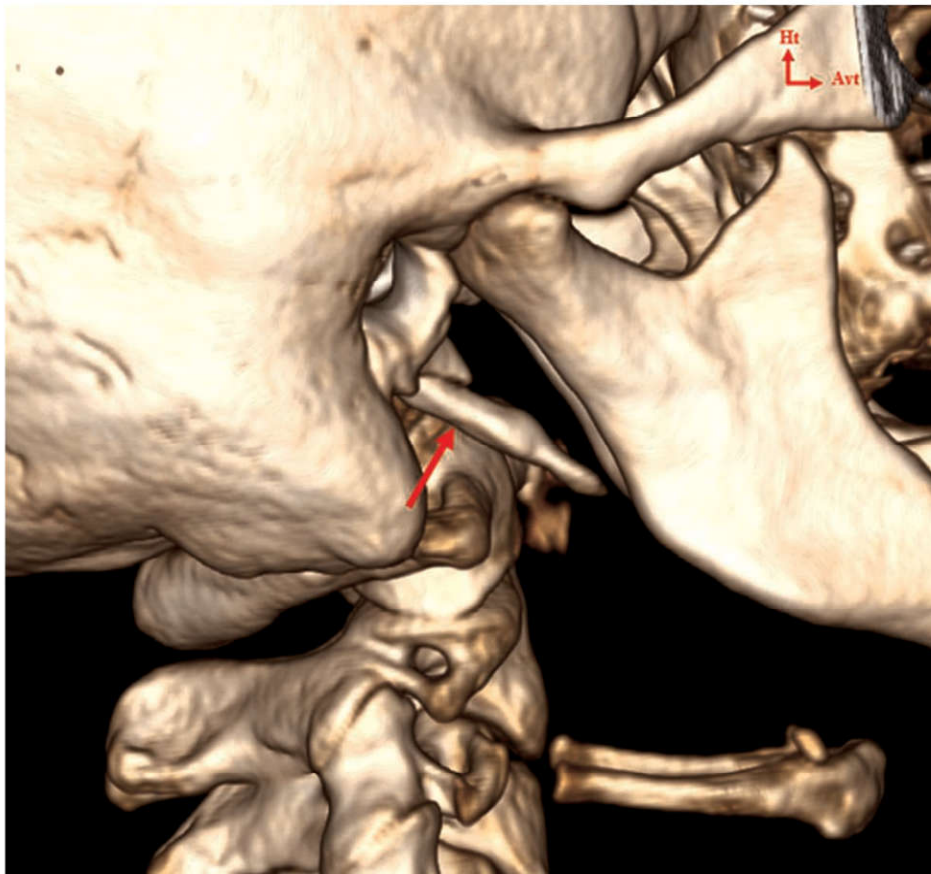


Fig. 2: VRT-mode reconstruction of the abnormally elongated right styloid process (red arrow).

Pen processes between 26 and 35 mm in size accounted for 68%, and 32% represented styloid processes strictly greater than 35 mm.

For one of the patients who received surgery

following repetitive TIA-type complications secondary to compression of the left internal carotid artery, we took the image of the pen process (Figure 3).

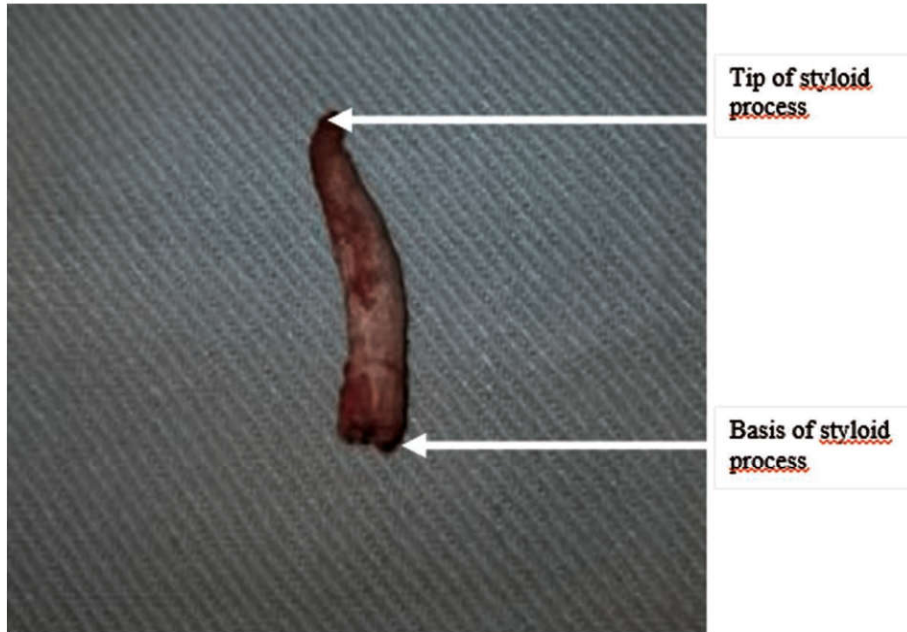


Fig. 3: Photo of a resected styloid process

We found in our population the three types described by Langlais. Morphologically, the PS consisted of a single long fragment in 78% of cases (Langlais types 1), or two fragments articulated

either by fibrous tissue or by a pseudoarticulation with an angular shape in 19% of cases (Langlais types 2; cf Figure 4), or several fragments (3% Langlais Types 3).

Table I below summarizes the distribution of these types by topography with a predominance of bilaterality which was 68% (Figure 5).

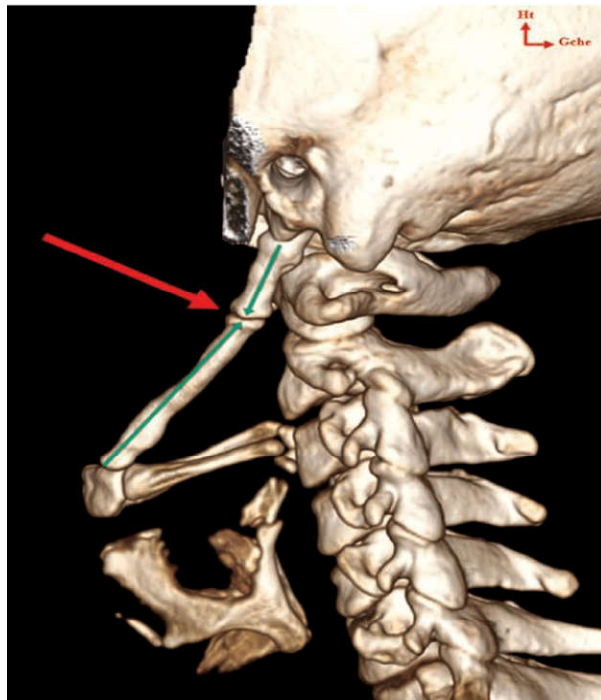


Fig. 4: Reconstruction in VRT mode showing type 2 elongation of the left styloid process (arrow) according to the Langlais classification with the pseudo-articulation (arrow).

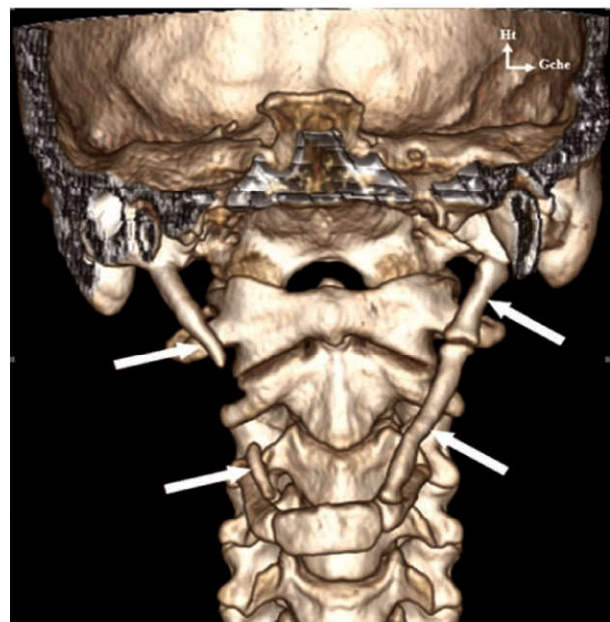


Fig. 5: Reconstruction in VRT mode showing bilateral lengthening of the styloid process (arrows).

LIST OF TABLES AND FIGURES:

Table 1: Distribution of types by topography.

Topography	TYPES			Total	Percentage (%)
	T1	T2	T3		
Left	4	4	0	8	25
Right	2	0	1	3	7
Bilateral	20	1	0	19	68
Total	26	5	1	32	100

Examination revealed a pharyngeal foreign body sensation in 65% of cases, dysphagia in 67% of cases, headache in 71% of cases and cervicobrachial neuralgia in 95% of cases.

DISCUSSION

In our study, the predominance was female with 75% or a sex ratio of 0.33. Our results are superimposed on those found by El Hassanni, Piagkou *et al.*^{3,13} The female sex seems to be a predisposing factor in the occurrence of the abnormally elongated pen process (SE). There is a relationship between the presence of systemic pathology and (ES).¹⁰ Other authors blame hormonal disorders due to menopause.¹⁴

This female predominance was not shared by Keur JJ *et al.*¹⁵ for whom there would be no female or male difference on the occurrence of elongation of the pen process. This may be due to population size. Consideration should also be given to the fact that osteoarthritis occurs at a relatively late age regardless of gender.¹⁶

In our sample, the average age was 39, so it is close to what is described by certain heights.^{3,17,18} Camarda and Al are a little bit ahead of us. They are at 40¹⁷ while Fini *et al.*¹⁰ had found 37. This observation of the average around the wall age could be explained by the fact that the ossification of the pen process is a continuous phenomenon throughout life and starts late. During youth, pen process is absent or is very short.¹⁹ The study of Al-Khateeb *et al.*¹³ was in phase with ours. This was the case with the results of Camarda *et al.*²¹

Our work contradicted those of Eagle²⁰ that criminalize surgery, or trauma to the cervical region, in the occurrence of elongation of the pen process. This is confirmed by the work of Fini *et al.* who concluded that there is a strong correlation between a history of tonsillectomy and/or trauma with the occurrence of Eagle syndrome.¹⁸ However, no association could be made between the clinic and the degree of elongation of the pen process.²¹

The 3D reconstruction scanner (3 Dimensions)

allowed the exact measurement of the pen process and the knowledge of the surrounding structures.²² It remains a good anatomical study tool *in vivo*.

In our study the bilaterality of the abnormally elongated pen process was found in 68% of cases. This is superimposed on the results of the literature^{10,11} which showed a bilaterality around 85% of cases. Harma *et al.*²³ found 48%.

When the elongation of the pen process is unilateral (32% of cases), we find a 25% left predominance in contrast to Jung T and all.²⁴ who found no difference in distribution between right and left. This could be explained by the size of their sample which was 1000 patients.

In our study a pen process was considered pathological, that is to say abnormally elongated when it was greater than 25 mm like some authors.¹⁴

Ceylan²⁵ agrees with us that a normal pen process should be less than 25 mm. Other authors set a threshold greater than 30 mm.^{11,15,21,26,27}

According to Monsour and Young²⁸, SP is considered an elongated variant when its length exceeds 40 mm, as well as for Savranlar *et al.*²⁹

It should be noted that the majority of elongated pen processes (ESP) are between 30 and 40 mm (54%) on both the right and left sides. The ossification of the pen process is a continuous phenomenon throughout life, and especially very variable: the length of the pen process varies considerably from one individual to another. The underlying phenomenon is unclear but would influence length variability.^{12,31}

In our study, type 1 predominated with 78% followed by type 2 with 19% and finally type 3 with 4%. Our results are superimposed on those of EL Hassani and Gossman *et al.*^{3,32} who found a majority of pen processes that were elongated without interruption of their integrity (type 1) in 78% of cases. But unlike them, Type 3 was the least represented with 4% versus 27% among them. Type 2 is not found in their study but only in our case, it was not negligible (19% of cases). In addition, we

noted that there was a type match in our series when a stretching of the pen process is bilateral (78%). It is indeed quite rare to find two different types in the same patient. We did not find studies on the correspondence of types in the literature.

Many vascular complications such as ACI dissection have been described in the literature.^{4, 33-37} The same was true of one of our cases with repeated transient ischemic stroke on an anatomical variant of the pen process. This justifies the interest to study the relations of the pen process with the particularly vascular neighbourhood structures.

CONCLUSION

Eagle syndrome is a radioanatomical entity with several variants whose knowledge is essential to its management and understanding of its complications, especially since it was classified in 1988 as "not sufficiently demonstrated", by the International Headache Society.

REFERENCES

1. *Eagle WW*. Elongated styloid process, report of 2 cases. *Arch Otolaryngol*. 1937;25:584-587.
2. *Balde D, Do Santos ZA, Ndiaye C, Dione A, Diallo B K, Adjibabi W, Yehouessi VB*. Intra oral versus external approach in the surgical management of Eagle's syndrome. *International Journal of Otorhinolaryngology*. 2019; 5(1):9-14.
3. *El hassane* apport de la tomodensitometrie dans le diagnostic du syndrome d'eagle au centre hospitalier regional heinrich lübke de diourbel : à propos de 30 cas [Mémoire de spécialité]. *Université Cheikh Anta Diop de Dakar année 2019 N°313 ; 39p*
4. *Lengele B. et Dhem A*. Microradiographic and histological study of the styloid process of the temporal bone. *Acta Anat*. 1989;135(3):193-199.
5. *Raser J.M, Mullen M.T, Kasner S.E et al*. Cervical carotid artery dissection is associated with styloid process length. *Neurology*. 2011;77(23):2061-2066.
6. *Aydil U, Kizil Y et Koybasioglu A*. Less known non-infectious and neuromusculoskeletal system-originated anterolateral neck and craniofacial pain disorders. *Eur Arch Otorhinolaryngol*. 2011; 269(1):9-16.
7. *Rodriguez-Vasquez JF, Mérida-Velasco JR, Verdugo et al*. Morphogenesis of the second pharyngeal arch cartilage (Reichert's cartilage) in human embryos. *J Anat*. 2006;208(2):179-189.
8. *Camarda AJ, Deschamps C et Forest D*. Stylohyoid chain ossification: a discussion of etiology. *Oral Surg Oral Med Oral Pathol*. 1989;67:508-514.
9. *Kaufman SM, Elzay RP, Irish EF*. Styloid process variation: Radiologic and clinical study. *Arch Otolaryngol*. 1970; 91:460-463.
10. *Khandelwal S, Hada YS et Harsh A*. Eagle's syndrome - A case report and review of the literature. *Saudi Dent J*. 2011 ;23(4) :211-215.
11. *Al-Khateeb TH, Al-Dajani, Al-Jamal GA*. Mineralization of the stylohyoid ligament complex in a Jordanian sample: a clinicoradiographic study. *J Oral Maxillofac Surg*. 2010; 68:1242-1251.
12. *Oztas B et Orhan K*. Investigation of the incidence of stylohyoid ligament calcifications with panoramic radiographs. *J Investig Clin Dent*. 2011;3(1): 30-35.
13. *Correl R, Jensen J, Taylor J, et al*. Mineralization of the stylohyoid-stylomandibular ligament complex: A radiographic incidence study. *Oral Surg Oral Med Oral Pathol*. 1979;48:286-291.
14. *Gokce C, Sisman Y et Sipahioğlu M*. Styloid process elongation or Eagle's syndrome: is there any role for ectopic calcification? *Eur J Dent*. 2008;2(3):224-228.
15. *Piagkou M, Anagnostopoulou S, Kouladouros K et al*. Eagle's syndrome: a review of the literature. *Clin Anat*. 2009;22(5):545-558.
16. *Watanabe PC, Issa JP et al*. Elongated styloid process atheroma in panoramic radiography and its relationship with system osteoporosis and osteopenia. *Osteoporosis Int*. 2010;21(5):831-836.
17. *Keur JJ, Campbell JP, McCarthy JF, et al*. The clinical significance of the elongated styloid process. *Oral Surg Oral Medicine Oral Pathol*. 1986; 61:399-404.
18. *Headache Classification Committee of the International Headache Society*. Classification and diagnostic criteria for headache disorders, cranial neuralgias and facial pain. *Cephalgia*. 8: Suppl. 7 : 1-96, 1988.
19. *Fini G, Gasparini G, Filippini F et coll*. The long styloid process syndrome or Eagle's syndrome. *J Craniomaxillofac Surg*. 2000;28(2):123-127.
20. *Krmpotic Nemanic J, Vinter I, Ehrenfreund T et al*. Postnatal changes in the styloid process, vagina processus styloide, and stylomastoid foramen in relation to the function of muscles originating from the styloid process. *Surg Radiol Anat*. 2009;31(5):343-348.
21. *Eagle WW*. Symptomatic elongated styloid process. *Arch Otolaryngol*. 1949;49:490-503.D
22. *Balbuena L, Hayes D, Ramirez SG, Johnson R*. Eagle's syndrome (elongated styloid process). *South Med J*. 1997;90:331-334.
23. *Savranlar A, Uzun L, Uayur MB et al*. Three-dimensional CT of Eagle's syndrome. *Diagn Interv Radiol*. 2005;11(4):206-209.
24. *Vaidhyanath R. et Kenninham R*. Elongated styloid process or Eagle's syndrome. *British J Hosp Med*. 2008; 69:6.
25. *Bafaqeeh SR*. Eagle syndrome : classic and carotid artery types. *J Otolaryngol*. 2000;29:88-94.

26. **Mendelsohn AH, Berke GS et Chhetri DK.** Heterogeneity in the clinical presentation of Eagle's syndrome. *Otolaryngol Head Neck Surg.* 2006;134(3):389-393.
27. **Härmä R.** Stylalgia: Clinical Experiences of 52 Cases. *Acta Oto-Laryngologica.* 1967; 63:149-155.
28. **Jung T, Tschernitschek H, Hippen H et al.** *Dentomaxillofacial Radiology.* 2004; 33:119-124.
29. **Ceylan A, Koybasioglu A, Celenk et al.** Surgical treatment of elongated styloid process: experience of 61 cases. *Skull Base.* 2008; 18(5):289-295.
30. **Gokce C, Sisman Y et Sipahioglu M.** Styloid process elongation or Eagle's syndrome: is there any role for ectopic calcification? *Eur J Dent.* 2008;2(3):224-228.
31. **Ilguy M, Ilguy D, Guler N et coll.** Incidence of the type and calcification patterns in patients with elongated styloid process. *J Int Med Res.* 2005;33(1):96-102.
32. **Monsour P, Young WJ.** Variability of the styloid process and stylohyoid ligament in panoramic radiographs. *Arch Otolaryngol.* 1986; 61:522±526.
33. **Gossman JR Jr, Tarsitano JJ.** The stylo-stylohyoid syndrome. *J Oral Surg.* 1977; 35:555-560.
34. **Ohara N, Sakaguchi M, Okazaki S et al.** Internal carotid artery dissection caused by an elongated styloid process: usefulness of transoral ultrasonography. *J. Stroke Cerebrovasc.* 2012; 21(8):918e7-918e8.
35. **Renard D, Azakri S, Arquizan et al.** Styloid and hyoid bone proximity is a risk factor for cervical carotid artery dissection. *Stroke.* 2013;44(9):2475-2479.
36. **Todo T, Alexander M, Stokol C et al.** Eagle syndrome revisited: cerebrovascular complications. *Ann Vasc Surg.* 2012;26(5):729e1-729e5.

