

Prevalence of Thyroidea Ima Artery & Variations in Aortic Arch Branches in South Asian Population: A Retrospective CT-Based Study

Gopinath Periaswamy¹, Navya Christopher², Venkatesh Kasi Arunachalam³,
Sugumar Raghul⁴, Dhanyasree T R⁵, Kartheek Guthikonda⁶, Rajesh Kumar
Varatharajaperumal⁷, Mathew Cherian. P.⁸

How to cite this article:

Gopinath Periaswamy, Navya Christopher, Venkatesh Kasi Arunachalam, *et al.*/Prevalence of Thyroidea Ima Artery & Variations in Aortic Arch Branches in South Asian Population: A Retrospective CT-Based Study/Indian J Anat. 2023;12(1):9-19.

Abstract

Objectives: The aim of this study is to determine the prevalence of thyroidea ima artery (TIA) and branching pattern variations of aortic arch among 2000 patients who underwent CECT imaging.

Materials and methods: This retrospective cross-sectional observational study included 2000 patients who underwent CECT of aortic arch and branches during a two-year period in a tertiary care centre in South India. The presence of thyroidea ima artery with its origin were identified and the branching patterns of aortic arch were assessed.

Results: TIA was identified in 23 patients, showing a prevalence of 1.15%. The normal branching pattern of aortic arch was observed in 1493 patients, and variations in branching pattern were seen in 507 patients. The variations included 342 cases of bovine-type arch, 162 left vertebral arteries originating from arch, 16 aberrant right subclavian artery, 10 right-sided aortic arch, and 1 double aortic arch.

Conclusion: The identification of TIA and variations in aortic arch branching are crucial, as they can cause complications during neck and thoracic surgeries and endovascular interventions. CECT is a reliable tool to assess the vascular anatomy. Considering the prevalence demonstrated in our study, imaging should be included prior to procedures in order to prevent complications.

Keywords: Thyroidea ima artery; Right aortic arch; Double Aortic arch; Bovine type arch.

Author's Affiliation: ¹⁻⁶Resident, ⁷Consultant Radiologist, ⁸Head of the Department, Department of Radiology, KMCH, Avanashi Road, Coimbatore-641014, India.

Corresponding Author: Venkatesh Kasi Arunachalam, Resident, Department of Radiology, KMCH, Avanashi Road, Coimbatore-641014, India.

E-mail: drkasivenkatesh@yahoo.co.in

Received on: 03.09.2023

Accepted on: 10.10.2023

INTRODUCTION

The thyroidea ima artery (TIA) is an uncommon variant artery supplying the inferior aspect of the thyroid gland, seen ascending on the anterior surface of the trachea. It was first described by Neubauer (1772), and has been shown to have a prevalence ranging from 1% to 15% across studies.¹

TIA can vary in its origin, arising from the arch of aorta (AA), brachiocephalic trunk (BCT), common

carotid artery (CCA), subclavian artery (SCA), vertebral artery (VA) or internal thoracic artery.² It is often associated with absent inferior thyroid arteries. Because of its critical anatomic position in the superior mediastinum or lower neck, knowledge of the existence of the TIA is of vital importance to avoid accidental hemorrhage during neck and thorax surgeries, including thyroidectomy and tracheostomy.

Apart from thyroidea ima artery, the arch of aorta can have various anatomical variations in its branching pattern, that includes the variation in the number of branches and in the origins of different branches from the arch.

In foetal life, the aortic development takes place during the 3rd week of gestation.³ It is a complex process, alteration of which can lead to a variety of congenital variants and pathologic anomalies. Each primitive aorta consists of a ventral and a dorsal segment. The two ventral aortae fuse to form the aortic sac, and the two dorsal aortae fuse to form the descending aorta, and the left 4th arch vessel becomes the aortic arch.

In the classical anatomical configuration, the aortic arch is left sided and the most common branching pattern of the AA comprises of three great vessels; from right to left- the brachiocephalic trunk which further branches into right subclavian artery and right common carotid artery, the left common carotid artery, and the left subclavian artery. This branching pattern occurs in 64.9–94.3% of the cases and it is described as “normal”.^{4,6} The variations from the normal anatomy of AA occur due to persistence of segments of the aortic arches that normally regress or disappearance of segments that normally remain, or both.

Many of the aortic arch variations are associated with cardiovascular anomalies or gastroesophageal symptoms (rings and slings) and thus tend to be discovered early in life.^{7,8} Many others however are either isolated or asymptomatic. These can be found incidentally on plain film imaging or on cross-sectional studies.^{9,10} An unsuspected arch anomaly may first come to light during an endovascular procedure also. Hence, the knowledge of the branching pattern variations of aortic arch is significant for various diagnostic, surgical, and interventional procedures of the thorax and neck.

Though there are studies available on the prevalence of thyroidea ima artery and on the variations of aortic arch and its branching pattern in cadavers, only a few studies are available among living patient population that are based on CT and from the Indian subcontinent. The purpose of this

study is to determine the prevalence of thyroid ima artery (TIA) and the branching pattern variations of aortic arch among 2000 patients who underwent contrast enhanced CT imaging. To the best of the authors' knowledge, this is the largest contrast CT based study till date regarding the prevalence of thyroidea ima artery, and one of the largest contrast CT based studies regarding the prevalence of variant branching anatomy of aortic arch, in a living patient population.

MATERIALS AND METHODS

This was a retrospective observational study conducted in a tertiary care centre in South India. The study included 2000 patients who underwent contrast enhanced CT of aortic arch and branches, which included CT pulmonary angiogram, CT aortogram, CECT thorax, CECT neck and CT cerebral angiography, for various indications during the period of January 2020 to January 2022. All consecutive patients were included irrespective of the indications. The data was accessed through the hospital health information system (HIS) and picture archiving and communication system (PACS).

Imaging analysis

CT scans were performed using a multidetector dual energy CT scanner (Somatom Force, Siemens Healthineers, Erlangen, Germany). Images from PACS were transferred to the workstation (Syngo. via, Siemens), and source axial, multiplanar reconstructed images and postprocessed (maximum intensity projection and 3D volume rendered) images were evaluated. The image analysis was performed by a senior radiologist with 15 years of experience in cross sectional imaging and angiography.

The origin of thyroidea ima artery, and the number of branches of aortic arch were identified and the branching patterns were analyzed. The scans in which clear identification of the arch anatomy was not possible due to poor image quality (eg. motion artefacts), or cases with prior arch reconstructive surgery were excluded from the study.

Statistical analysis

Anatomical variants were identified and expressed in terms of the prevalence of each variant. Chi-square test for trend analysis was performed for gender with a 95% confidence interval. A p-value of less than 0.05 was considered significant. Data

analysis was carried out using commercially available software (Statistical package for social sciences, SPSS Inc., Chicago, Illinois, US).

RESULTS

The study included 2000 patients who underwent CECT covering aortic arch during the study period, which included 65.2% (n= 1304) males and 34.8% (n= 696) females. Age of the subjects ranged from 1 to 98 years, with mean age of 53.7 years. Normal vascular anatomy with normal branching pattern of aortic arch was observed in 74.6% (n= 1493) patients.

The thyroidea ima artery was identified in only 23 patients, thus showing a prevalence of 1.15%. Among the 23 patients, 11 cases (47.8%)

showed origin of thyroidea ima artery from the brachiocephalic trunk, 5 (21.7%) from the right subclavian artery, 2 (8.7%) from the right common carotid artery, 2 (8.7%) from the right vertebral artery, 2 (8.7%) from the left common carotid artery and 1 (4.4%) from the aortic arch.

Five types of variations of aortic arch branching pattern were observed in the study. The variations were identified in 507 patients, making the prevalence of variations 25.3%. (Figure 1) Among them, 24 patients showed two variations each, thus accounting to a total of 531 instances of variations. Out of the total variations observed, 65.9% (n= 334) cases involved males and 34.1% (n= 173) were females. (Table 1) Chi-square test for trend analysis for correlation of variation with gender was not significant (p=0.710).

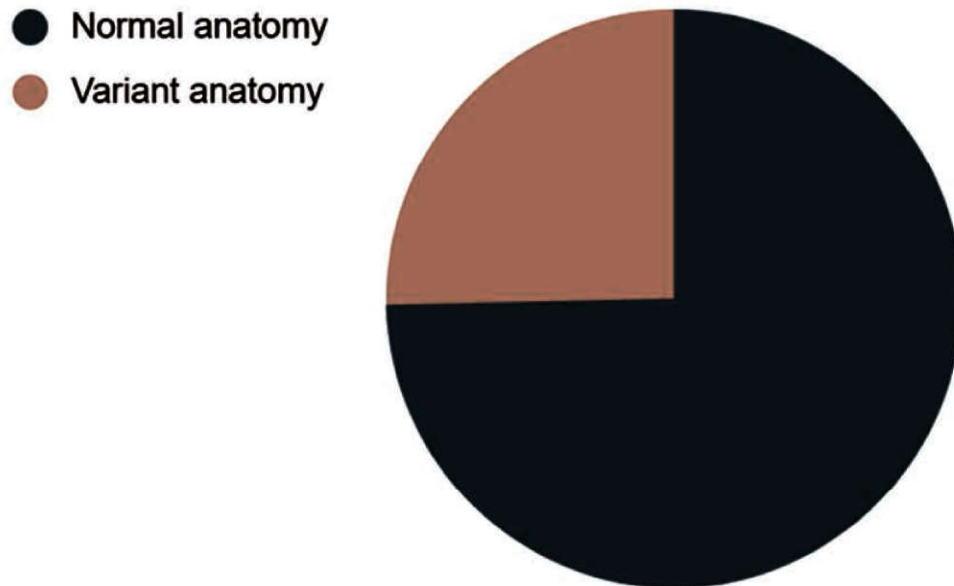


Fig. 1: Distribution of branching pattern of aortic arch

Table 1: Gender distribution of branching pattern of aortic arch

Aortic arch branching pattern	Total population	Males	Females
Normal	1493	970	523
Variant anatomy	507	334	173

The five types of variations of aortic arch branching included 342 cases (17.1 %) of bovine arch (217 males, 125 females), 162 cases (8.1 %) of the origin of left vertebral artery from arch (119 males, 43 females), 16 cases (0.8 %) of aberrant

right subclavian artery (10 males, 6 females), 10 cases (0.5%) of right-sided aortic arch (6 males, 4 females), and 1 case (0.05 %) of double aortic arch (1 female) (Figure 2).

The variations are summarised in Table 2.

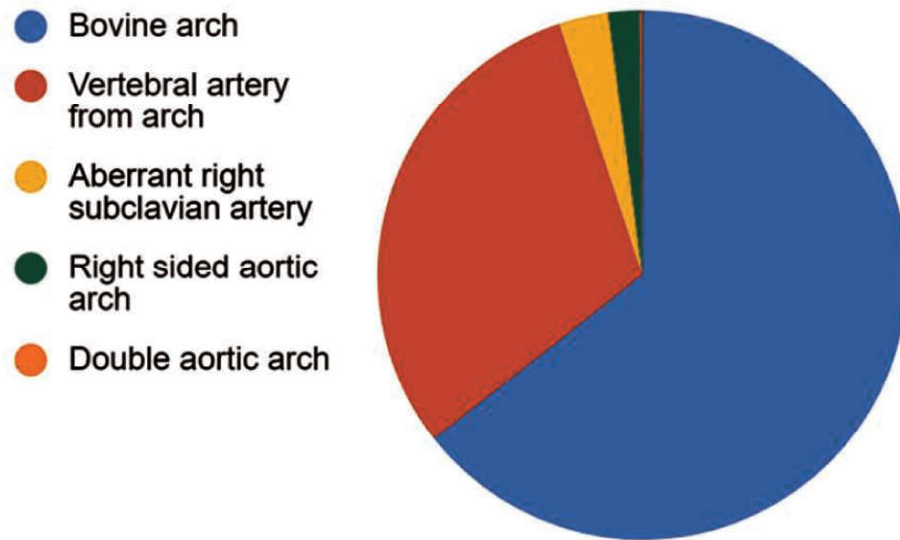


Fig. 2: Distribution of types of variant branching pattern of aortic arch

Table 2: Distribution of types of variant branching pattern of aortic arch

Aortic arch branching pattern variations	Number of variants (n)	Prevalence in total population (%)	Prevalence in variant population (%)	Males	Females
Bovine arch	342	17.1%	67.4%	217	125
Vertebral artery from arch	162	8.1%	31.9%	119	43
Aberrant right subclavian artery	16	0.8%	3.1%	10	6
Right sided aortic arch	10	0.5%	1.9%	6	4
Double aortic arch	1	0.05%	0.2%	0	1

DISCUSSION

This was a retrospective observational study conducted at a tertiary care centre in South India over a period of two years. To the best of the authors' knowledge, this is the largest contrast CT based study till date regarding the prevalence of thyroidea ima artery, and one of the largest contrast CT based studies regarding the prevalence of variant branching anatomy of aortic arch, in a living patient population.

The prevalence of thyroidea ima artery in our study was 1.15%, which corresponds to the range of prevalence as described across studies, ranging from 1% to 15%.¹

Thyroidea ima artery

TIA was first described by Neubauer (1772), and it

has been described using several synonyms such as thyroidea ima artery, arteria thyroidea ima, artery of Neubauer, and the lowest thyroidea ima artery. TIA can have a variable origin, from the arch of aorta, brachiocephalic trunk, common carotid artery, subclavian artery, vertebral artery or internal thoracic artery.¹

A total of 23 cases of thyroidea ima artery [Figure 3] were observed in this study, which included 13 males and 10 females. Out of the 23 cases, 11 were seen originating from the BCT, 5 from the right SCA, 2 from right CCA, 2 from right VA, 2 from left CCA, and 1 from the AA. [Table 3] These findings indicated the origin of the TIA was from the right sided arteries in 86.9%, left sided arteries in 8.7%, and from the AA in 4.4% patients.

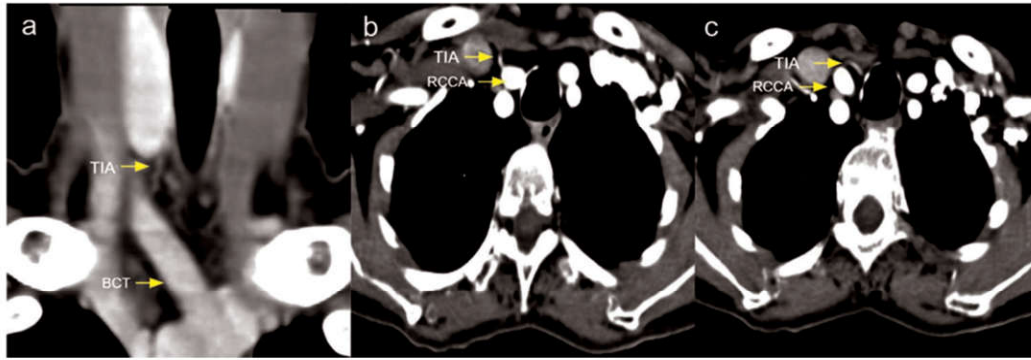


Fig. 3: Coronal CT neck contrast image (1a) showing thyroidea ima artery arising from the brachiocephalic trunk.

Axial CT contrast images (1b, 1c) showing thyroidea ima artery arising from the right common carotid artery.

TIA: Thyroidea Ima Artery, BCT: Brachiocephalic Trunk, RCCA: Right Common Carotid Artery

Table 3: Sites of origin of thyroidea ima artery

Site of origin of thyroidea ima artery	n	Prevalence (%)
Brachiocephalic trunk	11	47.8%
Right subclavian artery	5	21.7%
Right CCA	2	8.7%
Right vertebral artery	2	8.7%
Left CCA	2	8.7%
Aortic arch	1	4.4%

These findings were similar to the inferences of Esen and colleagues¹¹, from a CT angiography study conducted in 640 patients, who found 15 patients to have TIA (2.3% of cases), of which most originated from the BCT. In another study of dissection on 94 cadavers, Chin et al.¹² also found only one case to have a thyroid ima artery present, suggesting a prevalence of 1.06%.

Yurasakpong et al.¹ in their meta-analysis found a decreasing prevalence of TIA in adults than in fetuses, with roughly four times more prevalence in fetuses, suggesting a possible regression of TIA during postnatal period. They hypothesized that the TIA could be a normal structure during development, and its persistence beyond the fetal stage would result in TIA becoming an anatomical variant.

TIA is small in size, ranging from 3–5 mm in diameter, and it ascends in front of the trachea reaching the inferior part of the thyroid gland. In addition to supplying the thyroid gland, it can also perfuse the trachea and the parathyroid glands. Due to its small size and because of its rare presence, TIA can pose a risk of accidental hemorrhage during surgical operations including tracheostomy. Hence,

surgeons should be aware of the presence of TIA when performing surgical airway management.^{13,14}

AORTIC ARCH VARIATIONS:

The normal three-branch pattern of aortic arch is found with an incidence of 64.9–94.3% as per the literature.^{4–6} In the present study, the normal three-branch pattern of aortic arch was observed in 74.6% of the cases; and in 25.3% cases, variations from usual branching pattern were noted.

Variations in the branching pattern of aortic arch:

Bovine arch:

The most common variant branching pattern of arch is referred to as bovine-type arch [Figure 4], which occurs when the left CCA has a common origin with, or, less commonly, arises directly from the brachiocephalic trunk.¹⁵ However, it is a misnomer as it does not resemble the aortic arch pattern seen in cattle, which has only a single trunk from aortic arch that further divides into right subclavian artery, a common trunk for common carotid arteries and left subclavian artery.¹⁶

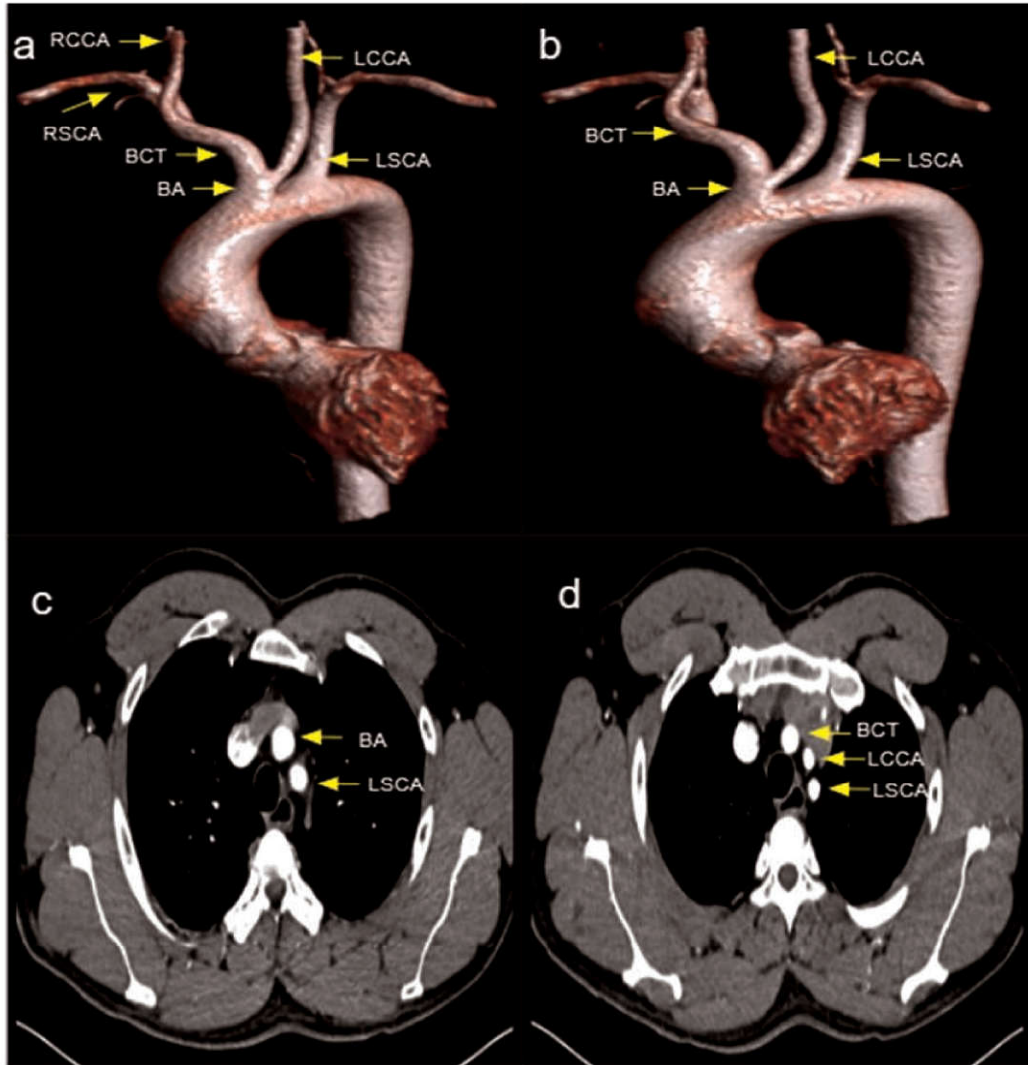


Fig. 4: Axial CT chest contrast and VRT images showing bovine-type arch.

BA: Bovine-type arch, **BCT:** Brachiocephalic Trunk, **RSCA:** Right Subclavian Artery, **RCCA:** Right Common Carotid Artery, **LCCA:** Left Common Carotid Artery, **LSCA:** Left Subclavian Artery

The prevalence of bovine arch in this study was 17.1%. This corresponds to the range of prevalence as described by Baadh et al. ranging from 8% to 25% in different ethnic groups.¹⁷

The exact embryological events underlying the development of this variant remain incompletely understood. Normally, the proximal part of left third aortic arch gets absorbed into the left horn of aortic sac. Instead, if it gets absorbed into the right horn of aortic sac, it shows a branching variation of bovine-type.¹⁸

The bovine arch could be associated with technical failure and neurological complications in carotid stenting procedures. And in case of blunt

chest trauma, bovine arch is found to show an increased likelihood of transection of BCT at its take-off from the aorta.¹⁹

Left vertebral artery from arch:

Another relatively common variant of aortic arch is the origin of the left vertebral artery directly from the aortic arch [Figure 5], with a reported prevalence between 2.4 and 8% [20]. Our study also shows a similar prevalence of 8.1%. The most common location of origin of vertebral artery from arch is between the left CCA and left SCA. Occasionally, the left vertebral artery is also seen as the last branch of AA.

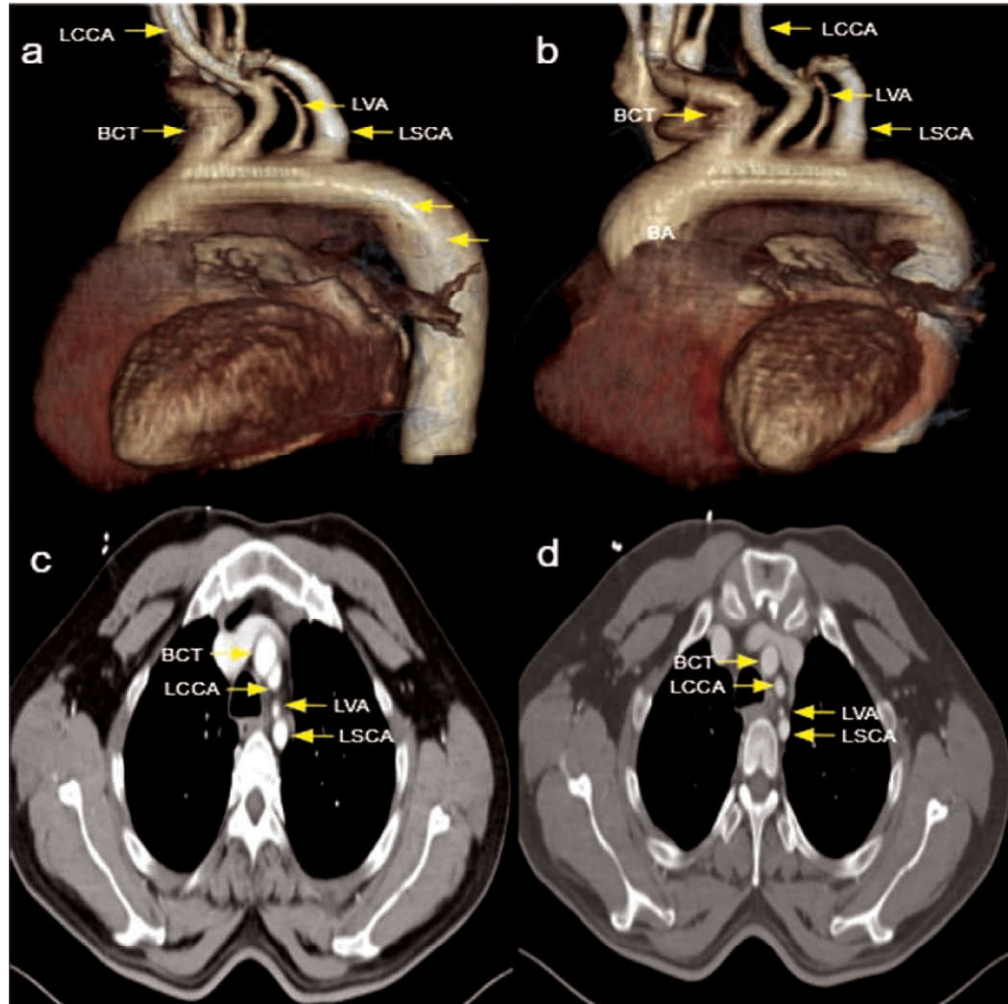


Fig. 5: Axial CT chest contrast and VRT images showing the origin of left vertebral artery from aortic arch.

BCT: Brachiocephalic Trunk, **LCCA:** Left Common Carotid Artery, **LVA:** Left Vertebral Artery, **LSCA:** Left Subclavian Artery

Embryologically, the origin of the vertebral artery from arch is explained to be due to the persistence of development of sixth cervical intersegmental artery and failure of dorsal aortic segment to disappear.²¹

The variations in the origin of the vertebral artery may lead to altered hemodynamics, predisposing to formation of intracranial aneurysms.²² Hence, a thorough search for coexisting aneurysms should

be done in patients with these anomalies.

Aberrant right subclavian artery:

The right subclavian artery may have an aberrant origin as the last branch of AA seen distal to the left subclavian artery [Figure 6], with a prevalence of 0.5%–2% as found in the study by Türkvtan et al.²³ In our study also, a prevalence of 0.8% was noted.

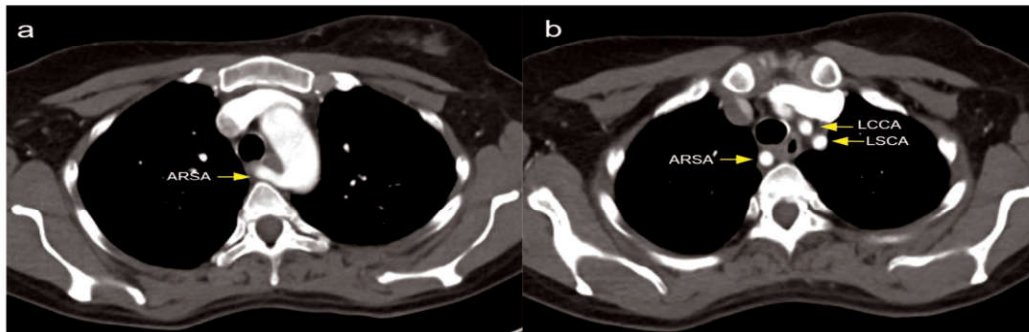


Fig. 6: Axial CT chest contrast images showing aberrant right subclavian artery.

ARSA: Aberrant Right Subclavian Artery, **LCCA:** Left Common Carotid Artery, **LSCA:** Left Subclavian Artery

Aberrant right subclavian artery (ARSA) is formed by the distal portion of the right dorsal aorta (rather than right fourth arch) and right seventh intersegmental artery. As its stem derives from the right dorsal aorta, ARSA has to cross the midline in order to reach the right arm. Thus, it takes a retro-tracheal or retro-oesophageal course, or very rarely, passes anterior to the trachea.²⁴

ARSA is usually asymptomatic, but can cause extrinsic compression of esophagus in about 10% of adults, termed as dysphagia lusoria. It has also been reported to show an association with trisomy 21.²⁵

VARIATIONS IN THE SIDEDNESS OF AORTIC ARCH

Right sided aortic arch

Right-sided aortic arch is a type of AA variant, characterised by AA coursing to the right of trachea, observed in about 0.1% of the adult population.²⁵ Right AA results when there is disappearance of left fourth arch which normally persists, and persistence of right arch which usually disappears. Right AA with an aberrant left subclavian artery (ALSA) is the more common type [Figure 7], which is rarely associated with congenital heart disease; and right AA with mirror-image type branching [Figure 8] is almost always associated with congenital heart disease, especially the cyanotic type.²⁶

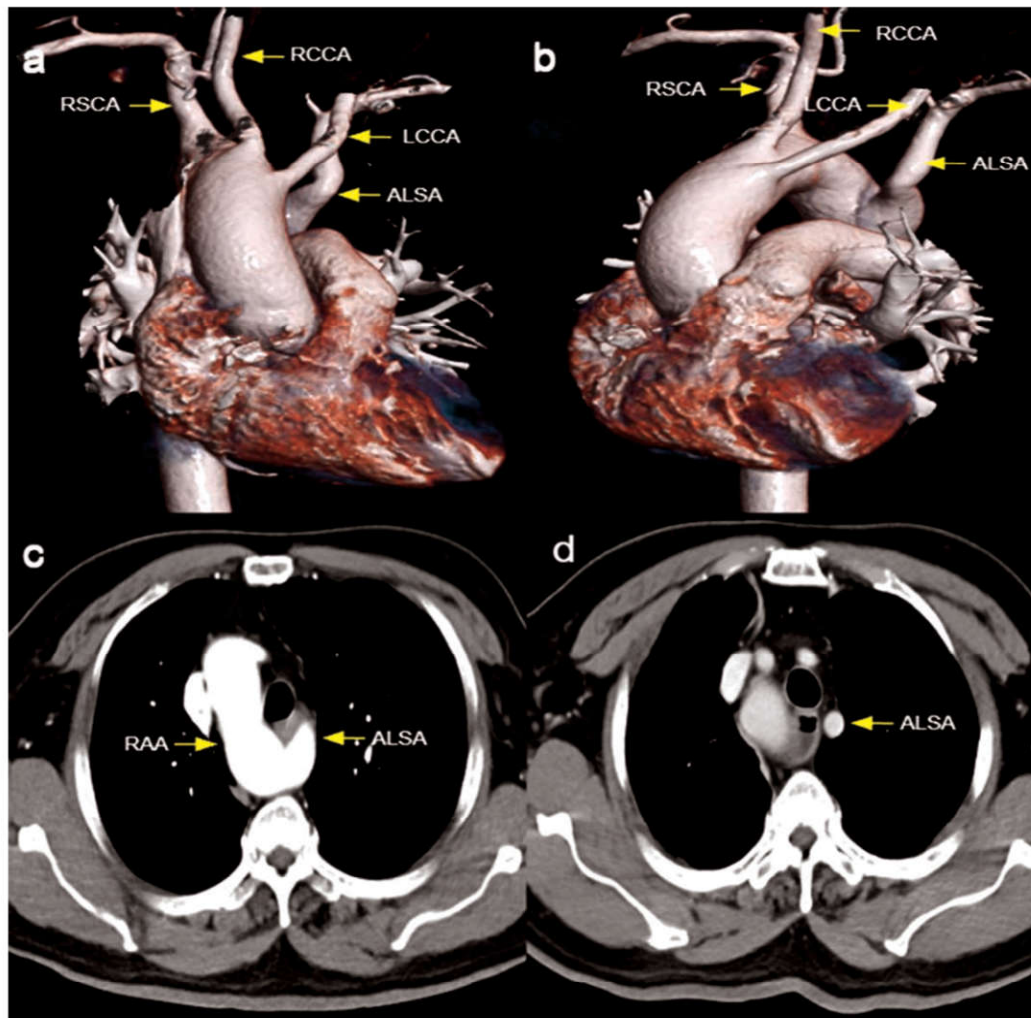


Fig. 7: Axial CT chest contrast and VRT images showing right sided aortic arch with aberrant left subclavian artery.

RAA: Right-sided Aortic Arch, **RSCA:** Right Subclavian Artery, **RCCA:** Right Common Carotid Artery, **LCCA:** Left Common Carotid Artery, **ALSA:** Aberrant Left Subclavian Artery

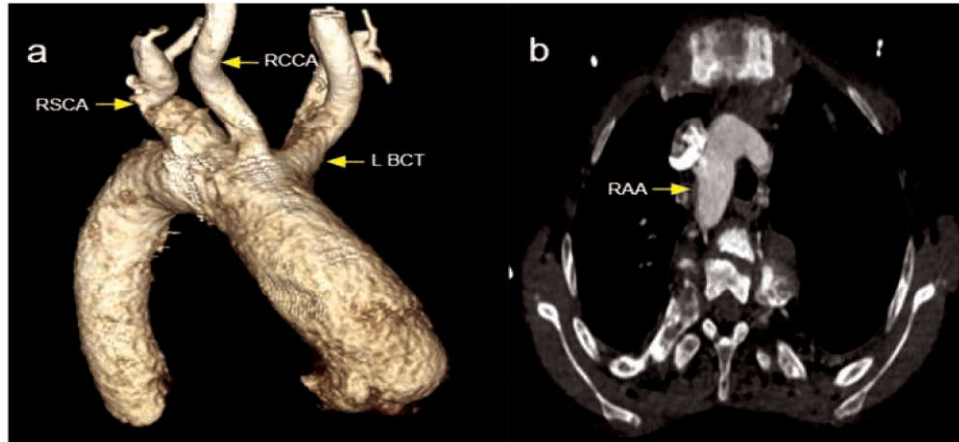


Fig. 8: Axial CT chest contrast and VRT images showing right sided aortic arch with mirror image type branching. Incidental medullary hematopoiesis is also noted at the sternum, vertebra and ribs.

RAA: Right-sided Aortic Arch, **RSCA:** Right Subclavian Artery, **RCCA:** Right Common Carotid Artery, **LBCT:** Left Brachiocephalic Trunk

In the current study, a total of 10 cases of right-sided AA were observed, thus showing a prevalence of 0.5%, of which 4 cases showed right AA with ALSA, 5 cases showed right AA with mirror-image type branching; and 1 case showed absent brachiocephalic trunk with left CCA and SCA reformed through prominent intercostal collaterals. Multiple congenital cardiac anomalies like VSD, ASD, dTGA, pulmonary atresia/ narrowing were associated in the cases with right AA with mirror image branching in this study.

RAA with ALSA is the commonest arch anomaly giving rise to Kommerell's diverticulum, that can present with respiratory symptoms owing to tracheal compression.²⁷ In the present study,

Kommerell's diverticulum was observed in two cases.

Double aortic arch

The double aortic arch is a rare type of aortic arch anomaly [Figure 9]. Though its true prevalence is unknown, a study by Guo Q et al. showed a prevalence of about 0.005% to 0.007% in fetuses.²⁸ Double AA is caused by persistence of the fetal double aortic system, where two aortic arches form a vascular ring that can compress the trachea or oesophagus.²⁹ Most commonly, one arch is dominant. The right dominant arch is seen in approximately 70-80%, codominant arch in 5%, and left dominant arch in 25%.³⁰

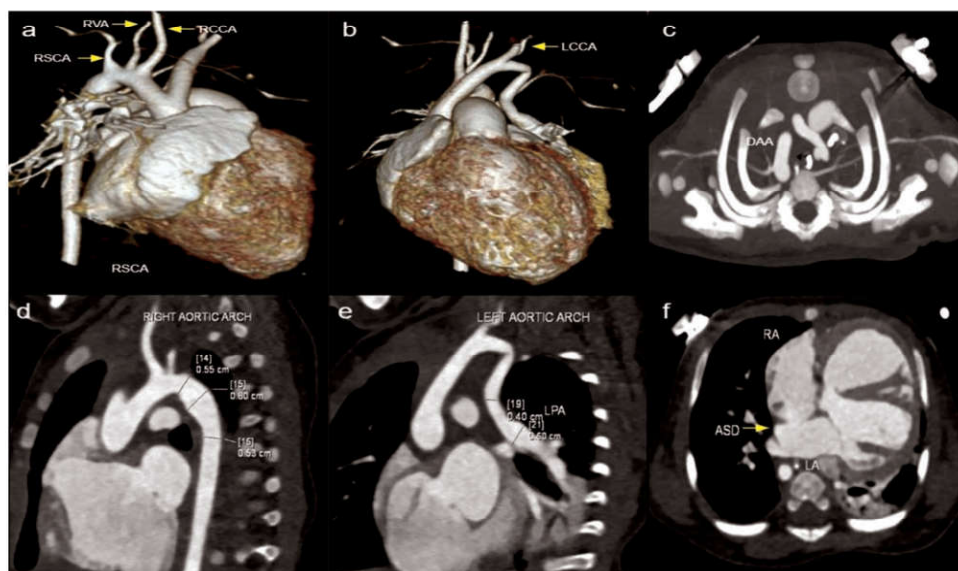


Fig. 9: CT chest contrast and VRT images showing double aortic arch with RSCA, RCCA and RVA arising from the right arch continuing as descending aorta, and LCCA arising from the left arch. Note is also made of ASD (Atrial septal defect).

DAA: Double Aortic Arch, **RSCA:** Right Subclavian Artery, **RCCA:** Right Common Carotid Artery, **RVA:** Right Vertebral Artery, **LCCA:** Left Common Carotid Artery

In the current study, one case of double AA was observed, hence with a prevalence of 0.05%. This case showed a dominant right arch and atretic left arch. Right SCA, right CCA and right vertebral artery were seen arising from the right arch which continued as descending aorta, left CCA and left vertebral artery from the left arch, and left SCA arising from the proximal descending thoracic aorta. Other congenital anomalies like ostium secundum ASD, subaortic VSD, and left sided SVC were also observed in this case besides the double AA.

CONCLUSION

The thyroidea ima artery is rare in occurrence, with a variable origin and course, which contribute to the difficulty in its identification. Results of this study confirm reports in present literature on the prevalence of the thyroidea ima artery in the general population. Since TIA can be a cause for uncontrollable bleeding and complications during neck and thorax surgeries and endovascular interventions, its identification is essential to avoid them. The authors would like to suggest the use of screening imaging of the neck before tracheostomy or neck surgeries. Though our study was retrospective CECT based, we also recommend USG screening for identification of thyroidea ima artery as an arterial branch in the pretracheal region supplying the thyroid gland, so that accidental injury and uncontrollable haemorrhage could be avoided by proper planning.

The variations in the aortic arch branching are not uncommon, and many of them can be observed as incidental finding in routine diagnostic imaging, with contrast enhanced CT being a reliable tool to assess the vascular anatomy. The familiarity with the imaging appearance of aortic arch variants is essential, and given the prevalence demonstrated in our study, imaging should be included prior to procedures in order to prevent complications.

LIMITATIONS

The study was retrospective and cross-sectional; therefore, a complete clinical profile of the patients could not be obtained, and longitudinal studies may be warranted to address this deficiency. Since only the patients who underwent arch of aorta imaging were included in the study, it could have led to a selection bias.

REFERENCES

1. Yurasakpong L, Nantasenamat C, Janta S, Eiamratchanee P, Coey J, Chaiyamoorn A, Kruepunga N, Senarai T, Langer MF, Meemon K, Suwannakhan A. The decreasing prevalence of the thyroid ima artery: A systematic review and machine learning assisted meta-analysis. *Annals of Anatomy-AnatomischerAnzeiger*. 2022 Jan 1;239:151803.
2. Branca JJ, LascialfariBruschi A, Pilia AM, Carrino D, Guarnieri G, Gulisano M, Pacini A, Paternostro F. The Thyroid Gland: A Revision Study on Its Vascularization and Surgical Implications. *Medicina*. 2022 Jan 17;58(1):137.
3. Schleich JM. Development of the human heart: days 15–21. *Heart*. 2002 May 1;87(5):487-8.
4. H. A. Alsaif and W. S. Ramadan, "An anatomical study of the aortic arch anomalies," *Journal of King Abdulaziz University – Medical Sciences*, vol. 17,2010, pp. 37–54.
5. Jakanani GC, Adair W. Frequency of variations in aortic arch anatomy depicted on multidetector CT. *Clinical radiology*. 2010 Jun 1;65(6):481-7.
6. Müller M, Schmitz BL, Pauls S, Schick M, Röhrer S, Kapapa T, Schlötzer W. Variations of the aortic arch—a study on the most common branching patterns. *ActaRadiologica*. 2011 Sep;52(7):738-42.
7. Donnelly LF, Fleck RJ, Pacharn P, Ziegler MA, Fricke BL, Cotton RT. Aberrant subclavian arteries: cross-sectional imaging findings in infants and children referred for evaluation of extrinsic airway compression. *American Journal of Roentgenology*. 2002 May;178(5):1269-74.
8. Ramos-Duran L, Nance Jr JW, Schoepf UJ, Henzler T, Apfaltrer P, Hlavacek AM. Developmental aortic arch anomalies in infants and children assessed with CT angiography. *American Journal of Roentgenology*. 2012 May;198(5):W466-74.
9. Türkvtan A, Büyütkbayraktar FG, Ölçer T, Cumhuri T. Congenital anomalies of the aortic arch: evaluation with the use of multidetector computed tomography. *Korean Journal of Radiology*. 2009 Apr 1;10(2):176-84.
10. Shuford WH, Sybers RG, Edwards FK. The three types of right aortic arch. *Am J Roentgenol Radium TherNucl Med*. 1970;109:67-74.
11. Esen K, Ozgur A, Balci Y, Tok S, Kara E. Variations in the origins of the thyroid arteries on CT angiography. *Japanese Journal of Radiology*. 2018 Feb;36(2):96-102.
12. Chin J, Zhou Y, Wan PJ, Lomiguen CM. The prevalence of thyroid ima artery and its clinical significance. *International Journal of Otorhinolaryngology and Head and Neck Surgery*.

- 2019;5(4):845.
13. Gwilym S, Cooney A. Acute fatal haemorrhage during percutaneous dilatational tracheostomy. *British journal of anaesthesia*. 2004 Feb 1;92(2):298-298.
 14. Kamaroudi P, Paliouras D, Gogakos AS, Rallis T, Schizas NC, Lazopoulos A, Chatzinikolaou F, Sarafis P, Serchan P, Katsikogiannis N, Sarika E. Percutaneous tracheostomy—beware of the thyroidea-ima artery. *Annals of translational medicine*. 2016 Nov;4(22).
 15. Shaw JA, Gravereaux EC, Eisenhauer AC. Carotid stenting in the bovine arch. *Catheterization and cardiovascular interventions*. 2003 Dec;60(4):566-9.
 16. Layton KF, Kallmes DF, Cloft HJ, Lindell EP, Cox VS. Bovine aortic arch variant in humans: clarification of a common misnomer. *American Journal of Neuroradiology*. 2006 Aug 1;27(7):1541-2.
 17. Baadh AS, Rockman CB, Mitnick RJ, Lim RP. Bovine arch and carotid artery atherosclerosis: are they related?. *Clinical Imaging*. 2014 Sep 1;38(5):681-5.
 18. Moore, Keith L., T. V. N. Persaud, and M. G. Tochia. "The development Human clinically oriented embryology 7th ed." 2003: 259-263.
 19. Graham JM, Feliciano DV, Mattox KL, Beall Jr AC. Innominate vascular injury. *The Journal of trauma*. 1982 Aug 1;22(8):647-55.
 20. R. A. Bergman, A. K. Afifi, and R. Miyauchi, "Illustrated encyclopedia of human anatomic variation," 2000, <http://www.anatomyatlases.org/AnatomicVariants/Cardiovascular/Text/Arteries/Aorta.shtml>.
 21. Nayak SR, Pai MM, Prabhu LV, D'Costa S, Shetty P. Anatomical organization of aortic arch variations in the India: embryological basis and review. *Jornal Vascular Brasileiro*. 2006 Jun;5(2):95-100.
 22. Satti SR, Cerniglia CA, Koenigsberg RA. Cervical vertebral artery variations: an anatomic study. *American Journal of Neuroradiology*. 2007 May 1;28(5):976-80.
 23. Sukumaran TT, Pillay M, Gopalakrishnan A. An anomalous right subclavian artery with a retrotracheal course: a case report. *Journal of Clinical and Diagnostic Research: JCDR*. 2015 Nov;9(11):AD01.
 24. FehmiYazıcıoğlu H, Sevket O, Akın H, Aygün M, Özyurt ON, Karahasanoğlu A. Aberrant right subclavian artery in Down syndrome fetuses. *Prenatal Diagnosis*. 2013 Mar;33(3):209-13.
 25. Hori D, Tanaka M, Yamaguchi A, Adachi H. Type A aortic dissection, right-sided aortic arch, and thoracic aortic aneurysm. *Asian Cardiovascular and Thoracic Annals*. 2009 Dec;17(6):640-2.
 26. McElhinney DB, Hoydu AK, Gaynor JW, Spray TL, Goldmuntz E, Weinberg PM. Patterns of right aortic arch and mirror-image branching of the brachiocephalic vessels without associated anomalies. *Pediatric cardiology*. 2001 Jul;22(4):285-91.
 27. Backer CL, Mongé MC, Popescu AR, Eltayeb OM, Rastatter JC, Rigsby CK. Vascular rings. In *Seminars in pediatric surgery* 2016 Jun 1 (Vol. 25, No. 3, pp. 165-175). WB Saunders.
 28. Guo Q, Kong Y, Zeng S, Zhou J, Wang X, Shang Q, Zhou J, Yuan H, Wang L, Tong L, Yi A. Fetal double aortic arch: prenatal sonographic and postnatal computed tomography angiography features, associated abnormalities and clinical outcomes. *BMC Pregnancy and Childbirth*. 2020 Dec;20(1):1-0.
 29. Nagre SW, Kulkarni DV. Double aortic arch surgery. *Indian Journal of Vascular and Endovascular Surgery*. 2015 Jul 1;2(3):118.
 30. Lale P, Toprak U, Yagız G, Kaya T, Uyanık SA. Variations in the branching pattern of the aortic arch detected with computerized tomography angiography. *Advances in Radiology*. 2014 Jun 29;2014.

