

Study of Variant Innervations of Extensor Carpi Radialis Brevis Muscle with its Clinical Importance

Sharadkumar Pralhad Sawant*, Dope Santoshkumar A., MBBS, MS (Anatomy)**

Abstract

Aim: To study the nerve supply to the extensor carpi radialis brevis muscle.

Materials and Methods: 100 upper limbs of 50 donated embalmed cadavers (45 males & 5 females) of age group ranging from 70 to 80 years were studied in the department of Anatomy at K. J. Somaiya Medical College, Sion, Mumbai, INDIA, the nerve supply to Extensor carpi radialis brevis muscle was observed. The finding was noted after thorough and meticulous dissection of the upper limbs of both sides. The arterial pattern of upper limb were also observed. The photographs of the variations were taken for proper documentation.

Results/Observations: In 36 specimens of the upper limbs, the nerve supply to extensor carpi radialis brevis was from the deep branch of radial nerve i.e. the posterior interosseous nerve. In the remaining 64 upper limbs, the nerve supply to extensor carpi radialis brevis was from the angle of bifurcation of radial nerve in 22 specimens and from the superficial branch of radial nerve i.e. the radial nerve proper in 42 specimens.

Conclusions: The awareness of the nerve supply to extensor carpi radialis brevis from superficial branch of radial nerve is clinically important for surgeons dealing with entrapment or compressive neuropathies, orthopaedicians operating on the fractures of the lower end of the humerus, anaesthetist performing pain management therapies on the upper limb and physiotherapist doing electromyography for evaluating and recording the electrical activity produced by skeletal muscles. A lack of knowledge of such type of variations might complicate surgical repair.

Keywords: Extensor Carpi Radialis Brevis; Superficial Radial Nerve; Nerve Variation; Surgeons; Compressive Neuropathies; Orthopaedicians; Fractures; Anaesthetist; Pain Management Therapy; Physiotherapist; Electromyography.

Introduction

The extrinsic extensor muscles of the hand are located in the back of the forearm and have long tendons connecting them to bones in the

hand, where they exert their action. Extrinsic denotes their location outside the hand. Extensor denotes their action which is to extend, or open flat, joints in the hand. The extensor carpi radialis brevis is one of the superficial muscles of the extensor compartment of the forearm. The extensor carpi radialis brevis muscle is shorter and thicker than the extensor carpi radialis longus muscle. It arises from the lateral epicondyle of the humerus, by a tendon common to it and the three following muscles; from the radial collateral ligament of the elbow-joint; from a strong aponeurosis which covers its surface; and from the intermuscular septa between it and the adjacent muscles. The fibers end about the middle of the forearm in a flat tendon,

Author's Affiliation: *Associate Professor, Department of Anatomy, K. J. Somaiya Medical College, Somaiya Ayurvihar, Eastern Express Highway, Sion, Mumbai-400 022, **Assistant Professor, Dept of Anatomy, Government Medical College, Latur-413512 (Maharashtra)

Reprint's request: Dr. Sharadkumar Pralhad Sawant, 25/2, Samrat Ashok Nagar Society, Shell Colony Road, Chembur, Mumbai - 400 071, Maharashtra, India. Phone : 022-22936867, 09322061220

E-mail: drspsawant@gmail.com

(Received on 24.04.2013, accepted on 22.05.2013)

which is closely connected with that of the extensor carpi radialis longus muscle, and accompanies it to the wrist; it passes beneath the abductor pollicis longus and extensor pollicis brevis, then beneath the dorsal carpal ligament, and is inserted into the dorsal surface of the base of the third metacarpal bone on its radial side. Under the dorsal carpal ligament the tendon lies on the back of the radius in a shallow groove, to the ulnar side of that which lodges the tendon of the extensor carpi radialis longus, and separated from it by a faint ridge. The tendons of the two preceding muscles pass through the same compartment of the dorsal carpal ligament in a single mucous sheath. The extensor carpi radialis brevis muscle may split into two or three tendons of insertion to the second and third or even the fourth metacarpal. The extensor carpi radialis longus and brevis muscles may unite into a single belly with two tendons. The cross slips between the two muscles may occur. The extensor carpi radialis intermedius rarely arises as a distinct muscle from the humerus, but is not uncommon as an accessory slip from one or both muscles to the second or third or both metacarpals. The extensor carpi radialis accessorius is occasionally found arising from the humerus with or below the extensor carpi radialis longus and inserted into the first metacarpal, the abductor pollicis brevis, the first dorsal interosseous, or elsewhere. The extensor carpi radialis longus muscle is supplied by the radial nerve and the extensor carpi radialis brevis muscle by the deep branch of the radial nerve (posterior interosseous nerve). The extensor carpi radialis longus and brevis muscles receive blood from the radial artery.[1] It is a universally accepted fact that the variation in the nerve supply to any muscle of the extremity is of definite surgical importance in order to avoid any error surgery.

Material and Methods

100 upper limbs of 50 donated embalmed cadavers (45 males & 5 females) of age group ranging from 70 to 80 years were studied in the department of Anatomy at K. J. Somaiya

Medical College, Sion, Mumbai, INDIA, the nerve supply to the extensor carpi radialis brevis muscle was observed. The finding was noted after thorough and meticulous dissection of the upper limbs of both sides. The superficial muscles of the extensor compartment of the forearm were separated from each other, starting with the tendons at the wrist. The three anterolateral muscles the brachioradialis, extensor carpi radialis longus and brevis were completely separated from the extensor digitorum and the supinator muscle which lay deep in these muscles, was exposed. The deep branch of the radial nerve, the posterior interosseous nerve, was dissected. The nerve which supplied extensor carpi radialis brevis was then identified in all the specimens. Observations were made on the basis of origin of the nerve to the extensor carpi radialis brevis either from the angle of bifurcation of radial nerve or from the deep branch of the radial nerve or from the superficial branch of the radial nerve. The arterial pattern of upper limb were also observed. The photographs of the variations were taken for proper documentation.

Results / Observations

The nerve to the extensor carpi radialis brevis arose from the deep branch of the radial nerve before it entered the supinator muscle in 36 upper limbs. In the remaining 64 upper limbs, the nerve supply to extensor carpi radialis brevis was from the angle of bifurcation of radial nerve in 22 specimens and from the superficial branch of radial nerve i.e. the radial nerve proper in 42 specimens (Table 1). The radial nerve was divided most commonly above the level of the lateral epicondyle in 60%, followed by its division at the level of the lateral epicondyle in 30% and in the remaining 10% limbs, it was divided below this level (Table 2). In 78% of the limbs, the radial nerve divided into two branches i.e. superficial and deep branches and in the remaining 22% limbs, it showed three divisions, the third being the nerve to the extensor carpi radialis brevis (Table 3). In none of the specimen the nerve to

Table 1: Nerve supply to extensor carpi radialis brevis muscle

Nerve supply to extensor carpi radialis brevis muscle derived from	No. of specimes	%
Deep branch of the radial nerve	36	36
Angle of bifurcation of radial nerve	22	22
Superficial branch of radial nerve	42	42

Table 2: Division of radial nerve

Division of radial nerve	No. of specimes	%
Above the level of lateral epicondyle	60	60
At the level of lateral epicondyle	30	30
Below the level of lateral epicondyle	10	10

Figure 1: Showing photographic presentation of the nerve to the extensor carpi radialis brevis arising from the superficial branch of the radial nerve i.e. radial nerve proper.

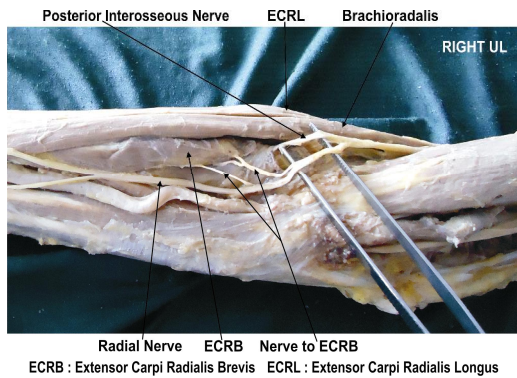


Figure 2: Showing photographic presentation of the nerve to the extensor carpi radialis brevis arising from the superficial branch of the radial nerve i.e. radial nerve proper

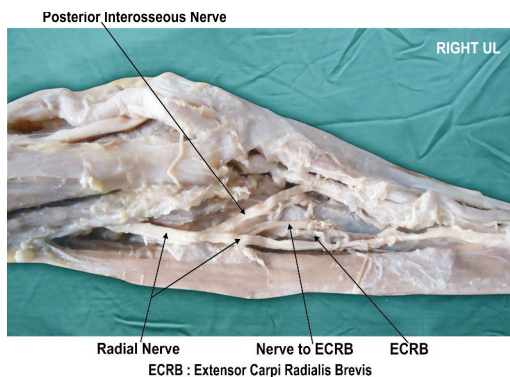


Figure 3: Showing photographic presentation of the nerve to the extensor carpi radialis brevis arising from the superficial branch of the radial nerve i.e. radial nerve proper

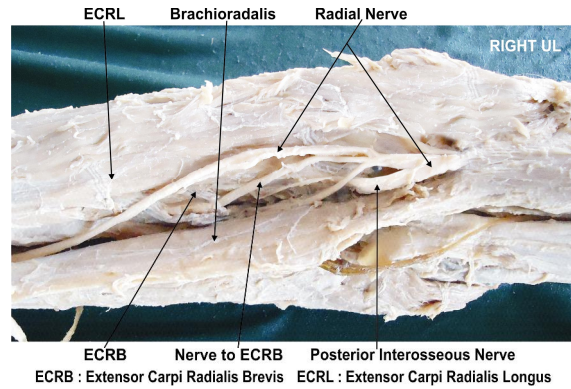


Figure 4: Showing photographic presentation of the nerve to the extensor carpi radialis brevis arising from the superficial branch of the radial nerve i.e. radial nerve prope

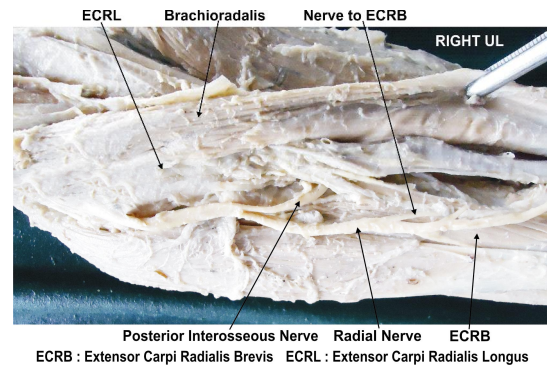


Figure 5: Showing photographic presentation of the nerve to the extensor carpi radialis brevis arising from the superficial branch of the radial nerve i.e. radial nerve proper

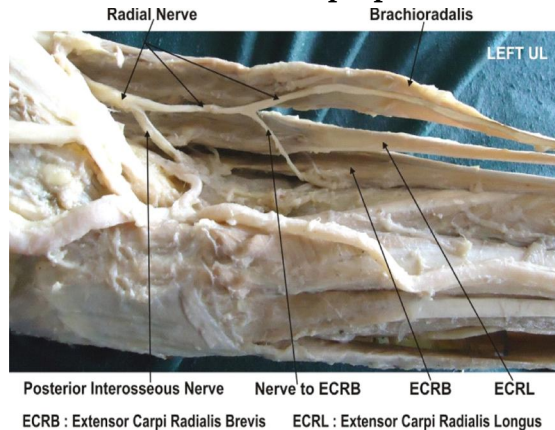


Figure 6: Showing photographic presentation of the nerve to the extensor carpi radialis brevis arising from the superficial branch of the radial nerve i.e. radial nerve proper

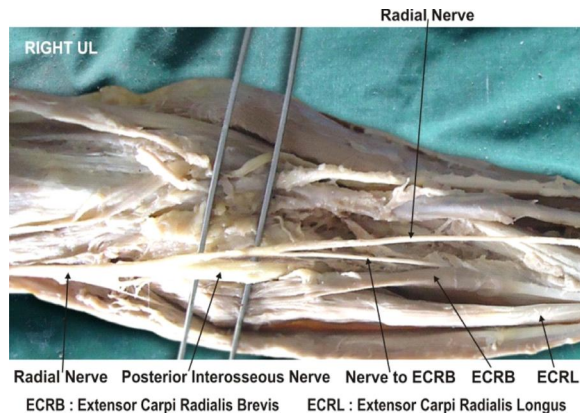


Figure 7: Showing photographic presentation of the nerve to the extensor carpi radialis brevis arising from the superficial branch of the radial nerve i.e. radial nerve proper

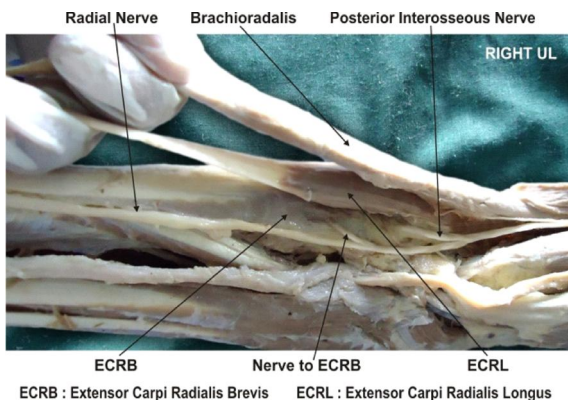


Figure 8: Showing photographic presentation of the nerve to the extensor carpi radialis brevis arising from the angle of bifurcation of the radial nerve

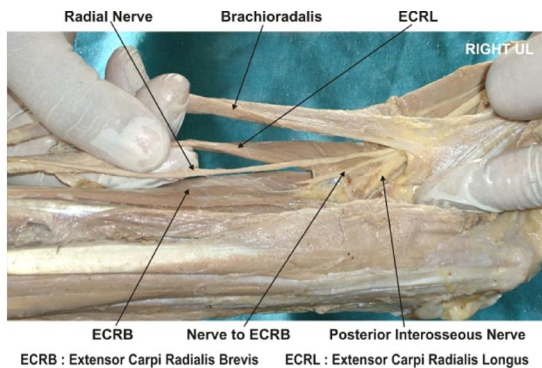


Figure 9: Showing photographic presentation of the nerve to the extensor carpi radialis brevis arising from the angle of bifurcation of the radial nerve

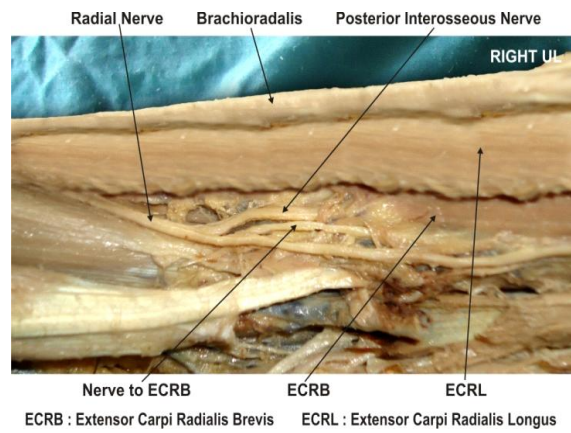


Table 3: Division of radial nerve

Division of radial nerve	No. of specimens	%
Into two branches - superficial branch and deep branch of the radial nerve.	78	78
Into three branches - superficial branch, deep branch of the radial nerve and nerve to the extensor carpi radialis brevis.	22	22

the extensor carpi radialis brevis was seen to arise from the radial nerve trunk above the level of its division.

Discussion

The nerve supply to the extensor carpi radialis brevis muscle is studied by many authors in the past.[2,3,4,5,6,7,8] The superficial branch of the radial nerve i.e. radial nerve proper is a purely sensory nerve and the nerve supply to the extensor carpi radialis brevis muscle is from the posterior interosseous nerve. The standard text books did not mention about the nerve supply to the extensor carpi radialis brevis arising from the superficial branch of the radial nerve i.e. radial nerve proper.[1] The incidence of the nerve supply to the extensor carpi radialis brevis muscle from the superficial branch of the radial nerve i.e. radial nerve proper had been reported by Salisbury, Al- Qattan and Brash as 56%, 48%

Table 4: Comparison with previous studies as gleaned from literature

Nerve supply to the extensor carpi radialis brevis from superficial branch of the radial nerve i.e. radial nerve proper	No. of specimes	%
Salisbury - 1938 (9)	56	56
Al- Qattan - 1996 (10)	48	48
Brash - 1955 (11)	21	21
Sawant et al - 2012 (Present study)	42	42

and 21% limbs respectively.[9,10,11] In the present study the nerve supply to the extensor carpi radialis brevis muscle from the superficial branch of the radial nerve i.e. radial nerve proper was observed in 42 upper limbs.

Compared with the previous studies the incidence of the origin of the nerve to the extensor carpi radialis brevis muscle from the superficial branch of the radial nerve i.e. radial nerve proper documented in the present study was higher than the study of Brash and lower than the study of Salisbury and Al-Qattan (Table 4). In the present study it was also observed in 22 specimens the radial nerve divides into three branches, superficial branch of radial nerve i.e. the radial nerve proper, deep branch of the radial nerve (posterior interosseous nerve) and nerve to the extensor carpi radialis brevis muscle. The nerve supply to the extensor carpi radialis brevis muscle was from that terminal branch of the radial nerve i.e. nerve to the extensor carpi radialis brevis muscle. This high percentage cannot be ignored as a rare variation. In tennis elbow the muscle involved is the extensor carpi radialis brevis.[12] The non-inflammatory, chronic degenerative changes occurs in the origin of the extensor carpi radialis brevis muscle.[13] The knowledge of the variant nerve supply to the extensor carpi radialis brevis muscle is important before injecting corticosteroid injections in the treatment of tennis elbow.[14] The surgeons performing Z-shaped tenotomy on tennis elbow to lengthen the tendon of extensor carpi radialis brevis must be aware of this variation in order to avoid unwanted complications.[15,16] Variations in the nerve supply of the extensor carpi radialis brevis are important in the clinically. The extensor carpi radialis brevis

may be spared in injuries to the posterior interosseous nerve, thereby explaining the preservation of some wrist function clinically after penetrating injuries which may otherwise result in a complete wrist drop. Similarly, the injuries to the superficial radial nerve, which is suppose to be a sensory nerve, may lead to pain during the extension of the wrist and slight weakness on the extension on the wrist joint due to involvement of the nerve supply of the extensor carpi radialis brevis.[17] Recently, extensor carpi radialis brevis has also gained importance for use in 'free functional muscle transfer' i.e. transfer of a muscle with its motor nerve and vascular pedicle from one site of the body to another distant site, in order to restore the motor function.[18] The knowledge of the variations in the nerve supply is thus important while this muscle is being harvested. It is well known that the normal origin and the course of the nerve to the extensor carpi radialis brevis lie very close to the posterolateral aspect of the radius, a frequent site of pathology (e.g. infections and tumours), trauma and surgical procedures.[19,20,21] The anterior approach to the elbow and the variations in this approach are used frequently in the surgical management of proximal radial fractures, as well as a variety of other pathologies.[22,23] Such manouvers involve the separation of the extensor carpi radialis brevis distally, with resultant exposure of the radial nerve and its branches.[24] Hence, the knowledge of variations of the nerve supply of the extensor carpi radialis brevis is essential in preventing injury to this nerve branch by the retractors.

Clinical significance

The awareness of the nerve supply to extensor carpi radialis brevis from superficial branch of radial nerve is clinically important for surgeons dealing with entrapment or compressive neuropathies, orthopaedicians operating on the fractures of the lower end of the humerus, anaesthetist performing pain management therapies on the upper limb and physiotherapist doing electromyography for

evaluating and recording the electrical activity produced by skeletal muscles. A lack of knowledge of such type of variations might complicate surgical repair.

Conclusion

The nerve supply to the extensor carpi radialis brevis from the superficial branch of the radial nerve is not a rare occurrence. This should be mentioned in the standard textbooks of anatomy and plastic surgery. The knowledge of the variations in the nerve supply of extensor carpi radialis brevis is important for plastic surgeons performing 'free functional muscle transfer'.

Competing interests

The author declare that he has no competing interests.

Acknowledgement

Author is also thankful to Dean Dr. Geeta Niyogi Madam for her support and encouragement. Author is also thankful to Dr. Arif A. Faruqui and Mr. M. Murugan for their help. Author also acknowledge the immense help received from the scholars whose articles are cited and included in references of this manuscript. The author is also grateful to authors / editors / publishers of all those articles, journals and books from where the literature for this article has been reviewed and discussed.

References

- Williams PL, Bannister LH, Berry MM, Collins P, Dyson M, Dussek JE, et al. The Nervous system. In: Gray's Anatomy, 39th edn. New York: Churchill Livingstone; 2005, 879 - 880.
- Hamilton WJ. Textbook of the Human Anatomy, 2nd edn. London: Macmillan Press Ltd.; 1976, 651.
- Last RJ. Anatomy: Regional and Applied, 7th edn. Edinburgh: Churchill Livingstone; 1984, 89.
- Tountas CP, Bergman RA. Anatomic variations of the upper extremity. New York: Churchill Livingstone; 1993, 11.
- Snell RS. Clinical Anatomy for Medical Students, 5th edn. Little Brown and Company, USA; 1995, 434.
- Turck SL. Orthopaedic principles and their applications, 4th edn. Philadelphia: JB Lippincott; 1984, 497- 498.
- Kaplan EB, Taleisnik J. The wrist. In: Kaplan's Functional and Surgical Anatomy of the Hand, 3rd edn. Philadelphia: JB Lippincott; 1984, 153-178.
- Sabiston DC. The biological basis of modern surgical practice. In: The Textbook of Surgery, 15th edn. Philadelphia: WB Saunders Company; 1997, 1484.
- Salisbury CR. The nerve to the extensor carpi radialis brevis. *Brit J Surg.* 1938; 26: 95-98.
- Al-Qattan MM.. The nerve supply to the extensor carpi radialis brevis. *J Anat.* 1996; 188: 249-50.
- Brash JC. Neurovascular hila of the limb muscles. Edinburgh: E and S Livingstone Ltd.; 1955, 36.
- Garden RS. Tennis elbow. *J Bone Joint Surg.* 1961; 43B(1): 100-106.
- Kalainov D, Cohen MS. Posterolateral rotatory instability of the elbow in association with lateral epicondylitis. A report of three cases. *J Bone Joint Surg Am.* 2005; 87(5): 1120-1125. [PubMed]
- Edwards SG, Calandruccio JH. Autologous blood injections for refractory lateral epicondylitis. *J Hand Surg [Am].* 2003; 28(2): 272-278.
- Boyer MI, Hastings H. Lateral tennis elbow: "Is there any science out there?". *Journal of Shoulder and Elbow Surgery.* 1999; 8(5): 481-91. doi:10.1016/S1058-2746(99)90081-2. PMID 10543604.
- Meyer NJ, Walter F, Haines B, Orton D, Daley RA. Modeled evidence of force reduction at the extensor carpi radialis brevis origin with the forearm support band. *J Hand Surg [Am].* 2003; 28(2): 279-287.
- Lluch AL, Beasley RW. Treatment of

- dysesthesia of the sensory branch of the radial nerve by distal posterior interosseous neurectomy. *J Hand. Surg.* 1989; 14A: 121-24.
18. Binhammer P, Manktelow RT, Haswell T. Applications of the extensor carpi radialis brevis for facial reanimation. *Journal of Reconstructive Microsurgery.* 1994; 10: 109.
 19. Prasaritha T, Liupolvanish P, Rojanakit A. A study of the posterior interosseous nerve and the radial tunnel in 30 Thai cadavers. *J Hand Surg.* 1993; 18A: 107-12.
 20. Crecenti SV, DeAngelis MS, DiDio LJA, Ebraheim NA, Rupp RE, DiDio AS. Innervation of the extensor carpi radialis brevis and the supinator muscles: Levels of origin and penetration of these muscular branches from the posterior interosseous nerve. *Shoulder Elbow Surg.* 1994; 3: 390-94.
 21. Abrahams RA, Ziets RJ, Lieber RL, Botte MJ, Diego S. Anatomy of the motor branches of the radial nerve in the forearm. *J Hand Surg.* 1997; 22A: 232-37.
 22. Branovacki G, Hanson M, Crash R, Gonzalez M. The innervation pattern of the radial nerve at the elbow and in the forearm. *J Hand Surg.* 1998; 23B(2): 167-69.
 23. Thomas SJ, Yakin DE, Parry BR, Lubahn JD, Erie PA. The anatomical relationship between the posterior interosseous nerve and the supinator muscle. *J Hand Surg.* 2000; 25A: 936-41.
 24. Latev MD, Dalley AF. Nerve supply of the brachioradialis muscle: Surgically relevant variations of the extramuscular branches of the radial nerve. *Clin Anat.* 2005; 18: 488-92.
-

Red Flower Publication Pvt. Ltd,

CAPTURE YOUR MARKET

For advertising in this journal

Please contact:

International print and online display advertising sales

E-mail: redflowerppl@vsnl.net / tel: +91 11 22754205

Recruitment and Classified Advertising

E-mail: redflowerppl@vsnl.net / tel: +91 11 22754205