

A Study of Morphology of Psoas Minor Muscle in Human Cadavers

Shilpa Bhimalli*, Daksha Dixit**, S.P. Desai***, Amit Magdum****, Sheetal Pattanshetti****

Abstract

The Psoas Minor is a slender Muscle lying on the surface of Psoas Major Muscle. It is functionally a weak muscle that assists Psoas major in flexion of the trunk and vertebral column. The muscle normally arises from the sides of the bodies of twelfth thoracic vertebra and first lumbar vertebra with corresponding intervertebral disc. *Materials and Method:* The study is conducted on 30 cadavers from the Department of Anatomy J.N. Medical College Belagavi. The Psoas minor muscle was observed from its origin to its insertion. Length and width of the muscle, its fleshy belly and tendon part of the muscle was measured and the observations were tabulated. The normal anatomy and variations of the muscle were noted. *Results:* In the present study it was observed that the Psoas minor was present in 60% (18/30 cadavers) and absent in 40% (12/30 cadavers). It was observed that the muscle was bilaterally seen in 18 cadavers, and 12 cadavers showed unilateral presence. *Conclusion:* In the present study, conducted on 30 cadavers, the Psoas minor muscle was observed in 60% of cadavers. It was bilaterally seen in 7 cadavers and unilaterally seen in 5 cadavers. The normal anatomy and variations were noted. In any lower spine surgeries, the normal and variant anatomy of the muscle is important to note, and if neglected can lead to any complications during the surgery.

Keywords: Fleshy & Tendinous Part; Psoas Minor Muscle; Unilateral Muscle.

Introduction

The Psoas Minor is a slender Muscle lying on the surface of Psoas Major Muscle. It is functionally a weak muscle that assists Psoas major in flexion of the trunk and vertebral column. The muscle normally arises from the sides of the bodies of twelfth thoracic vertebra and first lumbar vertebra with corresponding intervertebral disc. The origin of the muscle varies from thin slender to broad and thick belly. The muscle is normally inserted to the pectineal line of pubis and iliopectinate eminence. The insertion of the muscle varies with formation of thin long tendon inserting to bony attachment or merging with the fascia. Psoas

minor receives its nerve supply from the ventral rami of L1 spinal nerve. The Psoas minor muscle is well developed in lower animals that run very fast. While in humans it has clinical significance in sport person, more commonly affected are the foot ball players [1]. It is muscle that has highest percentage of unilateral or bilateral agenesis between 40% and 66% of the population [2]. The study is aimed to obtain a detailed knowledge of morphometry of Psoas minor muscle.

Materials and Method

The study is conducted on 30 cadavers from the Department of Anatomy J.N. Medical College Belagavi. The posterior abdominal wall muscles were exposed and then the Psoas minor muscle was noted. The Psoas minor muscle was observed from its origin to its insertion. Length and width of the muscle, its fleshy belly and tendon part of the muscle was measured and the observations were tabulated. The normal anatomy and variations of the muscle were noted.

Author's Affiliation: *Associate Professor, **Professor, ***HOD & Professor, ****Assistant Professor, KLE University's Department of Anatomy Jawaharlal Nehru medical College, Belagavi.

Corresponding Author: Shilp Bhimalli, Associate Professor, KLE University's Department of Anatomy Jawaharlal Nehru medical College, Nehru Nagar, Belagavi, Karnataka 590010

E-mail: shilpambhimalli@gmail.com,

Results

In the present study it was observed that the Psoas minor was present in 60% (18/30 cadavers) and absent in 40% (12/30 cadavers). It was observed that the muscle was bilaterally seen in 7 cadavers, and 5 cadavers showed unilateral presence. The muscle belly originated normally in all the cadavers. The average length of the fleshy belly was 7.5cm and width was 1.91cm. (Table 1).

Tendon, in all cadavers was long, slender and

Table 1: The length and width of the fleshy belly of the Psoas minor muscle

S. No	Length of fleshy belly(cm)	Width of fleshy belly(cm)
1	7.5	2
2	7	1.5
3	5.5	2.5
4	4.5	2
5	9	2
6	7	2.5
7	7.5	1
8	6.5	1.7
9	8	2
10	7.5	2
11	7	2.5
12	7	2
13	8	2
14	7.5	1.5
15	6.5	1.5
16	7.5	1.5
17	7	2
18	7	2
19	8	1.8
20	8.5	1.5
21	7.5	2
22	7	2
23	7	2.5
24	8	1.5
25	8	1.2
26	7.5	1.5
27	9.5	2
28	7	2.5
29	7	1.5
30	6.5	1.5

flattened. The average length of the tendon was 11.17cm and width was 0.7cm (Table 2).

The tendon flattened towards the insertion. Variations were observed in the morphology of the muscle. In one cadaver it was seen that the muscle had a fleshy origin, was very short and broad, and had a long slender tendon (Figure 1).

In another cadaver it was observed that the muscle had a normal origin, but the tendon was slender and long, and merged with iliopsoas fascia. The muscle received the nerve supply from L1 from Lumbar plexus (Figure 2).

Table 2: The length and breadth of tendinous part of Psoas minor muscle

S. No	Tendon length(cm)	Tendon width(cm)
1	11	.5
2	10.5	.5
3	11.5	.5
4	12	.8
5	12	1
6	11	1
7	12.5	.5
8	11.5	.5
9	12	1
10	10	1
11	11	1
12	12	.8
13	12	.5
14	12.5	.5
15	11.5	.5
16	11.6	1
17	11.5	1
18	10.5	.5
19	11	.5
20	10	.4
21	11.5	.8
22	12.5	1
23	12	1.2
24	10.5	1.2
25	11.5	.5
26	11.6	.5
27	11.6	.6
28	12.5	1
29	13	1
30	13.5	1.5

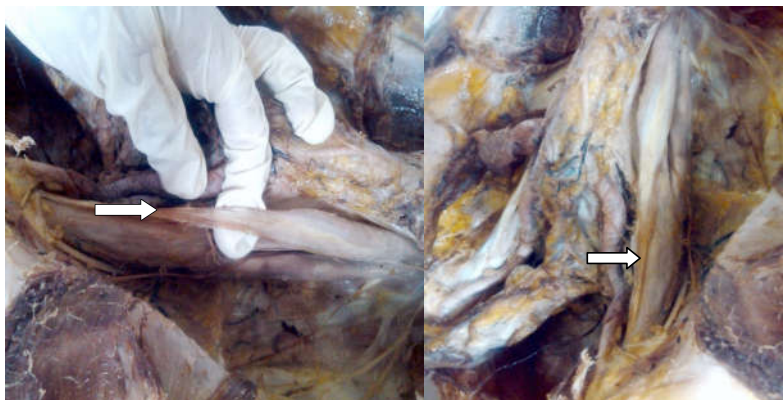

Fig. 1: Showing psoas minor muscle with long slender tendon

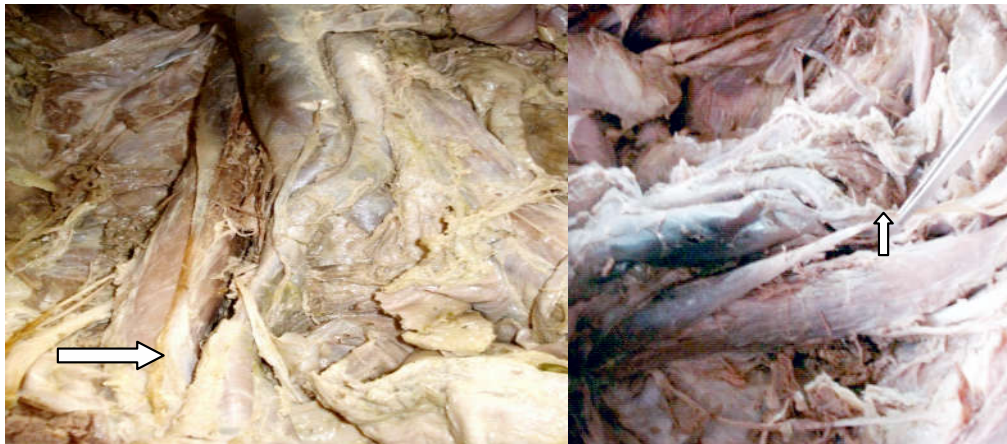

Fig. 2: Showing the psoas minor muscle tendonous part merged with iliopsoas fascia

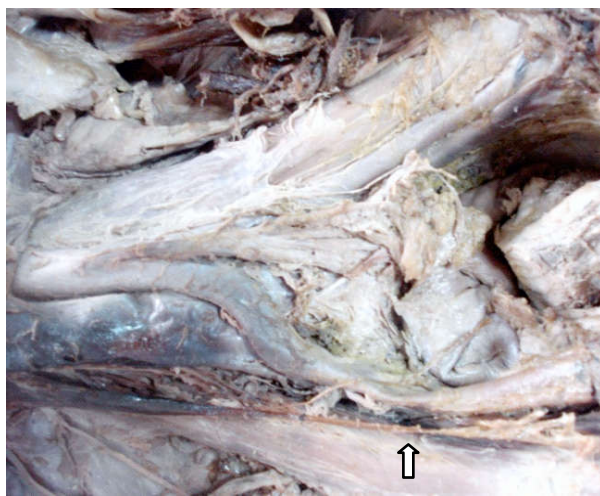


Fig. 3: Showing the psoas minor muscle appearing like a sling

In an another cadaver it was observed that the muscle was very thin, both the fleshy and tendonous part was appearing like a sling (Figure 3).

Discussion

In a study by Kraycheter et al, the Psoas minor muscle was present in only 30% of the cases³. While in another study by Danillo et al, the presence of the muscle was observed in 59% of the human fetuses⁴. While in the present study the Psoas minor was observed in 60% of the cadaver

	Researcher	Year	Incidence %
1	Snell R.S Kraychete D.C	1993	60%
2	Kraychete D.C	2007	30%
3	Guerra D.R eta	2012	59.9%
4	Danillo	2012	59%
5	Sonali Agichan et al	2013	40%
6	Present	2014	60%

In majority, Psoas minor muscle is deficient similar to commonly absent muscle like

Pyramidalis, Peroneus tertius, Palmaris longus and plantaris⁵.

The psoas minor muscle arises as a fleshy belly arising from the first two lumbar vertebrae and intervertebral disc which was observed in present cases. In a study by Macalister, the author observed variation in origin, where the fibres of the Psoas minor muscle originated as a ramification of the fibres of psoas major in some cases.

Bergman and Afifi showed variations of insertions on the inguinal ligament, femoral neck and lesser trochanter of the femur [6]. In a description by Gardner et al, they reported that this muscle was inserted by means of thin tendon into the iliopubic eminence and arcuate line and that it had an additional insertion into iliac fascia and pectineal ligament [7]. In the present study the thin tendon was long slender flattened at the insertion into iliopectinate line and in cases blended with iliopsoas fascia.

Psoas Minor is found to be consistently absent in those with Trisomy 18. Higher frequency of muscle anomalies in aneuploidy is due to delayed developmental process in them [8].

Psoas minor syndrome is attributed to unusual high tone in Psoas minor muscle and tendon, the patient complains of pain in lower quadrant of abdomen. In this syndrome, there is limited extension; tenotomy is only treatment which relieves the symptoms [8].

Conclusion

In the present study, conducted on 30 cadavers, the Psoas minor muscle was observed in 60% of cadavers. It was bilaterally seen in 7 cadavers and unilaterally seen in 5 cadavers. The normal anatomy

and variations were noted. In any lower spine surgeries, the normal and variant anatomy of the muscle is important to note, and if neglected can lead to any complications during the surgery.

References

1. Kocho T V, Psoas minor strain In- Sports medicine & rehabilitation, International. Bradenton FL. (2004-2012).
2. Tellez V, Acuna L. Consideraciones Anatomicas de los Musculos Inconstantes. Med Unab; 1998.
3. Kraychete DC, Rocha APC, Castro PACR de. Psoas muscle abscess after epidural analgesia: case report. Rev. Bras. Anesthesiol. 2007 Apr; 57(2): 195-8.
4. Danillo Ribeiro Guerra, Francisco Prado Reis, Afrânio de Andrade Bastos,, Ciro José Brito, Roberto Jerônimo dos Santos Silva , José Aderval Aragão: Anatomical Study on the Psoas Minor Muscle in Human Fetuses. Int. J. Morphol. 2012; 30(1): 136-139.
5. Macalister, A. Additional observations on muscular anomalies in human anatomy (third series), with acatalogue of the principal muscular variations hitherto published. Trans. Roy. Irish. Acad. 1875; 25: 1-130.
6. Snell R. membro inferior. In: Snell P, editor. Anat. Clin. Para Estud. Med. 5th ed. Rio de Janeiro; 1999.
7. Bergman, RA. and Afifi, AK. The Virtual Hospital. Illustrated Encyclopedia of Human Anatomy. Part 1: muscular system: palmaris longus; 1997.
8. Moore K, Dally K. Anatomia orientada para a clinica. 5th ed. Rio di Janeiro: Guanabara Kougan; 2007.
9. Travell J, Simons D. Myofascial Pain and Dysfunction: The Trigger Point Manual; the Lower Extremities. 2nd ed. Philadelphia: Lippincott Williams and Wilkins; 1998; Vol. 2.