

Death due to Accidental Electrocution: Social Aspects: A Case Report

Hemant Kumar¹, Vanika², Ruchi K³, Aravindan V⁴, Arijit Dey⁵

Author Affiliation: ^{1,5}Senior Resident, ^{2,3,4}Junior Resident
Department of Forensic Medicine, All India Institute of
Medical Sciences, Sri Aurobindo Marg, Ansari Nagar, Ansari
Nagar East, New Delhi, Delhi 110029, India.

Corresponding Author: Arijit Dey, Senior Resident, Room
No. 302, Department of Forensic Medicine and Toxicology,
All India Institute of Medical Sciences, Sri Aurobindo Marg,
Ansari Nagar, Ansari Nagar East, New Delhi 110029, India.

E-mail: arijit.forensic@gmail.com

Abstract

Background: The passage of electric current through human body can produce multiple effects, commonly known as Electrocution. The passage of electric current through the body produces wide range of effects, varying from insignificant localized spasm, little or no contact burns, fatality with little or no burns or extreme severe burning. **Case Report:** A detailed history of the incident revealed that the bike rider skid and fell on the water logged road in rainy season and came in contact with the high tension wire and was electrocuted. The second person tried to attend to the bike driver and he also came in contact with the same wire and died instantly. Autopsy revealed external electrocution injuries on both deceased. Both these deaths were accidental in nature and were preventable. Histopathological examination of the electric contact point showed elongation and streaming of nuclei with focal inter-epidermal and epidermal-dermal separation. **Conclusion:** This present article focuses on need for proper development of water drainage system especially during rainy season and also to generate public awareness regarding regular supervision of roadside Electric pole and wires which could prevent similar accidents. A detailed history regarding the incidence, scene visit, circumstantial evidence, statement of witness and proper postmortem examination with the histopathological examination are recommended prior to concluding the cause of death in case of alleged death due to electrocution. The data can be used for further planning and implementation of adequate measures to prevent accidents and thereby benefit the society.

Keywords: Electrocution; Rainy season; High tension wire; Water logging; Electric contact point.

How to cite this article:

Hemant Kumar, Vanika, Ruchi K, et al. Death due to Accidental Electrocution: Social Aspects: A Case Report. J Forensic Chemistry Toxicol 2020;6(1):73–78

Introduction

The passage of electric current through human body can produce multiple effects, commonly known as Electrocution, varying from a localized muscle spasm to internal organ damage and even sudden death of the person. Electric fatalities are usually accidental in nature.¹ In India, with high population density, most people tend to flout the building rules with regards to electricity, high tension wires pass by roadsides in the electric poles, which may lead to accidental electrocution.² Severity of electrocution injuries mainly depends on the path traversed by the current along with type and duration of its contact with the body. High voltage electrical injuries are relatively uncommon but contribute

to occupational fatalities due to hazardous exposure during their tasks at workplaces.³ In case of death due to alleged electrocution, proper history of incidence with examination of scene of occurrence and a detailed postmortem examination by an autopsy surgeon may help to conclude the cause of death and its manner, for the purpose of compensation and help to implement future preventive policies to reduce such incidences. The authors describe one such case of accidental death due to electrocution in a water logged road in rainy season, and discuss the preventive aspects.

Case Details

Case 1: A 28-year old male deceased was brought

to mortuary of JPNATC, AIIMS, New Delhi, after being recovered from road. The victim was driving his bike on road in rainy season (September), when his bike skidded and he fell down on a water-logged road, where water had stagnated after a heavy rainfall. A high tension wire had broken from a nearby high tension pole (11000 KW), and came in contact with the abovementioned victim, who instantly was electrocuted (Fig. 1).

The autopsy revealed that the deceased was 165cm in length, average built and well-nourished male, with all his clothing mud stained and soaked with water at several areas (Fig. 2). Rigor mortis was fully developed all over the body and the postmortem lividity was present over back except pressure areas and was fixed (Fig. 3). On external examination, electric contact points were present obliquely over posterior aspect of right forearm over an area of 27 cm by 6 cm, back of right chest over an area of 10 cm by 2 cm and posterior aspect of left leg over an area of 8 cm by 2 cm (Fig. 4–6). Margins of all these injuries had shallow crater with ridges at the circumference. Base and floor of injuries were blackened, charred and pale at places. Periphery of the injuries was erythematous and peeled off at places. On internal examination, all internal organs were congested and the heart was cyanotic and rigid. The brain was mildly oedematous with congested vessels. Histopathological Examination of electric contact point showed elongation and streaming of nuclei with focal inter-epidermal and epidermal-dermal separation with coagulation changes (homogenization) and necrosis seen in dermis (Fig. 7). Brain showed focal areas and edema and few axonal bulbs predominantly in sub-meningeal areas. Lung showed autolytic changes, hemorrhagic areas and destruction of alveolar spaces (Fig. 8). Heart showed focal areas of deep eosinophilic changes with coalescence of myocardial fibres. The cause of death was opined as Shock due to Electrocution.



Fig. 1: Scene of Incidence

Case 2

A 38-year old male deceased was brought to the mortuary of JPNATC, AIIMS, New Delhi. The victim was a pedestrian, walking on the roadside nearby the bike rider and when he saw him fall down, then the latter went to help the fallen bike rider and accidentally he also came in contact with the same high tension wire which was broken from a pole and was in contact with water (Fig. 9).

The autopsy revealed that the deceased was 168 cm in length, average built and well-nourished male. All clothing was mud stained and soaked with water at several areas. Rigor mortis was fully developed and the postmortem lividity was present over back except pressure areas and was fixed (Fig. 10). On external examination, electric contact points were present obliquely over the body over left shoulder tip over an area of 14 cm by 8 cm, anterior aspect of neck over an area of 12 cm by 10 cm and antero-lateral aspect of right arm over an area of 18 cm by 4 cm (Fig. 11–13). Margins of the wound were shallow crater with ridges at its circumference. Base and floor of the injury were blackened, charred and pale at places. On internal examination, all the visceral organs were congested and stomach contained about 100 ml of semi-digested food particles. Histopathological Examination of Brain showed focal areas of gliosis, sub-meningeal edema; Liver showed focal fatty changes and mild focal chronic inflammatory infiltrates in portal triad; Lung showed autolytic changes, hemorrhagic areas and irregular alveolar spaces filled with fluid/ hemorrhage (Fig. 14); Heart showed focal overlapping/ coalescence of myocardial fibres and eosinophilic cytoplasm (Fig. 15). Electric contact point showed inter-epidermal and epidermal-dermal separation, coagulation, necrosis in epidermis, nuclear elongation in epidermis homogenization of dermis along with nuclear elongation in epithelium of hair follicle (Fig. 16). The cause of death was opined as Shock due to Electrocution.



Fig. 2: Deceased Bike rider

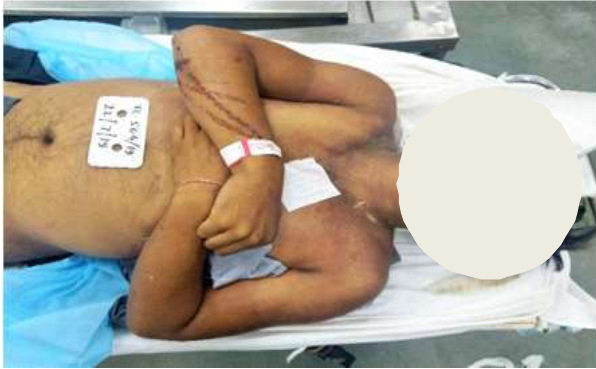

Fig. 3: External appearance of deceased.

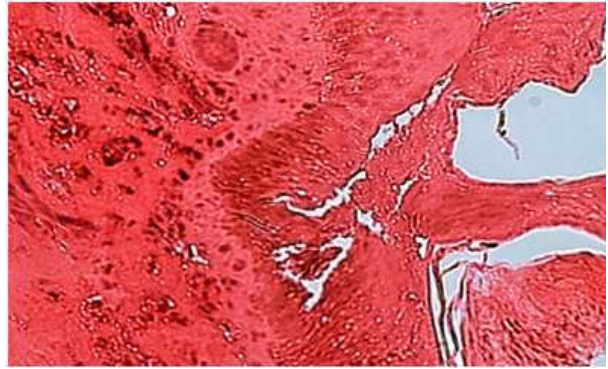


Fig. 7: Photomicrograph of Skin (HandE, 10 X) contact point showing inter-epidermal and epidermal-dermal separation, coagulation and necrosis in epidermis.

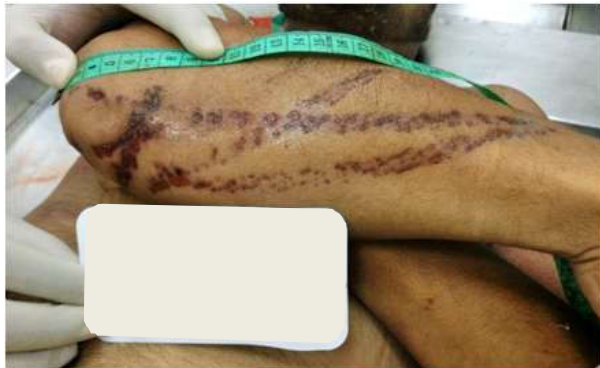

Fig. 4: Electrocutation Injury – right forearm.

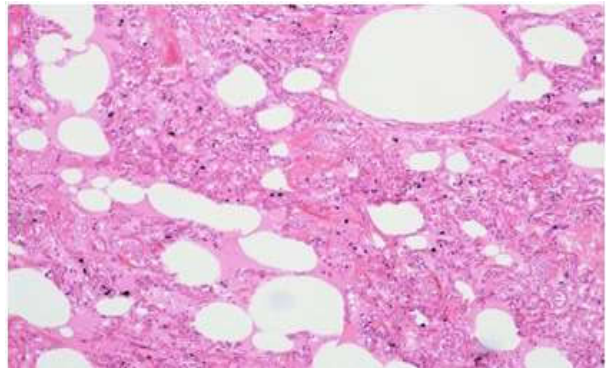


Fig. 8: Photomicrograph of Lung (HandE, 40X) showing the destruction of alveolar space.

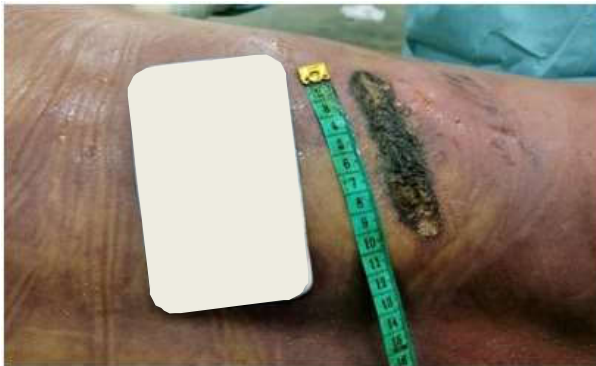

Fig. 5: Electrocutation Injury – back of right chest.



Fig. 9: Deceased pedestrian.

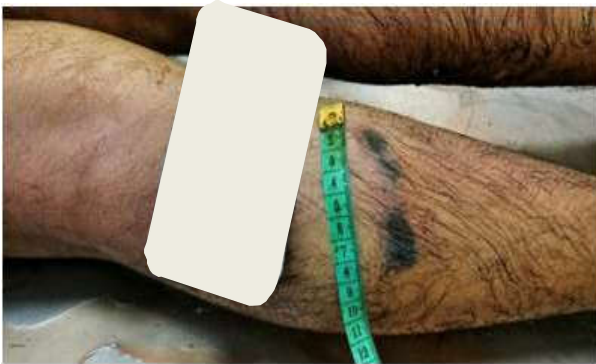

Fig. 6: Electrocutation Injury – back of left leg.

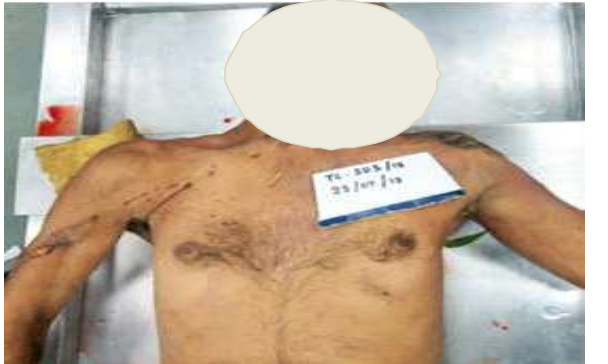

Fig. 10: External appearance of deceased.

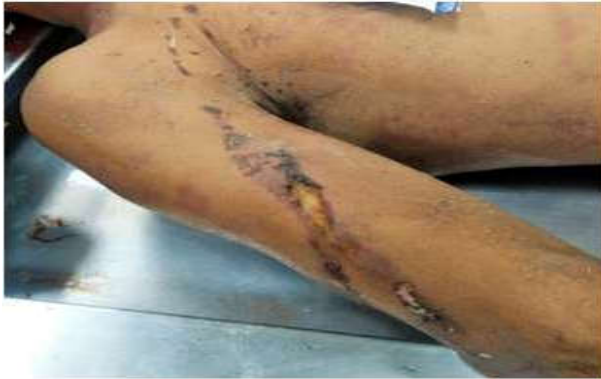

Fig. 11: Electrocution Injury – right arm.

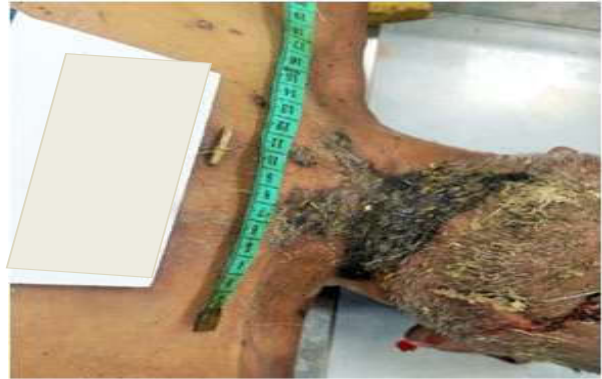

Fig. 12: Electrocution Injury – front of neck.

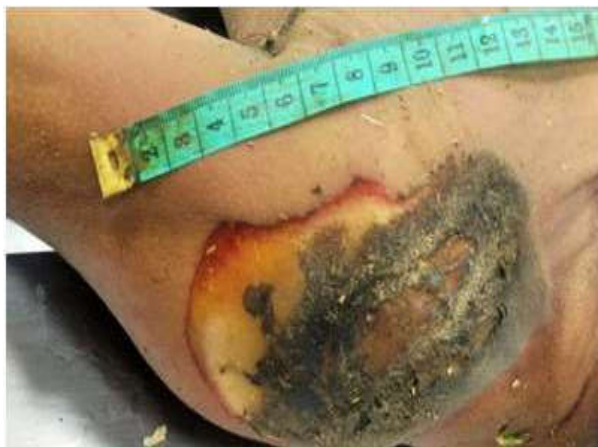

Fig. 13: Electrocution Injury – left shoulder.

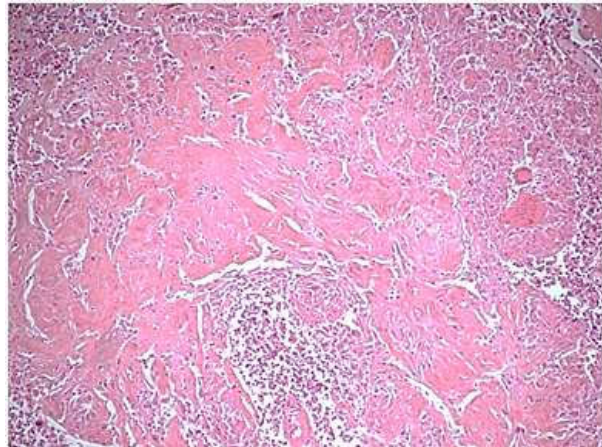


Fig. 14: Photomicrograph of Lung (HandE, 10X) showing autolytic changes, hemorrhagic areas and irregular alveolar spaces filled with fluid/hemorrhage.

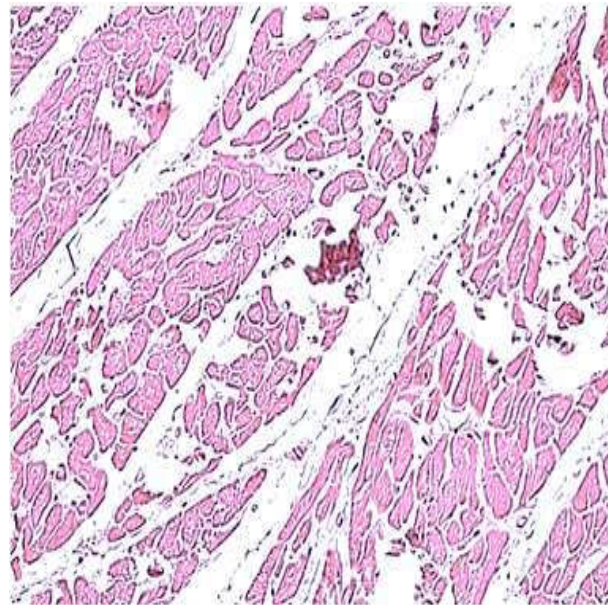


Fig. 15: Photomicrograph of Heart (H and E, 40X) showing focal areas of hyper-eosinophilic changes, overlapping myocardial fibers.

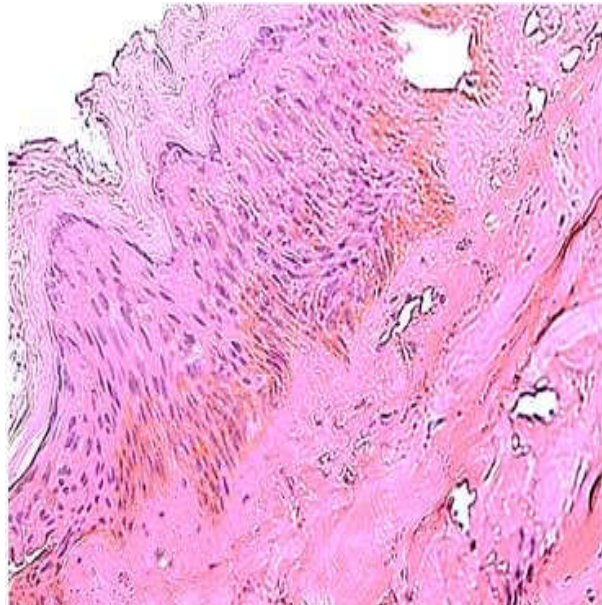


Fig. 16: Photomicrograph of Skin (HandE, 40X) Contact point showing nuclear elongation in epidermis, homogenization of dermis with nuclear elongation in epithelium of hair follicle.

Discussion

A detailed history of incident revealed that the bike rider skid and fell on water logged road in rainy season and came in contact with the high tension wire and was electrocuted. The second person tried to attend the bike driver and he came in contact with the same wire and died instantly. A study by Hussain et al.⁴ showed that high voltage electrocution accounts to 18–26% of deaths due to electric current and 40% of victims were aged between 21–40 years, to which both victims of present case also belonged. In their study, Pathak et al.⁵ observed that accidental incidences were typically higher in monsoon season (47.5%) as compared to other seasons, which shows that there is a characteristic seasonal variation in electrocution. Accidental electrocution may be encountered when an individual disregards warning signs or ignores the presence of high voltage cables when he is engaged in some activity near the cable.⁶ Diagnosis of high voltage electrocution is sometimes difficult in absence of history and circumstantial evidence, as pathognomonic features like electric marks and joule burns are often seen with low or medium voltage current involvement and also entry and exit marks are seen in 20% cases.⁷

Electrical burns occur due to the conversion of electric current to heat within the body, and this can be either entry or exit marks. According to the circumstantial evidence, both the deceased came in contact with the current wire that carries about 11000 KW from a pole and was in contact with water. Multiple electrical marks were identified during the autopsy of both the victim. Those marks showed characteristic appearance of dry, firm to hard craters with ragged edges along with 1st and 2nd degree burns also with flash effect over the back of the body. Histopathological examination of skin around the burnt area done with normal Haematoxylin and Eosin (H and E) staining showed characteristic sub-epidermal separation, nuclear streaming and partial separation of the dermis due to micro blisters. The skin over crocodile flash burns showed thinning with focal separation of epidermis with nuclear streaming, which was due to the cooking effect of tissues with the strong heat and the large vacuoles were also identified within epidermal layer. Elongated and tightly packed nucleus in the basal layer of epidermis causes streaming of the nuclei which give rise to nuclear palisading effect and by far it is the most characteristic histological feature seen in electrical

burns and are seen in majority of cases.⁸ In both the cases, all the above mentioned histological changes were present in the skin.

Electrical injuries leading to myocardial damage are either due to direct cellular damage or by inducing cardiac arrhythmias. Ventricular fibrillation is the most common mechanism of death identified in electrocution.⁹ Necrotic and fragmented myocardial cells with round or square shaped nuclei were seen in the microscopic section of heart, and this finding along with the absence of cellular reaction suggests an instantaneous death. This feature of myofibril breakdown was seen in 90% of cases in a study done by Fineschi et al.¹⁰ Cause of death in both the cases were opined as death due to electrocution and manner of death was accidental. There is lack of general public awareness regarding safety measures near electric poles and wires and also about the initial response to an electrocuted person. Hence, public should be made aware of basic preventive steps such as not to touch electrocuted person and not to attempt to give first aid and call for help in such circumstances. Roads should be better maintained, along with regular supervision of drainage system to avoid water logging on roads. Better maintenance of electric poles and wires and strict adherence to safety measures can reduce the fatality due to electrocution, which is mostly accidental and easily preventable.

Conclusion

The cases described in the article occurred as a result of electrocution due to broken high tension wire, along with poor drainage system of water which caused water logging on the road in rainy season. This present article focuses on need for proper development of water drainage system especially during rainy season and also to generate public awareness regarding regular supervision of roadside Electric poles and wires, which could prevent similar accidents. Insulating/isolating high tension electric wires would also reduce these instances. A detailed history regarding the incidence, scene visit, circumstantial evidence, statement of witness and proper postmortem examination with the histopathological examination are recommended prior to concluding the cause of death in case of alleged death due to electrocution. This article can be used for further planning and implementation of adequate measures to prevent accidents and thereby benefit the society.

Funding: None

Conflict of Interest: None declared

Reference:

1. Saukko P, Knight B. Knight's Forensic pathology. 3rd Ed London: Arnold. 2004;326.
2. Kishore K Sh, Rani S, Rakesh M M, et al. Accidental High Voltage Electrocution: Case Report. International Journal of Medical Toxicology and Forensic Medicine 2016;6(3): 188-90.
3. Kisner S, Casini V et al. Epidemiology of electrocution fatalities: 1998. In: Worker deaths by electrocution: A summary of NIOSH Surveillance and Investigative Findings. Washington, DC, Department of Health and Human Services (NIOSH), Publication No. 98-131:9-19.
4. Hussain IB, Khan MT et al. Related deaths due to electrocution: A comparative study. International Journal of Basic and Applied Medical Sciences. 2015;5(1):114-21.
5. Pathak AK, Disani NL et al. Pattern and seasonal variations in death due to electrocution: A retrospective study. Int J Med Sci Public Health. 2015; 4(1): 19-22.
6. Gupta BD, Mehta RA, Trangadia MM. Profile of Deaths due to Electrocution: A Retrospective Study. J Indian Acad Forensic Med. 2012;34(1): 13.
7. Kumar SS, Narayan AR, Gopal S, et al. High voltage electrical shock with multiple life threatening injuries. International journal of critical illness and injury science 2015 Oct;5(4):266.
8. Vishwakanth B, Shruthi P et al. Low voltage electrocution deaths and histopathological findings: One-year prospective autopsy study. J Curr Forensic Sci Res 2015;1(2):1-5.
9. Vij K. Textbook of Forensic Medicine and Toxicology. 5th edition. New Delhi: Elsevier; 2011:180.
10. Finesch V, Karch SB, D'Errico S, et al. "Cardiac pathology in death from electrocution." International journal of legal medicine. 2006;120(2): 79-82.

