

Abnormal Lumbarisation & Sacralisation: A Case Study on Dry Bones

Gokul Krishna Reddy Nune

How to cite this article:

Gokul Krishna Reddy Nune/Abnormal Lumbarisation & Sacralisation: A Case Study on Dry Bones/Indian J Anat. 2021;10(1):15-17.

Author's Affiliation: Assistant Professor, Dept. of Anatomy, NRI Academy of Medical Sciences, Mangalagiri, Andhra Pradesh 522503, India.

Corresponding Author: Gokul Krishna Reddy Nune, Assistant Professor, Dept. of Anatomy, NRI Academy of Medical Sciences, Mangalagiri, Andhra Pradesh 522503, India.

E-mail: gkr.nune@gmail.com

Abstract

The malformations of the sacrum which influence the free functioning of the spine go by the name of lumbarisation and sacralisation.¹ In human being sacrum is a solid bony mass formed from 5 fused vertebrae in the posterior part of bony pelvis on which the upright spine sits.² In foetus the segments of the sacrum were not fused, free to move like a tail and participate as an extension of the spine.^{1,2} Lumbarisation is a condition in which S1 vertebra is not fused & is free to move and participates along with lumbar vertebrae in spinal activity.^{1,2,3} Sacralisation of lumbar vertebrae is where (L5) segment is fused to the sacrum below.^{9,10}

In the present study examined 50 sacra which are available in the dept. of Anatomy, Nri medical college, mangalagiri for the lumbarisation and sacralisation.

Key words: Sacrum; Fifth lumbar vertebra; Sacralisation; Sacral foramina; Lumbarisation.

Introduction

The vertebral column protects the spinal cord and spinal nerves, supports transmits weight of the body to the lower limbs and thus plays an important role in posture and locomotion.^{1,2,3} Sacrum is a wedge shaped bone formed by the fusion of 5 sacral vertebrae which divided into base superiorly formed by the 1st sacral vertebra articulates with 5th lumbar vertebra, the caudal apex articulates with the coccyx.^{4,5} The anterior projecting border of 1st sacral vertebra called as sacral promontory. It has 4

pairs of pelvic sacral foramina communicates with the sacral canal. On dorsal surface, median sacral crest with 3 or 4 spinous tubercles representing fused sacral spines.⁵ Below the 4th tubercle an "U" shaped gap in the posterior wall of the sacral canal called sacral hiatus.⁵ There are four dorsal sacral foramina.

Transitional vertebrae in the lumbosacral region result as a congenital anomaly in the segmentation of the spine. Sacralisation means addition of sacral elements by the incorporation of lumbar vertebra mostly L5, can be unilateral/ bilateral producing partial/complete sacralisation.

The clinical significance of sacralisation of lumbar vertebra can cause L5 nerve compression resulting in pain along the sciatic nerve distribution.^{9,10} Spondylolisthesis is also a complication documented with sacralisation.

Reduction of sacral constituents is less common than the sacralisation but lumbarisation of first sacral vertebra does occur in some cases either partially or completely separate.^{6,7}

Materials and Methods

Total of 50 sacrum of both sex (male 30 & female 20) which are available in the dept. of Anatomy, kalinga institute of medical sciences Bhubhaneswar were studied for the lumbarisation and sacralisation, all the sacra were photographed.

Observations

Features	Complete	Incomplete	Incidence(%)
Lumbarisation	6	3	18
Sacralisation	1	2	6

Results

The sacra were examined to assess the number of its vertebral components and the number of sacral foramina was counted.

1. *Non-sacralisation*: sacrum which are showing 4 pairs of sacral foramina and 5 vertebral segments.
2. *Frank sacralisation*: sacrum which are showing 5 pairs of foramina and 6 vertebral segments.
3. *Occult sacralisation*: sacrum which are showing 6 vertebral segments and found to be set higher in the pelvis than usual, frank sacralisation was not seen.



Fig. 1: Sacrum Showing Sacralisation of Lumbar Vertebra Complete on Right & Incomplete on Left.



Fig. 2: Sacrum Showing Complete Sacralisation of Lumbar Vertebra.




Fig. 3: Sacrum Showing Incomplete Lumbarisation of Sacral(S1) Vertebra.



Fig. 4: Sacrum Showing Incomplete Lumbarisation of Sacral(S1) Vertebra.

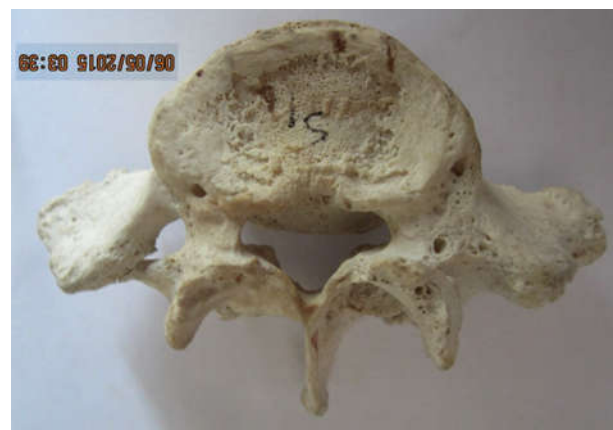


Fig. 5: First Sacral Vertebra.

Discussion

To understand sacralisation & lumbarisation the embryological origin of the lumbar vertebrae to be known, the development of which commences at 3rd week of intrauterine life from somites that form along the cranial-caudal axis, on either side of the notochord, from pre-somatic mesoderm.¹⁰ They differentiate into dermo-myotome & sclerotome. Each sclerotome divided into loosely packed cells cranially and densely packed cells caudally.¹⁰ Some of the densely packed cells move cranially opposite the centre of myotome where they form the intervertebral disc. The remaining densely packed cells in the caudal region of the cranial sclerotome fuse with the loosely arranged cells in the cranial end of immediately caudal sclerotome to form mesenchymal centrum.^{8,9} The mesenchymal cells surrounding the neural tube forms the neural arch.

The primary cause of sacralisation of the L5 vertebrae is likely to be a product of both genetic predisposition & developmental influences.^{5,6,7}

Complete sacralisation consists of a complete body union of the abnormal transverse process and the sacrum. Incomplete sacralisation shows a defined joint line. Both forms can be unilateral/ bilateral.

Clinical Importance

1. Usually presents with symptoms including spinal or radicular pain, disc degeneration, L4/L5 disc prolapse, lumbar scoliosis and lumbar extradural defects.^{1,2,6}
2. In transitional lumbosacral segmentation the intervertebral disc in this region is significantly narrowed & disc herniation is higher, occurs even at young ages.^{3,6,8}
3. The transitional vertebrae can increase degree of slippage in spondylolisthesis, this anomaly has known implications in the field of disc surgery.^{4,5}
4. It has been noticed that the discs immediately above & below the transitional vertebra were significantly more degenerative.^{9,10}

5. LSTV is one of the causative factors of low back pain.
6. Complications of sacralisation of 5th lumbar vertebra causes pain due to pressure on nerves or nerve trunks, ligamentous strain around the sacralisation, compression of soft tissues between bony joints.^{10,11}

References

1. Bron LJ, VanRoyan BJ and Wuisman P (2007). The clinical significance of lumbosacral transitional anomalies. *Acta ortopedica Belgica*. 73(6) 687-695.
2. Castellvi AE, Goldstein LA, Chan DPK (1983). Lumbosacral transitional vertebra and their relationship with lumbar extradural defects of Spine. 9(5) 493-495.
3. Frazer JE. (1958). *Anatomy of the human skeleton* 5th ed, edited by Breathnach ASJ and A (Churchill Livingstone London) 33-38.
4. Mahato NK. (2010). Morphological traits in sacra associated with complete and partial lumbarization of first sacral segment. *Spine* 10(10)910-915.
5. Malanga GA, Cook PM. (2004). Segmental anomaly leading to wrong level disc surgery in cauda equine syndrome. *Pain Physician* 7(1) 107-110.
6. Sharma VA, Sharma DK, Shukla CK. (2011). Osteogenic study of lumbosacral transitional vertebra in central India region. *Journal of Anatomical Society of India* 60(2)212-217.
7. Vergauwen S, Parizel PM, Van Breusegem L, VanGoethem JW, Nackaerts Y, Van den Hauwe Letal. (1997). Distribution and incidence of degenerative spine changes in patients with a lumbosacral transitional vertebra. *Eur Spine J.* 6(3):168-172.
8. Bonaiuti D, Faccenda I, Flores A (1997): Sacralisation of the 5th lumbar vertebra and backache: what's the possible relationship? *Med Lav.* 88(3): 226-236.
9. Southwood JD, Bersack SR (1950): Anomalies of the lumbosacral junction in 550 patients without symptoms referable to the low back. *AJR*, 64:624-634.
10. Khairnar KB, Rajale MB. (2013): Sacralisation of Lumbar Vertebrae. *Indian Journal of Basic & Applied Medical Research*; Issue-6, Vol.-2, P. 510-514.