

Study of Metopism Incidence in Adult Skulls of Karnataka

Drakshayini BK¹, Jayaprakash BR², Mallikarjun M³

How to cite this article:

Drakshayini BK, Jayaprakash BR, Mallikarjun M. Study of Metopism Incidence in Adult Skulls of Karnataka. Indian J Anat. 2020;9(2):138-141.

Author's Affiliation: ¹Assistant Professor, Department of Anatomy, Karnataka Institute of Medical Sciences, Hubballi, Karnataka 580032, India. ²Associate Professor, Department of Anatomy, Government Medical College, Nalgonda, Telangana 508001, India. ³Professor and Head, Department of Anatomy, Vijayanagar Institute of medical sciences, Ballari, Karnataka 583104, India

Corresponding Author: Jayaprakash BR, Associate Professor, Department of Anatomy, Government Medical College, Nalgonda, Telangana 508001, India.

E-mail: jayaprakash1805@gmail.com

Received 24.12.2019 | **Accepted** 02.03.2020

Abstract

Background: The persistence of complete metopic suture is called as metopism. The metopic suture is formed at the meeting of the two halves of the frontal bone, in the midline. The fusion of metopic suture starts normally in the second year of life and within a short duration, gets completely obliterated. The time of the closure of metopic suture varies from one to eight years and it can persist until adult age.

Aims and Objectives: To study the incidence of metopism and its clinical importance.

Materials and Methods: The present study was carried on 105 dry adult human skulls of both sexes obtained during routine undergraduate teaching. The skulls with complete Metopic suture were selected and studied.

Results: In the present study the incidence of complete Metopic suture is 2.85% (out of 105).

Conclusion: Awareness of the incidence of persistent metopic suture is important for anatomists, neurosurgeons, radiologists and forensic specialists.

Keywords: Adult skull; Metopic suture; Metopism; Frontal bone.

Introduction

The frontal bone forms the skeleton of forehead, articulating inferiorly with the nasal and zygomatic bones. In the fetal skull, the two halves of the frontal bone are separated by the frontal suture and

they remain separate until approximately 6 years of age. In some adults the separation line persists as the metopic suture in the midline of the glabella, the smooth, slightly depressed area between the superciliary arches.¹ The persistent complete metopic suture extending from the nasion to bregma is called metopism.² According to Romanes the metopic suture closes by the 5th or 6th year, leaving traces of it on the above and below.³ According to Hamilton the metopic suture disappears by 7th year.⁴ According to Warwick and Williams the metopic suture is usually obliterated by the 8th year.⁵ Incidence of metopism has geographical variations, it varies in different regions of India.⁶⁻⁸ A study by Dixit and Shukla in 1968 on Uttarpradesh skulls found incidence of metopism 2.53%.¹² Another study by Manalgiri et al. in 2010 on central Indian skulls found incidence of metopism 3.95%.¹⁷ Shanta Chandrasekaran (2011) studies showed 5% metopism in Tamilnadu Skulls¹⁸. Pankaj R et al. (2014) studies found 1.25% metopism in Maharashtra.²³ Metopic suture persistence is due to various causes such as abnormal growth of cranial bones, growth interruption, heredity, sexual, hormonal influence, atavism, cranial malformations and hydrocephalus.⁹

The knowledge about metopic suture is important for clinicians as it is easily mistaken as a fracture line of frontal bone or even for the sagittal suture in radiological images.^{6,10} It is also important for Paleodemography and Forensic medicine.

Aims and Objectives

The aims and objectives of the present study is to study the incidence of metopism in adult skulls of Karnataka and its clinical importance.

Materials and Methods

The present study was carried on 105 dry adult human skulls of both sexes obtained from the museum at Department of Anatomy, Vijayanagar Institute of Medical Sciences, Ballari (during 2012–2015). The skulls with complete metopic suture were selected and studied.

Results and Discussion

In the present study out of 105 dry adult human skulls of both sexes, 3 skulls showed the presence of complete metopic suture. The incidence of the metopism in the present study is 2.85%. Our results differ from other studies done in Karnataka region.^{15,20,27} Incidence of metopism in south India

ranges from 1.20%–6.25%. The results of present study are approximately similar to the study conducted by Dixit and Shukla (1968) which show 2.53% in Uttar Pradesh,¹² Agarwal et al. (1979) which show 2.66% in Kanpur⁸ and Chandrashekar et al. (1985) show 3.00% each in Maharashtra and South Indian respectively.¹³ And also similar to the study conducted by Sharada B Menasinakai et al. in 2019 on Karnataka skulls showed 3% metopism.²⁸ Das et al. (1973) observed metopism to be 3.31% in Uttar Pradesh⁷ and Hussain Saheb S (2010) observed metopism to be 3.20% South Indians.¹⁶ Complete metopic suture incidence reported in Indian adult skulls by various researchers are tabulated in (Table 1).

Minimum incidence of complete metopic suture was reported by Moula P Akbar Basha et al. (2015) in Indian skulls was 1.00%²⁶ and maximum incidence of complete metopic suture was reported by William F Masih et al. (2013) in Rajasthan (Indian skulls) was 6.50%.²⁵ Genetics play an important role in causing metopism.²⁹ The metopic suture closure impairment is common in Apert Syndrome.³⁰

Table 1. The incidence of complete metopic suture in various geographical regions of India as reported by various researchers

Study	Race/Region	Percentage
Rau (1934) ¹⁰	Dravidians of Madras	4.00
Jit and shah et al. (1948) ⁶	Indian (Punjabi)	5.00
Fakhruddin and Bhalerao (1967) ¹¹	Indian skulls	2.00
Dixit and Shukla (1968) ¹²	Indian (UP)	2.53
Das et al. (1973) ⁷	Indian (UP)	3.31
Agarwal et al. (1979) ⁸	Indian (Kanpur)	2.66
Chandrashekar et al. (1985) ¹³	South Indian	3.00
Anjoo yadav et al. (2007) ¹⁴	Indian skulls	3.50
Muralimanju B V et al. (2010) ¹⁵	Indian skulls	1.20
Hussain Saheb S (2010) ¹⁶	South Indian	3.20
Manalgiri et al. (2010) ¹⁷	Central India	3.95
Shanta Chandrasekaran (2011) ¹⁸	South India (Salem, Tamil nadu)	5.00
Gupta R et al. (2012) ¹⁹	Indian (UP)	5.00
K. Kalyan Chakravarthi ²⁰	South India n(Manipal-Karnataka, Krishna-Andhra Pradesh)	6.25
Neelima Pilli et al. (2013) ²¹	Indian (Andhra Pradesh)	5.00
William F Masih et al. (2013) ²²	Indian (Rajasthan)	6.50
Pankaj R et al. (2014) ²³	Indian (Maharashtra)	1.25
Rubi Saikia (2014) ²⁴	Indian (Assam)	3.17
T H Dilipkumar et al. (2014) ²⁵	Indian (Pondicherry)	2.00
Moula P. Akbar Basha et al. (2015) ²⁶	Indian (Andhra Pradesh)	1.00
Sangeetha V et al. (2018) ²⁷	South Indian (Karnataka, Tamilnadu)	5.71
Sharada B Menasinakai et al. (2019) ²⁸	Indian (Karnataka)	3.00
Present study (2019)	Indian (Karnataka)	2.85



Fig. 1: Showing total number 105 dry adult Human skulls of either sex.

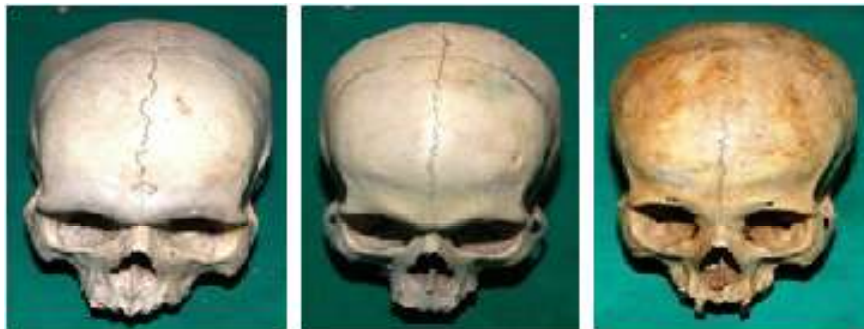


Fig. 2: Anterior view-showing complete Metopic suture in 3 dry adult human skulls.

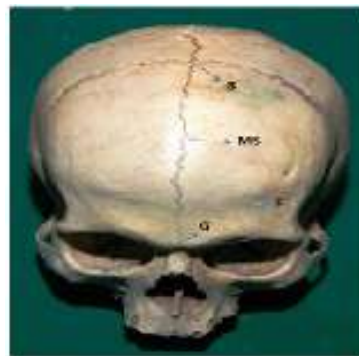

Fig. 3: Skull showing; B-Bregma, MS-Metopic suture, F-Frontal suture, G-Glabella.

Conclusion

The incidence of metopism in the present study is 2.85%. Incidence of metopic suture shows geographical variations after correlating the data available of earlier studies in India. Thus, incidence of metopism is higher in southern India, as can be correlated with other studies. Temperature and genetics appear to be significant factors, though further studies are needed to confirm the same. Knowledge of the metopic suture is important academically for anatomists, to avoid misdiagnosis

as a fracture by radiologists and orthopaedicians and also to the forensic experts while evaluating medico legal cases. The awareness of metopic suture is also important for neurosurgeons while doing frontal craniotomy.

References

1. Keith L. Moore, Arthur F. Dalley. Clinically oriented anatomy, 4th edition, Lippincott Williams & Wilkins publication: p.834.

2. Bryce TH. Osteology and anthropology in Quain elements of anatomy. 11th Ed. London 1915;4:177.
3. Romanes GJ. Cunningham's Textbook of Anatomy. 11th Ed. Oxford University, London 1972.pp.133.
4. Hamilton W.J. Textbook of Human Anatomy, Macmillan & Co., London. 2nd edition 1976. pp.60.
5. Warwick R. and Williams P.L. Gray's Anatomy. 36th ed., London; Longmans p.334.
6. Jit I & Shah MA. Incidence of frontal or metopic suture amongst Punjabi adults. Indian. Medical Gazette 1948;83:507.
7. Das AC, Saxena RC, & Beg MAQ. Incidence of metopic suture in U.P. subjects. Journal of the Anatomical Society of India 1973;22:140.
8. Agarwal SK, Malhotra VK and Tiwari SP. Incidence of the metopic suture in adult Indian crania. Acta Anat; 1979;105:p.469-74.
9. Del Sol M, Binvignat O, Bolini PDA, & Prates JC. Metopismo no indivíduo brasileiro. Rev. Paul. Med 1989;107(2):105-07.
10. Rau RK. Skull showing absence of coronal suture. J. Anat. London 1934;69:109-12.
11. Fakhruddin S and Bhalerao UK. Interparietal bone in three pieces, a case report. J of Anat Soc of India 1967;16;146-47.
12. Dixit CS, Shukla PL. Metopicsutures in human crania J. Anat. Soc. India 1968;17:47.
13. Chandrasekharan P. Identification of skull from its suture pattern. Forensic science International 1985;27:205-14.
14. Yadav A, Kumar V, Srivastava RK. Study of metopic suture in the adult human skulls of North India. J. Anat. Soc. India 2010;59(2):232-36.
15. Murlimanju BV, Latha V Prabhu, Mangala M. et al. Median Frontal Sutures - Incidence, Morphology and Their Surgical, Radiological Importance. Turkish Neurosurgery 2011;21(4):489-93.
16. Hussain Saheb S, Mavishettar GF, Thomas ST, et al. Incidence of metopic suture in adult south Indian skulls. J Biomed Sci Res 2010;2:223-6.
17. Manalgiri AS, Satpathi DK, Razvi R, et al. Study of metopism in skulls of central India. Indian Journal of Forensic Medicine Toxicology 2010;4(1):74-77.
18. Chandrasekaran S, Shastri D. A Study on Metopic Suture. International Journal of Basic Medical Science 2011;1:379-82.
19. Gupta R, Usman N, Zaidi SHH. A study of Metopic suture in Adult Indian Skulls. National Journal of integrated research in medicine 2012;3:82-83.
20. Chakravarthi KK, Nelluri V. Morphological study of metopicsuture in adult south Indian skulls. Int J of Med & Health Sci 2012;1(2):23-28.
21. Pilli N, Sunder RR. Persistent metopic suture in various forms in south Indian adult skulls- A study. IJSRP 2013;3(5):1-7.
22. Masih WF, Gupta S, Saraswat PK, et al. Autopsy study of metopic suture incidence in human skulls in western Rajasthan. National Journal of medical research 2013;3(1):63-65.
23. Wadekar PR, Pundge SJ, Fulpatil MP, Pandit SV. Study of incidence of metopic suture in adult skulls. Indian J Basic Appl Med Res. 2014;4(1):277-83.
24. Rubi Saikia. A study on metopic suture in cadaveric skulls of Assamese people. Journal of Evolution of Medical and Dental Sciences 2014;3(44):10910-914.
25. Dilip Kumar TH, Rajasekar SS. Metopic suture and its variations. Indian Journal of Basic and Applied Medical Research 2014;3(4):42-45.
26. Akbar Basha MP, Sugavasi R. Study of metopic suture in south Indian skulls, Int J Res Med Sci 2015 Sep;3(9):2237-39.
27. Sangeetha V, Sundar G. Morphology of metopic suture and its clinical significance in human adult skull, Int J Anat Var 2018;11(2):40-42.
28. Menasinakai SB, Vidya HK, Koti MN. Study of metopic suture, Int J Anat Res 2019;7(2.1):6341-44.
29. Castilho SMA, Oda YJ, Santana GDM: Metopism in adult skulls from Southern Brazil. Int J Morphol 2006;24:61-66.
30. Faro C, Chaoui R, Wegrzyn P, et al. Metopic suture in fetuses with Apert syndrome at 22-27 weeks of gestation. Ultrasound Obstet Gynecol 2006;27:28-33.