

A Study of Histopathological Changes in Fallopian Tubes in Ectopic Pregnancy

Dharmendra singh¹, Shilpa Ulhas Vahikar², Shaila Kumari Mitra³,
Kanchan Srivastava⁴, Reeta Singh⁵, Kiriti Kanaujia⁶

How to cite this article:

Dharmendra singh, Shilpa Ulhas Vahikar, Shaila Kumari Mitra, *et al.* / A study of histopathological changes in fallopian tubes in ectopic pregnancy / Indian Journal of Pathology: Research and Practice 2023;12(2) 49-54.

Abstract

Context: Ectopic pregnancy is defined as any pregnancy in which fertilized ovum implants outside the uterus. Commonest site is fallopian tubes (90-95%), majority in the ampulla or isthmic portions and the major cause of maternal mortality and morbidity in first trimester of pregnancy.

Aims: To study the histopathological changes in fallopian tube in ectopic pregnancy and correlate the changes with age group, parity and to recognise the pre disposing risk factors such as acute and chronic salpingitis, salpingitis isthmica nodosa, granulomas and other related findings.

Settings and Design: This study was conducted on resected specimens of fallopian tube/tubal mass of ectopic pregnancy received in the department of pathology, B.R.D. Medical College, Gorakhpur.

Methods and Material: Each fallopian tube was inspected grossly for products of conception and length was noted and sectioned at 3-5 mm intervals and fixed in 10% formalin. Sections were stained with H & E stain and examined microscopically.

Statistical analysis used: Prospective cross-sectional

Results: Total 100 cases were studied, 98% were of tubal ectopic in which ampullary in 66.33% cases. Age of patients ranged from 19-44 years with mean age 24.4 years. Maximum 69% cases were of 21-30 years, 59% of rural areas, 76% Hindu, 56% of low socio-economic status, 31% with parity two, 69.18% involve right tube, 60.2% were ruptured tube. Commonest trophoblastic infiltration was stage III (38.8%).

Conclusions: Histopathology plays a crucial role in confirming ectopic pregnancy and identification of risk factors. Commonest risk factors were pelvic inflammatory disease in 28% and abortion in 10% cases. Chronic salpingitis was in 46.05% and acute salpingitis in 23.68% cases.

Author Affiliation: ¹Junior Resident, ^{2,4}Professor, ³Professor and Head, ⁵Associate Professor, Department of Obstetrics and Gynecology, ⁶Assistant Professor, Department of Pathology, Baba Raghav Das Medical College, Gorakhpur, Uttar Pradesh 273013, India.

Corresponding Author: Dharmendra Singh, Junior Resident, Department of Pathology, Baba Raghav Das Medical College, Gorakhpur, Uttar Pradesh 273013, India.

E-mail: sdharmendra99@gmail.com

Received on: 17.02.2023 **Accepted on:** 31.03.2023

Keywords: Histopathology; Ectopic pregnancy; Fallopian tube; Chorionic villi.

Key Messages: Histopathology plays a crucial role in confirming ectopic pregnancy and identification of risk factors. Early diagnosis of ectopic pregnancy can prevent rupture and unruptured ectopic pregnancy can be treated conservatively.

INTRODUCTION

Ectopic pregnancy is defined as any intra or extra uterine pregnancy in which the fertilized ovum implants at an aberrant site outside the uterus.¹ Ectopic pregnancy is the major cause of maternal mortality and morbidity in first trimester of pregnancy especially in developing countries where the majority of patients present late with rupture and hemodynamic compromise.² Aims and objective were to study the histopathological changes in fallopian tube in ectopic pregnancy and correlate the changes with age group, parity and to recognise the predisposing risk factors such as acute and chronic salpingitis, salpingitis isthmica nodosa, granulomas and other related findings.

MATERIAL & METHODS

This prospective cross-sectional study has been conducted on all the resected specimens of fallopian tube/tubal mass with a clinical diagnosis of ectopic tubal pregnancy received in the Department of Pathology, B.R.D. Medical College Gorakhpur for histopathological examination during a period from July 2021 to June 2022. All samples of patient of ectopic tubal pregnancy were selected on the basis of inclusion and exclusion criteria. A complete analysis regarding age, parity, gestational age, associated risk factors, clinical presentation, diagnostic tools used, treatment options and associated risk of morbidity and mortality has been made. Gross examination of the fallopian tube was done post-operatively and length of each fallopian tube has been noted and inspected for products of conception and other related findings. Ectopic pregnancy tubal tissue were fixed in 10% formalin solution and subjected to histopathological examination using paraffin embedding technique. Thin section of 2-3 micron thickness was cut by microtome from paraffin blocks. Sections were stained with H & E stain and examined thoroughly microscopically. The pathological findings have been correlated with clinical data like age, parity, associated medical conditions, previous surgeries and pregnancies and the results have been tabulated using percentage. A p value < 0.05 will be considered to be statistically significant.

RESULTS

In our study a total 100 specimens of ectopic pregnancy were studied microscopically during one year duration. Age of patients ranged from

19-44 years with mean age of 24.4 years. The maximum number of cases i.e. 38 cases (38%) were in the age group of 21-25 years followed by 31 cases (31%) in the age group of 26-30 years. Maximum 59 cases (59%) were of rural areas followed by 41 cases (41%) of urban areas. Majority of cases i.e. 76 cases (76%) were Hindu followed by Muslim in 18 cases (18%) and in others 6 cases (6%). Maximum 56 cases (56%) were belong to low socio-economic status followed by 36 cases (36%) of medium socio-economic status and only 8 cases (8%) were of high socio-economic status. Maximum 31 cases (31%) were with parity 2, followed by 26 cases (26%) with parity 0 (Nulliparous) and 22 cases (22%) with parity one. Maximum 98 cases (98%) were tubal and only 2 cases (2%) were of extra tubal ectopic pregnancy. The most common site of tubal ectopic pregnancy was ampulla in 65 cases (66.33%) followed by isthmus in 24 cases (24.49%), fimbriae in 6 cases (6.12%) and interstitial in 3 cases (3.06%). Right side fallopian tube was more commonly involved (59.18%) than left fallopian tube (40.82%). Maximum 59 cases (60.20%) were ruptured tube and 39 cases (39.80%) were unruptured tube at time of presentation. Maximum 57 cases (57%) presenting at ≤ 7 weeks and 43 cases (43%) at > 7 weeks of gestation. The most common presenting symptom was abdominal pain present in 96 cases (96%) followed by amenorrhea in 84 cases (84%), bleeding per vagina/spotting in 70 cases (70%), syncope/fainting in 32 cases (32%), nausea/vomiting in 26 cases (26%) and adnexal mass in 20 cases (20%). The most common presenting sign was abdominal tenderness in 82 cases (82%) followed by cervical tenderness in 71 cases (71%), fornix tenderness in 54 cases (54%), pallor in 52 cases (52%), shock in 26 cases (26%) and tachycardia in 25 cases (25%). Most common predisposing risk factor was pelvic inflammatory disease or sexually transmitted disease in 28 cases (28%), no any risk factor in 27 cases (27%), previous abortion/medical termination of pregnancy/dilatation and curettage in 10 cases (10%), previous ectopic pregnancy in 6 cases (6%), previous caesarean section in 7 cases (7%), history of infertility and its treatments in 5 cases (5%), history of previous tubal surgery in 6 cases (6%), uses of intrauterine contraceptive device in 5 cases (5%) and uses of oral contraceptive pills in 6 cases (6%). Most common pathological changes was chronic salpingitis seen in 35 cases (46.05%) followed by acute salpingitis in 18 cases (23.68%), salpingitis isthmica nodosa in 7 cases (9.22%), sclerotic vessel in 6 cases (7.89%), calcification in 5 cases (6.58%), walthard cell nest

in 4 cases (5.26%) and granulomatous/tubercular salpingitis in 1 case (1.32%). Most common stage of trophoblastic infiltration was stage III in 38 cases (38.8%) followed by stage II in 31 cases (31.6%) and stage I in 29 cases (29.6%). Patients with stage I trophoblastic infiltration have lower level of serum β -hCG (average 1620 mIU/ml) compare to stage II trophoblastic infiltration in which serum β -hCG was higher (average 4468 mIU/ml and stage III trophoblastic infiltration in which serum β -hCG level was highest (average 11956 mIU/ml). (p value < 0.00001). In late presented cases 82.14% have ruptured tube and in early presented cases most of cases (81.82%) were unruptured tube. (p value < 0.00001).

Table 1: Age wise distribution of cases of ectopic pregnancy

Age group (in years)	Number of cases	Percentage (%)
<20	4	4
21-25	38	38
26-30	31	31
31-35	18	18
36-40	7	7
> 40	2	2
Total	100	100

Table 2: Tubal ruptured status and its relation to time of presentation (N=98)

Tubal ruptured status	Early presentation (at < 6 weeks)	Late presentation (at > 6 weeks)	χ^2	p-value
Ruptured cases	10 (23.8%)	49 (87.5%)	40.635	< 0.00001
Unruptured cases	32 (76.2%)	7 (12.5%)		
Total	42 (100%)	56 (100%)		

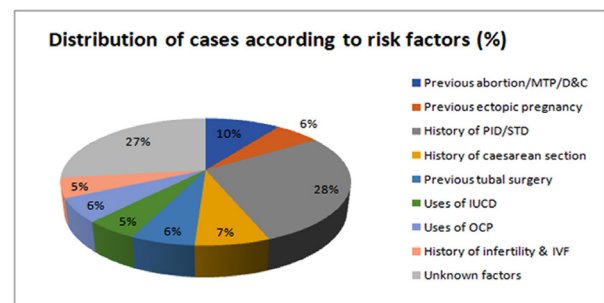
Table 3: Ultrasonographic findings and ruptured status of fallopian tube in tubal ectopic pregnancy (N=56)

Ultrasonographic findings	Ruptured tube Number (%)	Unruptured tube Number (%)	χ^2	p-value
Empty uterus + adnexal masses	4 (9.52%)	11 (78.57%)	26.317	< 0.00001
Empty uterus + free fluid in pouch of douglas	10 (23.81%)	2 (14.29%)		
Empty uterus + free fluid in pouch of douglas + adnexal masses	28 (66.67%)	1 (7.14%)		
Total	42 (100%)	14 (100%)		

Table 4: Distribution of cases according to risk factors

Predisposing risk factors	Number of cases	Percentage (%)
Previous abortion/MTP/D & C	10	10
Previous ectopic pregnancy	6	6
History of PID/STD	28	28
History of caesarean section	7	7
Previous tubal surgery	6	6
Uses of IUCD	5	5
Uses of OCP	6	6
History of infertility & IVF	5	5
Unknown factors	27	27
Total	100	100

Graph



Abbreviations:

- MTP - Medical Termination Of Pregnancy
- D & C - Dilatation And Curettage
- PID - Pelvic Inflammatory Disease
- STD - Sexually Transmitted Disease
- IUCD - Intrauterine Contraceptive Device
- OCP - Oral Contraceptive Pills

Table 5: Stages of trophoblastic infiltration and its correlation with β -hCG level (N=98)

Trophoblastic infiltration	Number of cases (%)	Serum β -hCG level (mIU/ml)	χ^2	p-value
Stage I	29 (29.6%)	1620 (355-5250)		
Stage II	31 (31.6%)	4468 (550-16650)	58.560	< 0.00001
Stage III	38 (38.8%)	11956 (2150-52500)		

Abbreviations: hCG -human chorionic gonadotropin
mIU/ml - mili International Unit/ millilitre.

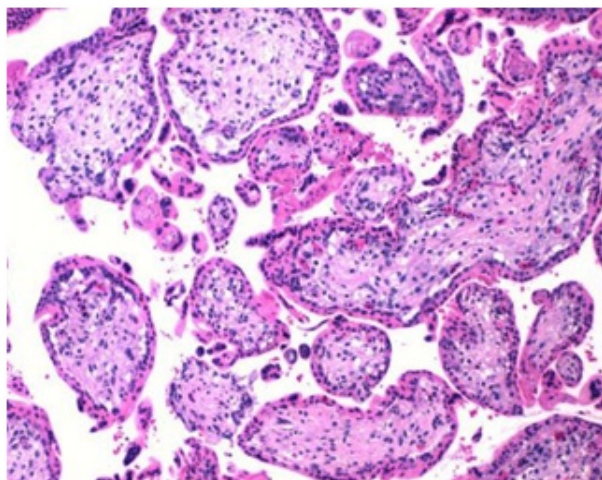


Fig. 1: Ectopic pregnancy figure showing numerous chorionic villi lined by double layers of cells inner cytotrophoblast and outer syncytiotrophoblast. (H & E x10x)

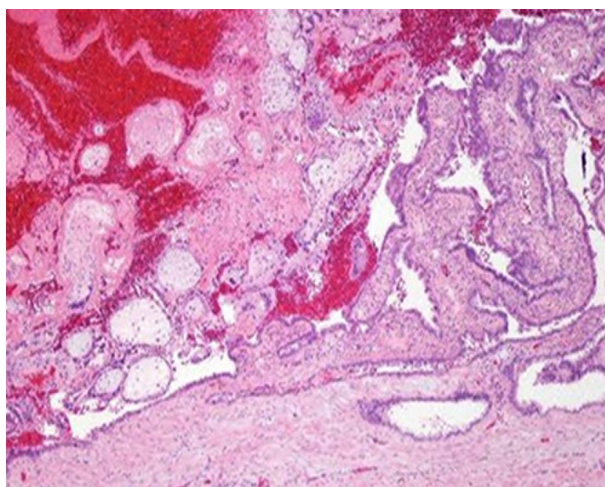


Fig. 2: Ectopic tubal pregnancy - stage I trophoblastic infiltration [villi in mucosa](H & E x10x)

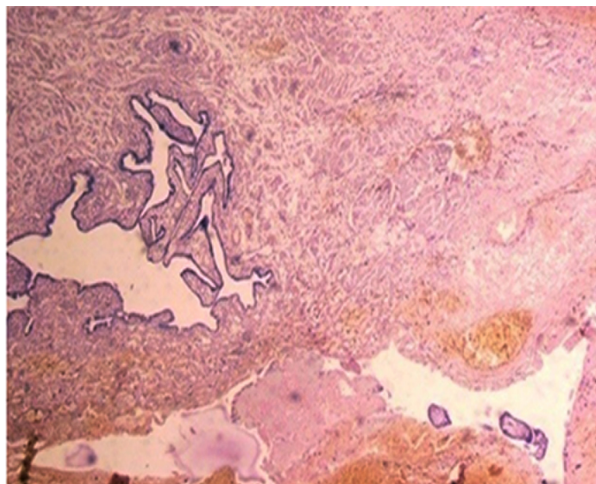


Fig. 3: Ectopic tubal pregnancy stage II trophoblastic infiltration [villi in muscles] (H & E x10x)

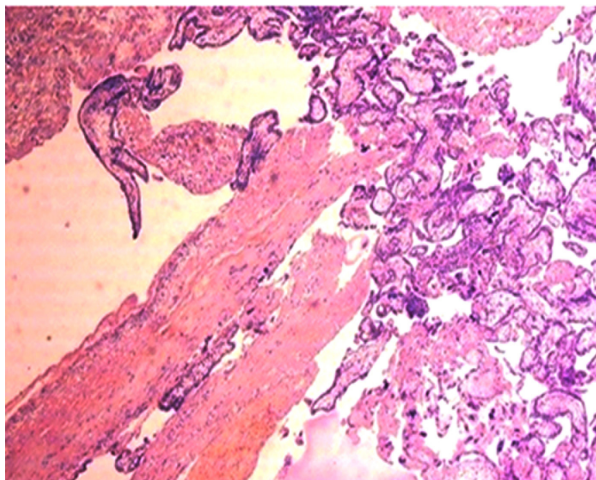


Fig. 4: Ectopic tubal pregnancy - stage III trophoblastic infiltration [villi reaching upto serosa] (H & E x 10X)

DISCUSSION

The most common site for ectopic pregnancy is fallopian tubes (90-95%), majority occur in the ampulla or isthmica portions of the fallopian tubes. About 2-3% occurs as interstitial ectopic pregnancies.³ There are many predisposing factors of ectopic pregnancy, chronic salpingitis being the most common one. Others include acute salpingitis, salpingitis isthmica nodosa (SIN), tuberculosis, endometriosis, previous ectopic pregnancy, treatment for infertility, previous abortion,¹ pelvic inflammatory disease.⁴

In our study, most common age group of presentation of ectopic pregnancy was 21-25 years, in 38 cases (38%) and 26-30 years in 31 cases (31%). Priti S. Vyas et al⁵ also reported similar presentation

of that was 21-25 years in 39.3% cases, 26-30 years in 35.7% cases. In our study, most of the cases of ectopic pregnancy were of low socioeconomic status in 56 cases (56%). Mamata S. *et al*⁶ also reported similar finding that 57% cases were of low socioeconomic status. In our study, maximum number of cases was with parity two in 31 cases (31%), followed by nulliparous (parity zero) in 26 cases (26%) and with parity one in 22 cases (22%). Mamata S. *et al*⁶ also reported similar finding that parity two in 33.3% cases followed by 31.9% cases in nulliparous women and 18.1% cases with parity one. In our study, ampulla of fallopian tube was most common site of tubal ectopic pregnancy in 65 cases (66.3%). Anuradha M. *et al*⁷ also reported similar that tubal ectopic pregnancy in ampulla in 61.97% cases. In our study, right side fallopian tube involvement in 58 cases (59.2%) similar to Mo. Irshad A. *et al*⁸ who reported right side tube involvement in 59.1% cases. In our study, patients presented as ruptured tube in 59 cases (61.2%) similar to Anuradha M. *et al*⁷ that as ruptured tube in 61.6% cases. In our study in late presented cases 87.5% have ruptured tube compare to early presented cases in which only 23.8% cases were ruptured tube. In early presented cases 76.2% were unruptured tube compare to late presented cases in which only 12.5% cases were unruptured tube. Qudisia Qazi *et al*⁹ also reported that in late presented cases 97.73% have ruptured tube compare to early presented cases in which only 16.67% cases were ruptured tube. In early presented cases 83.33% were unruptured tube compare to late presented cases in which only 2.27% cases were unruptured tube. In our study most of the cases (66.67%) with ruptured tube had empty uterus with free fluid in pouch of douglas and adnexal masses on ultrasonographic finding while most of the cases (78.57%) with unruptured tube had empty uterus with adnexal masses on ultra sonographic finding. Empty uterus with free fluid in pouch of douglas had seen in 23.81% of ruptured cases and 14.29% of unruptured cases of tubal ectopic pregnancy. Qudisia Qazi *et al*⁹ also reported similar finding that most of the cases (66.67%) with ruptured tube had empty uterus with free fluid in pouch of douglas and adnexal masses on ultrasonographic finding while in unruptured tube 50% cases had empty uterus with adnexal masses and 5% cases had empty uterus with free fluid in pouch of douglas on ultrasonographic finding. In our study maximum 34 cases (34%) presenting at 6 weeks of gestation similar to Neelima Govanda *et al*¹⁰ who also reported maximum 35.8% cases presented at 6 weeks of gestation. In our study, most common presenting

symptom was abdominal pain in 96 cases (96%), followed by amenorrhea in 84 cases (84%), bleeding per vagina or spotting in 70 cases (70%). Divyesh *et al*¹¹ also reported that most common symptoms was abdominal pain in 98.3% cases followed by amenorrhea in 85% cases, bleeding per vagina or spotting in 68.3% cases. In our study, most common presenting sign was abdominal tenderness in 82 cases (82%) followed by cervical tenderness in 71 cases (71%), forniceal tenderness in 54 cases (54%), pallor in 52 cases (52%). Mamata S. *et al*⁶ reported that most common presenting sign was pallor in 86.1% cases that was higher than our study, followed by abdominal tenderness in 83.3% cases, cervical tenderness in 65.3%, forniceal tenderness in 52.8% cases. In our study, most common predisposing risk factors for ectopic pregnancy was pelvic inflammatory disease or sexually transmitted disease in 28 cases (28%) followed by unknown factors in 27 cases (27%) and history of previous abortion /MTP/D & C in 10 cases (10%). Prasanna B. *et al*¹² also reported that PID/STD as most common predisposing risk factor in 26% cases followed by unknown factors in 20% and history of previous abortion /MTP/D & C in 16% cases. In our study, chronic salpingitis was most common associated pathological finding in 35 cases (46.05%) followed by acute salpingitis in 18 cases (23.68%) and Salpingitis isthmica nodosa in 7 cases (9.22%). Archana B. *et al*¹³ also reported similar finding that chronic salpingitis was most common associated pathological finding in 40.9% cases followed by acute salpingitis in 27.3% cases and Salpingitis isthmica nodosa in 22.7% cases. In our study, most common stage of trophoblastic infiltration was stage III in 38 cases (38.8%) followed by stage II in 31 cases (31.6%) and stage I in 29 cases (29.6%). F. R. Cabar *et al*¹⁴ also reported most common stage of trophoblastic infiltration was stage III in 46 cases (43.8%) followed by stage II in 30 cases (28.6%) and stage I in 29 cases (27.6%). In our study patients with stage I trophoblastic infiltration have lower level of serum β -hCG (average 1620 mIU/ml) compare to stage II trophoblastic infiltration in which serum β -hCG was higher (average 4468 mIU/ml) and stage III trophoblastic infiltration in which serum β -hCG level was highest (average 11956 mIU/ml). F. R. Caber *et al*¹⁴ also reported similar finding that patients with stage I trophoblastic infiltration have lower level of serum β -hCG (average 1553 mIU/ml) compare to stage II trophoblastic infiltration in which serum β -hCG was higher (average 4586 mIU/ml) and stage III trophoblastic infiltration in which serum β -hCG level was highest (average 12607 mIU/ml).

CONCLUSION

Histopathology plays a crucial role in confirming ectopic pregnancy and identification of risk factors. Early diagnosis of ectopic pregnancy can prevent rupture and unruptured ectopic pregnancy can be treated conservatively. It's a life threatening condition occurring in women all over the world which could be prevented by early diagnosis of ectopic pregnancy by studying its risk factors, associated morphological and radiological findings.

ACKNOWLEDGEMENT

I am grateful to my senior resident Deval B. Dubey, my batchmates Manoj Prajapati, Shaikat Ali for their assistance and the staff of Pathology Mr. Rajkumar Yadav, Mr. Ravindra for their much needed co-operation in timely processing of sections and slide preparation.

REFERENCES

1. Dama S, Kamat A. A clinical study of ectopic pregnancy in a tertiary care centre in Hubli. *International Journal of Reproduction, Contraception, Obstetrics and Gynecology*. 2017 Apr 1;6(4):1566-70.
2. Panti A, Ikechukwu N, Lukman O, Yakubu A, Egondu S, Tanko B. Ectopic pregnancy at Usmanu Danfodiyo University Teaching Hospital Sokoto: A ten year review. *Annals of Nigerian Medicine*. 2012 Jul 1;6(2):87.
3. Sharma P, Bishnoi R. Histopathological changes in ectopic tubal pregnancy. *Volume-7 | Issue-2 | February-2018 | Print ISSN No 2277 - 8179*.
4. Levin AA, Schoenbaum SC, Stubblefield PG, Zimicki S, Monson RR, Ryan KJ. Ectopic pregnancy and prior induced abortion. *American Journal of Public Health*. 1982 Mar;72(3):253-6.
5. Vyas PS, Vaidya P. Epidemiology, Diagnosis and Management of Ectopic pregnancy. *Research Articles*. 1998:1-1.
6. Soren M, Patnaik R, Sarangi BK. A clinical study on ectopic pregnancy. *Int J Res Med Sci*. 2017 Nov;5(11):4776-82.
7. Murugesan A, Prabhu K, Muthulakshmi M. A retrospective study of ectopic pregnancies in a tertiary care hospital. *International Journal of Reproduction, Contraception, Obstetrics and Gynecology*. 2016 Aug 1;5(8):2537-41.
8. Ahmed MI, Begum Z. A Study on Histopathological Findings in Ectopic Tubal Pregnancies and Evaluation of Associated Risk Factors. *Indian Journal of Pathology: Research and Practice*. 2018;7(8):928.
9. Qazi Q, Akhtar Z, Khan K. Clinical presentations and complications associated with tubal rupture in patients with tubal ectopic pregnancy. *Journal of Postgraduate Medical Institute*. 2010;24(4).
10. Govada N, Konkay K, Pola N, Chaganti PD, Yarra CC, Karri MD. Clinical and Histopathological Findings of Ectopic Pregnancy Cases- A Retrospective Study from a Tertiary Care Hospital, Andhra Pradesh, India. *National Journal of Laboratory Medicine*. 2022 Jul, Vol-11(3): PO31-PO35.
11. Panchal D, Vaishnav G, Solanki K. Study of management in patient with ectopic pregnancy. *Infection*. 2011;33:55.
12. Prasanna B, Jhansi CB, Swathi K, Shaik MV. A study on risk factors and clinical presentation of ectopic pregnancy in women attending a tertiary care centre. *IAIM*, 2016; 3(1): 90-96.
13. Bembde AS, Bindu SM, Bhale CP. Clinico-pathological study of tubal ectopic gestation and evaluation of associated risk factors in a tertiary center. *Ann Pathol Lab Med*. 2019;6:348-51.
14. Cabar FR, Pereira PP, Schultz R, Zugaib M. Predictive factors of trophoblastic invasion into the ampullary region of the tubal wall in ectopic pregnancy. *Human Reproduction*. 2006 Sep 1;21(9):2426-31.

