

**Author Affiliation:**

\*Associate Professor ,\*\*Senior Resident, Department of Urology, Yenepoya Medical College, Derlakatte, Mangalore – 575017 Karnataka.

**Reprint Request:**

**NischithD'souza**, Associate Professor, Department of Urology, Yenepoya Medical College, Derlakatte, Mangalore – 575017 Karnataka.  
E-mail: nish25@gmail.com

## Primary Carcinoid Tumor of Urinary Bladder: A Rare Case Report and Literature Review

**Nischith D'souza\***, **Ashish Verma\*\***, **Rahul Bhargava\*\***

**Abstract**

Carcinoid tumors are known to arise from enterochromaffin cells and are usually found arising from tissue derived from the embryonicneural crest. Although they are more commonly encountered in gastrointestinal and respiratory organs, rarely they have also been encountered in the genitourinary tract, including the kidney and urinary bladder. Only 29 cases of pure carcinoid tumor of bladder have been reported so far in the literature.

We report here another case of pure carcinoid tumor of bladder involving the prostatic urethra and whole of the prostate, who underwent radical cystectomy.

**Keywords:** Primary Carcinoid Tumor; Bladder Carcinoid; Malignant Bladder Carcinoid; Pure Carcinoid of Bladder.

**Introduction**

Carcinoid tumors commonly occur in gastrointestinal tract and respiratory tract, but carcinoid tumors of the genitourinary system like kidney, urinary bladder, prostate and urethra have also been reported. About 29 cases of primary bladder carcinoid have been reported so far in the literature [1-3]. Carcinoid tumors arise from enterochromaffin cells and arise from tissue derived from embryonicneural crest. These cells are also known as enterochromaffin cells or amine precursor uptake and decarboxylation (APUD) cells.

There are various theories proposed regarding the origin of these carcinoid tumors like origin frommetaplastic bladder urothelium, or presence of enterochromaffin cells in bladder, or arise from neural crest tissue entrapped within the metanephros during embryogenesis, or that they

represent metastases from an occult carcinoid tumor elsewhere in the body [4].

In this report, we describe the clinical, histopathologic, and immunophenotypic features of a pure carcinoid tumor of the urinary bladder and review the literature.

**Case Report**

A 54 year old male was referred to our out-patient departmentwith a history of haematuria since the past 4 months, with passage of clots and intermittent pain during that period. He was a smoker in the past and had no exposure to aniline dyes. He had no significant medical history. His physical examination was normal. He had already undergone CT-Urogram which showed a polypoidal lesion in the right posterolateral wall involving the right

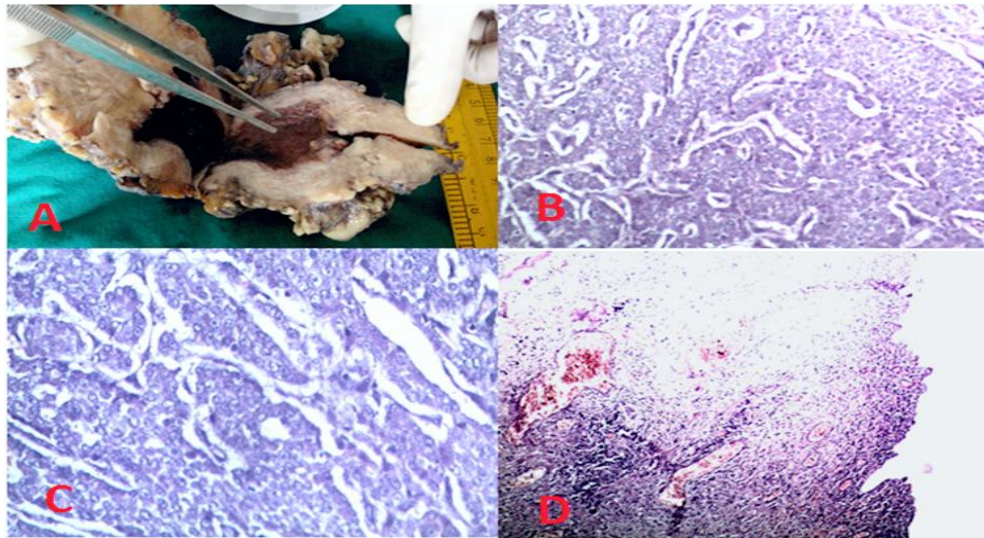
vesicoureteric junction causing right sided hydronephrosis. Also, he had undergone cystoscopy, which revealed a 4cm lesion in the right posterolateral wall and trigone. Biopsy was taken from that lesion and the histopathological report was transitional cell carcinoma of the urinary bladder (GRADE 3). So, he was referred to our hospital for further management.

In view of these findings, radical cystoprostatectomy and dissection of internal iliac group of nodes with ileal conduit was done. The histopathology report was as follows:

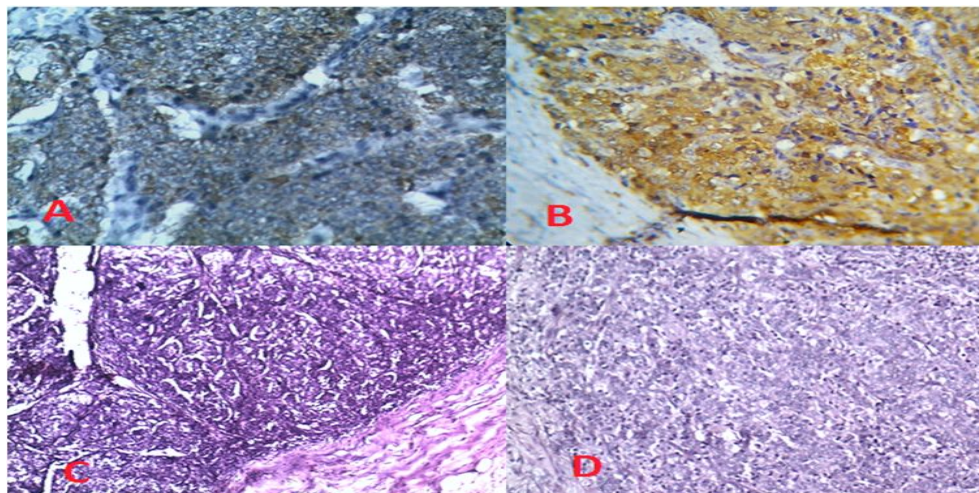
- Grossly, it was ulceroproliferative growth in the lower wall of the bladder close to the prostatic urethra measuring 3x2 cms. Tumor was infiltrating into the prostatic urethra and prostate. There was diffuse thickening of entire wall of bladder more in the lower part.

(Figure 1A).

- Microscopically, tumor showed ulcerated mucosa with tumor cells arranged in nesting pattern. Tumor cells were small, monotonous and round, with round, bland nuclei with stippled chromatin and indistinct nucleoli. The nests were separated by septae of vascular tissue (Figure 1B, 1C). Tumor showed muscle invasion and serosa, vascular and perineural invasion. Also, the whole of the prostate was replaced by tumor cells and the tumor extended into the prostatic urethra (Figure 2D). And there was involvement of iliac group of lymph nodes with vessels filled with tumor emboli (Figure 2C).
- Immunohistochemistry study was strongly positive for Neuron Specific Enolase (NSE) (Figure 2B) and Cytokeratin (Figure 2A).



**Fig. 1:** A-Radical cystectomy specimen cut open to reveal the tumor, B- Monotonous cells arranged in nesting pattern separated by fibrous septae (40X), C- High power view (100X), D- Cystitis with ulceration.



**Fig. 2:** A-Cytokeratin expression in the tumor, B- Neuron specific enolase expression in the tumor, C- Lymph node showing secondaries, D- Prostatic urethra showing tumor invasion

Thus, it was a carcinoid tumor of the bladder. And as there was no evidence of carcinoid tumors in any other organs, we concluded that this was a case of primary carcinoid tumor of the bladder with invasive nature. There was no element of transitional cell carcinoma found in the specimen.

## Discussion

Neuroendocrine tumors comprise of 1.7% of all bladder tumors [1]. As per the Travis classification, they can be classified into low-grade carcinoid tumors, and high-grade small-cell and large-cell carcinomas [2]. Among these, small cell carcinomas are the most common, with only 29 cases of pure bladder carcinoids reported so far in the literature.

Carcinoid tumors have a variety of growth patterns. On the basis of architecture, they can be classified as insular, trabecular, glandular, undifferentiated, and mixed [5]. Primary bladder carcinoid lesions are mostly seen over trigone or bladder neck and can coexist with other malignancies of bladder as well as inflammatory diseases of the bladder. Usually carcinoid tumours are present submucosally and on cystoscopy appear as polypoid lesions. In all reported cases neuroendocrine differentiation has been readily confirmed by presence of argyrophilic granules or by immunohistochemistry, which reveals presence of chromogranin, synaptophysin, neuron-specific enolase or other markers of neuroendocrine differentiation. Though carcinoids are slow growing tumors, about 75% of patients have local, distant and/or nodal metastasis at the time of diagnosis [4,6]. Our patient too, had tumor metastasis to the prostate, prostatic urethra and iliac lymph nodes.

As these are very rare tumors, much is not known about their progression and response to various treatment modalities or their long term management. For localized carcinoid tumors of the urinary bladder, a variety of treatments have been tried: a multiple biopsy, transurethral resection, a partial cystectomy, and a total cystectomy or radical cystoprostatectomy depending upon the size of tumor and extent of disease. Many of the reported tumors were small and so were cured by transurethral resection [1].

Not much is known about treatment for metastatic disease, owing to rarity of these tumors. Based upon the studies on neuroendocrine tumors in other parts of the body, two chemotherapy regimens have been recommended: methotrexate, vinblastine, adriamycin, and cisplatin (MVAC) for mixed type

and cisplatin-etoposide for pure neuroendocrine tumors [7]. But the overall prognosis of bladder neuroendocrine tumors remains poor, with a 2-year survival rate of 13%, mostly based on a series of small-cell carcinomas [7].

In view of lack of long term follow-up studies for bladder carcinoids as a consequence of paucity of pure carcinoids cases, the behaviour of these tumors is largely unknown and difficult to predict. Though, size and extent of the lesions usually appear to be most important, and also flow cytometric analysis of DNA ploidy may provide additional prognostic information [8], but nothing can be said conclusively. Mixed carcinoid tumors usually exhibit more aggressive behavior, in line with that expected of the noncarcinoid component [4].

In bladder carcinoids, carcinoid syndrome is not seen due to the fact that the peptides are flushed out of the system in the urine and are not absorbed in the systemic circulation in enough quantities so as to cause symptoms, exception being in cases of metastasis giving rise to large tumour burden, extensive nodal metastasis, or tumours with direct access to systemic circulation.

## References

1. Chang YS, Lin VCH, Lin KJ, Shen YY. Carcinoid Tumor of the Urinary Bladder: Case Report and Literature Review. *JTUA*. 2007; 18: 154-6.
2. Chen YB, Epstein JI. Primary carcinoid tumors of the urinary bladder and prostatic urethra: a clinicopathologic study of 6 cases. *Am J Surg Pathol*. 2011;35(3):442-6. DOI: 10.1097/PAS.0b013e318208f96a.
3. Sugihara A, Kajio K, Yoshimoto T, Tsujimura T, Iwasaki T, Yamada N, et al. Primary carcinoid tumor of the urinary bladder. *Int Urol Neph*. 2002; 33(1): 53-57.
4. Murali R, Kneale K, Lalak N, and Delprado W. Carcinoid Tumors of the Urinary Tract and Prostate. *Arch Pathol Lab Med*. 2006; 130(11): 1693-1706.
5. Martignoni G, Eble JN. Carcinoid Tumors of the Urinary Bladder: Immunohistochemical Study of 2 Cases and Review of Literature. *Arch Pathol Lab Med*. 2003; 127: e22-e24.
6. Lal A, Chen H. Treatment of advanced carcinoid tumors. *Curr Opin Oncol*. 2006; 18: 9-15.
7. Manunta A, Vincendeau S, Kiriakou G, Lobel B, Guillp F. Non-transitional cell bladder carcinomas. *BJU Int*. 2005; 95: 497-502.
8. Walker BF, Someren A, Kennedy JC, Nicholas EM. Primary carcinoid tumor of the urinary bladder. *Arch Pathol Lab Med*. 1992; 116: 1217-1220.