

## Study on the Nutrient Foramen of Long Bones of Upper Limb

Chakka Sreekanth<sup>1</sup>, Lattupalli Hema<sup>2</sup>

### How to cite this article:

Chakka Sreekanth, Lattupalli Hema. Study on the Nutrient Foramen of Long Bones of Upper Limb. Indian J Anat. 2020;9(1):9-15

**Author's Affiliation:** <sup>1</sup>Associate Professor, Department of Anatomy, Sri Padmavathi Medical College For Women (SVIMS) Tirupathi, Andhra Pradesh 517507, India. <sup>2</sup>Professor and Head, Department of Anatomy, Narayana Medical College, Nellore Andhra Pradesh 524004, India.

**Corresponding Author:** Lattupalli Hema, Professor and Head, Department of Anatomy, Narayana Medical College, Nellore Andhra Pradesh 524004, India.

**E-mail:** hemakarra06@gmail.com

**Received** 17.10.2019 | **Accepted** 13.11.2019

### Abstract

The success of any transplant lies in the surgeons ability to preserve its vascular supply and its rapid reconstruction, especially in free vascularized bone grafts, which preserve viability of osteocytes, act as a space filler and introduce a new vascular bed for the reconstruction of defects following trauma, tumour resection, congenital pseudoarthrosis and any cases of difficult non-union bones.

*Aims and Objectives:* The aim of the present study is to:

1. To determine the number and position of the nutrient foramina in the upper and lower limb long bones.
2. To determine the location and direction of nutrient canal.
3. To determine whether the nutrient foramina obey the general rule that is directed away from the growing end of long bone.

*Materials and Methods:* The present study is carried out on 150 human cleaned and dried bones of the Upper limb. The samples were taken from Narayana Medical College, Chinthareddypalem, Nellore and Sri Venkata Padmavathi College (SVIMS), Tirupathi of Andhra Pradesh. The long bones included for the study was as follows: Humeri – 50, Radii – 50, Ulnae – 50. All the bones that were taken for the study were normal and had no pathological changes were present. The age and the sex of the bone were unknown. In all these bones after determining the side of bone, the “Nutrient Foramen” were studied in regards with:

1. The number of foramina on the shaft of the bone;

2. Surface on which it was located;
3. Direction from growing end;
4. Location in relation with length of the shaft.

*Observations and Results:* Total 150 long bones of upper limb of right and left side of unknown age and sex were taken for the study. The parameters studied were depending on the number of nutrient foramina, direction of foramina and their distribution at various levels. The results and observations of the study are presented as tables.

*Conclusions:* Importance of nutrient foramen is relevant to fracture treatment. Combined periosteal and medullary blood supply to the bone cortex helps to explain the success of nailing of long bones fractures particularly in the weight bearing like femur and tibia uses of vascularized fibula bone in bony defects due to trauma. Currently, the detailed study of blood supply to long bone is a determining factor for the success of newer techniques and resection in orthopedics.

**Keywords:** Nutrient foramina; Nutrient artery; Humerus; Radius; Ulna bones.

### Introduction

The nutrient artery is the principal source of the blood to along bone particularly during its growth period in the embryo and fetus as well as during early phases of ossification (Lewis, 1956)<sup>8</sup>; Patake and Mysorekar, 1977<sup>10</sup>; Forriol Compos et al., 1987<sup>4</sup> during childhood, long bones receive about 80% of the interosseous blood supply from the nutrient arteries, and in the case of their absence, the vascularization occurs through the periosteal

vessels (Trueta, 1953).<sup>12</sup> Because the artery of the shaft of the long bone is largest it is called the "Nutrient Artery". Nutrient canal typically becomes slanted during the growth, the direction of slant from surface to marrow cavity point towards the end that has grown least rapidly. This is due to greater longitudinal growth at the faster growing end, hence the derivation of the axiom that foramina "seek the elbow and flee from the knee". Bones are structures that adapt to their mechanical environment, and from the fetal age adapt to a naturally occurring holes. The holes or nutrient foramina, allow blood vessel to pass through the bone cortex (Gotzen et al., 2003)<sup>5</sup> The cavities conducting the blood vessels and peripheral nerves on the surface of shaft of long bones are called as "Nutrient Foramen". The role of nutrient foramen is evident from the term "Nutrient" itself. The nutrient foramina has been studied in the past by Havers (1691)<sup>2</sup>, Berard (1835)<sup>2</sup>; Schwalbe (1876)<sup>11</sup>, Langer (1876).<sup>7</sup>

The location of nutrient foramen is important in longitudinal stress fractures, as they can either initiate from the nutrient foramina or the supero medial aspect: Longitudinal stress fractures are more commonly associated with tibia, but occasionally occur in femur, fibula and patella (Craig et al., (2003).<sup>1</sup> Clinical fracture of a long bone is usually accompanied by the rupture of the nutrient artery with variable disruption of the peripheral vessels associated with periosteal detachment. Following fracture the ruptured nutrient artery and the periosteal vessels, together with those in the adjacent soft tissue, start bleeding (Trueta, 1974).<sup>12</sup> An understanding of the location and the number of the nutrient foramina in long bones is, therefore, important in orthopedic surgical procedures such as joint replacement therapy, fracture repair bone grafts and vascularized bone microsurgery as well as medico legal cases (Trueta, 1974)<sup>12</sup>; Forriol Campos et al., 1978).<sup>4</sup>

Detailed data on the blood supply to long bones and the association with the areas of bone supplied has been, and continues to be, a major factor in the development of new transplantation and resection techniques in orthopedics (Kirschner et al., 1998)<sup>6</sup> However, there is still a need for a greater understanding of the location and number of nutrient foramen in bones such as Humerus, Radius and ulna. By defining this restricted area of "Nutrient Artery" entering into the nutrient canal, surgeons can void that during surgical operations and thereby prevent damage to nutrient artery and minimize or lessen the chances of non-union of fracture of the bone.

### ***Aim and Objectives***

The aim of the present study is to:

1. To determine the number and position of the nutrient foramina in the upper and lower limb long bones;
2. To determine the location and direction of nutrient canal;
3. To determine whether the nutrient foramina obey the general rule that is directed away from the growing end of long bone.

### **Materials and Methods**

The present study is carried out on 150 human cleaned and dried bones of the Upper limb. The samples were taken from Narayana Medical College, Chinthareddypalem, Nellore and Sri Venkata Padmavathi Medical College, under (SVIMS) of Andhra Pradesh. The long bones included for the study was as follows:

Humeri - 50,

Radii - 50,

Ulnae - 50.

All the bones that were taken for the study were normal and had no pathological changes were present. The age and the sex of the bone were unknown. In all these bones after determining the side of bone, the "Nutrient Foramen" were studied in regards with

1. The number of foramina on the shaft of the bone;
2. Surface on which it was located;
3. Direction from growing end;
4. Location in relation with length of the shaft.

Nutrient foramina were distinguished by the presence of a well-marked groove leading to the foramen, and by a well-marked often slightly raised edge of the foramen at the commencement of the canal. In doubtful cases a dissecting microscope was used to locate the foramen. For direction of canal fine stiff wire was passed through the foramen to confirm its direction. The size of nutrient foramen was determined by using hypodermic needle No. 20 and 24. (Hidustan Syringes and Dispovan pvt. Ltd.).

Large foramen - accepted the No. 20 needle;

Medium foramen - accepted only the No. 24 needle;

Small foramen - did not take No. 24 needle.

When more than one foramen was present, the larger one was considered Dominant (DF), and nutrient foramina smaller than a size 24 hypodermic needle were considered as being secondary nutrient foramina (SF)

*Humerus:* The distance between the superior aspect of the head and the most distal aspect of the trochlea.

*Radius:* The distance between the most proximal aspect of the head of radius and tip of the radial Styloid process.

*Ulna:* The distance between the most proximal aspect of the olecranon and the ulna Subdivisions of the position of the Foramina according to Foramen Index.

The position of the foramina was divided into three types according to the Foramen Index(FI) as follows:

Styloid process Type 1: FI up to 33.33, the foramen was in the proximal third of the bone;

Type 2: FI from 33.33 up to 66.66, the foramen was in the middle third of the bone;

Type 3: FI above 66.66 the foramen was in the distal third of the bone.

All measurements were taken to the nearest 0.1mm using a digital verniercaliper. The results were analyzed and tabulated using the Statistical Package for the Social Sciences (SPSS) 8.0 windows. The range, mean and standard deviation of Foramina Index were determined.

## Results

Total 150 long bones of upper limb of right and left side of unknown age and sex were taken for the study. The parameters studied were depending on the number of nutrient foramina, direction of foramina and their distribution at various levels. The observations of the study are presented as tables.

*Humerus:* Out of 50 bones 26 humeri belong to right side and 24 to left. Total numbers of nutrient foramina were 60. Single foramina were found in 3. (72%), double nutrient foramina in 12 bones (24%) and no nutrient foramina in 2 bones (4%). The average length of the humeri was 315.1 mm and average distance of nutrient foramina from upper end was 169.68 mm. Most of the nutrient foramina were found in the middle 1/3<sup>rd</sup> i.e., 55 foramina (92%), rest of the foramina occupies 1/3<sup>rd</sup> i.e., 4 (6%) and only one foramina in upper 1/3<sup>rd</sup> (2%). All nutrient foramina are directed

towards the elbow i.e., away from the growing end. Anatomical situation of the nutrient foramina on the shaft at large is on the anteromedial surface; out of 60 foramina 39 (67.2%) were on this surface, 11 (19%) of them were on posterior surface, 7 (12%) on medial border and 1.7% on the lateral surface.

*Radius:* Out of 50 bones 25 radii belong to right side and 25 radii belong to left side. Total number of nutrient foramina was 52. Single foramen were found in 46 bones (92%), double in 3 bones (6%) and absent in 1 bone (1%). The average length of the radius was 250.3 mm and average distance of nutrient foramina from the upper end was 85.7 mm. Most of the nutrient foramina were found in middle 1/3<sup>rd</sup> in 32 (61.5%), rest of the foramina occupies upper 1/3<sup>rd</sup> 29 (38.5%). Among 52 foramina only one is directed towards growing end and others away from the growing end. Anatomical situation of foramen on the shaft of radius at large is on the anterior surface; out of 52 foramina 37 (72.2%) were on this surface, 6 (11.5%) foramina were on the anterior border, 6 (11.5%) foramina were on the interosseous border and only 2 (4.8%) foramina were on posterior border.

*Ulna:* Out of 50 ulnae studied 25 ulnae belong to right side and 25 ulnae belong to left side. Total number of nutrient foramina was 50. Single foramen was observed in all 50 bones (100%). The average length of the radius was 264.7 mm and average distance of nutrient foramina from the upper end was 91.1 mm. Most of the nutrient foramina were found in upper 1/3<sup>rd</sup> in 29 (58%), 21 middle 1/3<sup>rd</sup> 29 (42%). One nutrient foramen is directed towards growing end and remaining 49 were directed away from the growing end i.e., towards the upper end (Elbow joint). Anatomical situation of foramen on the shaft of ulna mostly is on the anterior surface; out of 50 foramina 35 (70%) were on this surface, 10 (20%) foramina were on the anterior border and remaining 5 foramina were on interosseous border (10%). None of the ulna showed multiple foramina.

## Discussion

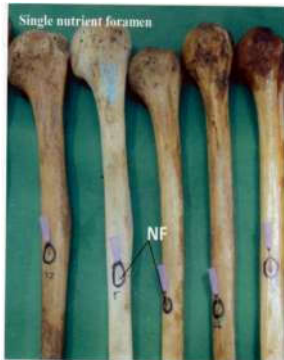
### *Number of Nutrient Foramina*

In the present study, a single nutrient foramen has a higher percentage (72%) in the humeral bones, compared to that of double (24%) and triple foramina (0%) and no nutrient foramina in 2 bones (4%) respectively is shown in (Table 1 and Figs. 1,2). Present result (Lutken, 1950)<sup>9</sup>; (Mysorekar, 1957): Forriol Campos et al., 1987)<sup>4,10</sup> Other studies

reported a higher percentage of a single nutrient foramen (80–88%) (Kizilkant et al., 2007).<sup>3</sup> The range of occurrence of double foramina varied from 13% to 42% (Mysorekar, 1967).<sup>10</sup> According to Kizilkant (2007), the percentage of occurrence of triple foramina in the humeri did not exceed (1–7%). The latter observations were in accordance to those reported in the present study. Moreover, Kizilkant et al., (2007)<sup>3</sup> reported the presence of four nutrient foramina in (1%) of the humeri studied. Such number was not observed in the present study. On the other hand, the absence of nutrient foramina in some humeri were also reported by other authors (Lutken, 1950; Patake et al., 1977; Kizilkant et al., 2007)<sup>9,10,3</sup> stated that in such cases, the periosteal vessels were entirely responsible for the blood supply of the bone.

**Table 1:** Number of nutrient foramina observed in long bones of upper limb

Bone	Number of Bones	Number of Foramina	Percentages (%)
Humerus (n = 50)	36	01	72%
	12	02	24%
	02	00	04%
Radius (n = 50)	46	01	92%
	03	02	06%
	01	00	01%
Ulna (n = 50)	50	01	100%



**Fig. 1:** Single nutrient foramen



**Fig. 2:** Double nutrient foramina

In the present study, all the radii examined had (92%) single nutrient foramen, double nutrient foramen in (6%) of bones, and no nutrient foramen in (1%) bone. The same finding was reported by Forriol Campos et al., (1987).<sup>4</sup> In other studies, the majority of radii (more than 90%) were found to possess a single nutrient foramen (Mysorekar, 1967; Kizilkant et al., 2007).<sup>3</sup> In such studies, radii possessing double nutrient foramina were also observed, and reported the absence of nutrient foramina in (1.2%) of radii examined.

In the present study, (100%) of ulnae examined had a single nutrient foramen. Who recorded a single nutrient foramen in all specimens examined, other authors reported a single nutrient foramen in more than 91% of ulnae (Mysorekar, 1967; Forriol Campos et al., 1987; Kizilkant et al.).<sup>10,4,3</sup> Furthermore, observed three nutrient foramina in (1%) of ulnae examined, while Mysorekar (1967)<sup>10</sup> reported the absence of nutrient foramina in (0.6%) and (1.1%) of ulnae respectively.

### Position of Nutrient Foramina

In this study, Table 2 shows 92% of the nutrient foramina were located along the whole middle third of the humerus, with the foramen index ranging between 33% and 68.68% of the bone length. In accordance with the present results, previous studies reported the position of the nutrient foramina within the middle third of the bone (Mysorekar, 1967; Forriol Campos et al., 1987; Kizilkant et al., 2007).<sup>10,4,3</sup> In this study, (67.2%) of all humeral nutrient foramina were observed on the anteromedial surface 19% of them were in the posterior surface (1.7%) on the lateral surface and 12% on the medial border of the bone. Similar findings had been reported by Forriol Campos et al., (1987) and Kizilkant et al., (2007).<sup>4,3</sup> On the other hand, Mysorekar (1967)<sup>10</sup> reported an equal percentage of foramina on both the anteromedial surface and the medial border. The site of entrance of the main artery into the humerus makes it vulnerable to be damaged in cases of exposure and plating of the medial column in Supracondylar fractures of the humerus. So, it had been advocated to plating these fractures both medially and laterally with fixation extending up to the diaphysis.

In the present study, as shown in Fig. 3 and 4, 61.5% of the total nutrient foramina were distributed most often in the middle third of the radius and 38.5% were in the proximal third, with the foramen index ranging between 27.82% and 48.57% of the bone length. The ratios of the present study were close to those reported by Mysorekar

**Table 2:** Position and number of Dominant Foramina (DF) and Secondary Nutrient Foramina (SF) observed in Humerus

Position	Total Number of Foramina	%	Number of Foramina					
			Single		Two		Three	
			DF	SF	DF	SF	DF	SFA
<b>Anteromedial surface</b>		67.2%	29		9	1	–	–
Posterior surface	11	19.0%	2		3	6	–	–
Lateral surface	01	1.7%	–	–		1	–	–
Medial border	07	12.1%	5	–		4	–	–

(1967)<sup>10</sup> who found 62% of foramina located in the middle third of the bone and 36% in the proximal end. On the other hand, some reports such as those of Shulman (1959), Forriol Campos et al. (1987)<sup>4</sup>, Kizilkanat et al. (2007)<sup>3</sup> stated that the majority of nutrient foramina were located in the proximal third of the bone.

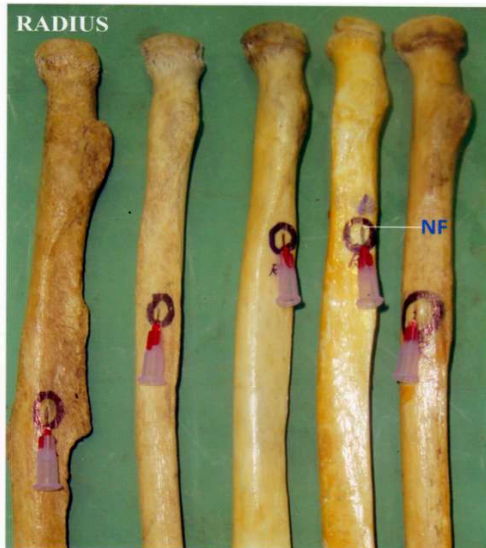

Fig. 3: Radius

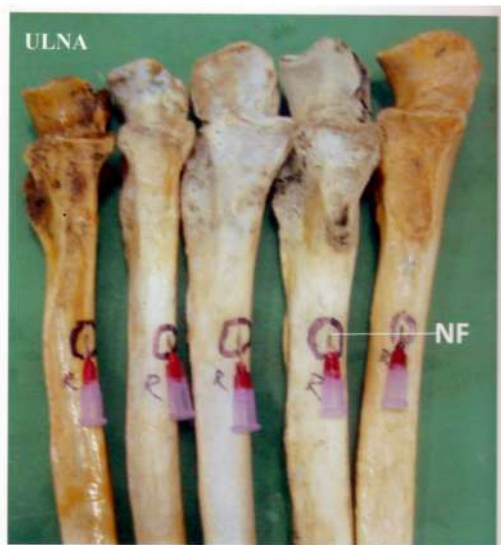

Fig. 4: Ulna Bones

In the present study, 72.2% of all radial foramina were on the anterior surface, of the bone. Such results were in accordance with the previous studies (Mysorekar, 1967; Forriol Campos et al., 1987)<sup>10,4</sup> who stated that the majority of nutrient foramina were located on the anterior surface of the bone.

Regarding the ulna, the nutrient foramina (42%) were in the middle third while majority 58% were in the proximal third of the bone, with the foramen index ranging between 27 and 47.59% of the bone length. No nutrient foramina were detected in the distal third of the ulnae. Reviewing the literatures, some authors reported that the majority of nutrient foramina were located in the middle third (Mysorekar, 1967)<sup>10</sup> while others stated that most of foramina were in the proximal third. However, all authors agreed that there were no nutrient foramina in the distal third of the ulna.

In the present study, 70% of the nutrient foamina were located on the anterior surface of the ulnae. In all previous studies, and in accordance with the present results, the nutrient foramina were mostly observed on the anterior surface of the ulna (Kizilkanata et al., 2007; Forriol Campos et al., 1987)<sup>3,4</sup> The blood supply to the sites of muscle attachment to the proximal half of the radius and ulna is directly reinforced by the nutrient arteries. There are, however, no significant muscle attachments to the distal half of the radius and ulna, corresponding to a general lack of nutrient foramina. Delayed or nonunion in the middle or lower diaphysis following trauma may be directly related to the absence of the nutrient arteries entering the bones in these areas. The posterior surface of both radius and ulna often lack nutrient foramina especially in the middle and dorsal diaphysis. That is why the dorsal localization for the plate is preferred during operative procedure.

#### Size of Nutrient Foramina

The present results showed that, Table 3 and 4 and Fig. 1, most of the foramina studied were dominant; all long bones of upper limb possessed a majority

**Table 3:** Position and number of Dominant Foramina (DF) and Secondary Nutrient Foramina (SF) observed in the Radius

Position	Total number of foramina	%	Number of Foramina					
			Single		Two		Three	
			DF	SF	DF	SF	DF	SF
Anterior surface	37	71.2%	34	—	3	—	—	—
Anterior border	06	11.5%	4	—	—	2	—	—
Posterior surface	02	03.8%	2	—	—	—	—	—
Posterior border	01	01.9%	1	—	—	—	—	—
Interosseous border	06	11.5%	5	—	—	1	—	—

**Table 4:** Position and number of Dominant Foramina (DF) and Secondary Nutrient Foramina (SF) observed in the ulna

Position	Total Number of Foramina	%	Number of Foramina					
			Single		Two		Three	
			DF	SF	DF	SF	DF	SF
Anterior surface	35	70%	35	—	—	—	—	—
Anterior border	10	20%	10	—	—	—	—	—
Interosseous border	05	10%	5	—	—	—	—	—

of secondary nutrient foramina. The present results contradicted with those of Kizilkanata et al. (2007)<sup>3</sup> who stated that most foramina were of the dominant type. They added that wherever a single nutrient foramen was observed, it was always dominant. This was not the case in the present study. Berard (1835)<sup>2</sup> stated that there was no femur without a dominant nutrient foramen.

#### Direction of Nutrient Foramina

In this study, all the nutrient foramina in humerus were directed distally (away from the growing ends). Similar observations were reported by Lutken (1950) who stated that all canals which were found in humerus were directed distally. In the radii examined, one foramen was directed towards the growing end and all others were away from the growing end. Similar observations were reported by Mysorekar (1967)<sup>10</sup> who stated that all nutrient foramina on the diaphysis of radius entered obliquely and were directed the elbow.

The nutrient foramina of all ulnae examined one had a proximal direction and remaining all were away from the growing end. Similar observation were reported by Craig et al., (2003)<sup>1</sup> who stated that all nutrient foramina on the shaft of the ulna entered obliquely and all were directed towards the elbow, (Table 5, Figs. 1 and 3).

**Table 5:** Position and direction of Nutrient Foramina in long bones of upper limb

Bone	Position		
	Type-1	Type-2	Type-3
Humerus	1 (1.7%)	55 (91.6%)	4 (6.7%)
Radius	20 (38.5%)	32 (61.5%)	0
Ulna	29 (58%)	21 (42%)	0

#### Obliquity of Nutrient Foramina

In all long bones of upper limbs examined, there were no changes in the obliquity of the foramen whether it was in the centre of the bone or nearer the ends. Such results were in agreement with those of Mysorekar (1967).<sup>10</sup>

#### Conclusion

The present study was undertaken to study the nutrient foramina of upper limb long bones. The study material consisted of 150 long bones; each bone was studied for the number, position, size, direction and obliquity of their nutrient foramina. In all bones nutrient foramina were single in number and were secondary in size. Most of the nutrient foramina were concentrated in the middle third of the bone. Nutrient foramina were mostly located on the anterior surface of the shaft of bones of the upper limb.

The direction of nutrient foramina followed the growing end theory. The results of the present study confirmed previous findings regarding the number and position of nutrient foramina of long bones of the limbs and provided clinical information concerning the nutrient foramina which could be useful as reference for surgical procedures. Accordingly, intimate understanding of the characteristic morphological features of the nutrient foramina by orthopedic surgeons is recommended. Exact position of the distribution of the nutrient foramina in bone diaphysis is important to avoid damage to the nutrient vessels during surgical procedure.

## References

1. Craig JG, Widman D, van Holsbeeck M. Longitudinal stress fracture: Patterns of edema and the importance of the nutrient foramen. *Skeletal Radiol* 2003 Jan;(32):22-27.
2. Berard A. Memoire sur le rapport qui existe la direction des conduits nourriciers des os longs et l'ordre suivant lequel les epiphysis se soudent au corps de l'os. *Archives generals de medicine* 1835;(7):176-83.
3. Kizilkanata E, Boyana N, Tozsahina E, et al. Location, number and clinical significance of nutrient foramina in human long bones. *Ann Anat* 2007;(189):87-95.
4. Forriol Compos F, Gomez pellico L, Gianonatti Alias M, et al. A study of the nutrient foramina in human long bones. *Surg Radiol Anat* 1987;(9):251-55.
5. Gotzen N, Cross A, Ifju P, et al. Understanding stress concentration about a nutrient foramen. *J Biomech* 2003;(36):1511-21.
6. Kirschner MH, Menck J, Hennerbichler A, et al. Importance of arterial blood supply to the femur and tibia for transplantation of vascularised femoral diaphyses and knee joints. *World J Surg* 1998;(2):845-52.
7. Langer K. Über das Gefässsystem der Röhrenknochen, mit Beiträgen zur Kenntnis des Baues und der Entwicklung des Knochengewebes. *Denkschr. Akad Wiss Wien* 1876;(36):1-40.
8. Lewis OJ. The blood supply of developing long bones with special reference to the metaphyses. *J Bone Jt Surg* 1956;(38):928-33.
9. Lutken P. Investigation into the position of the nutrient foramina and the direction of the vessel canals in the shafts of the humerus and femur in man. *Acta anat* 1950;9(1-2):57-68.
10. Patake SM, Mysorekar VR. Diaphyseal nutrient foramina in human metacarpals and metatarsals. *J Anat* 1977;(124):299-304.
11. Schwalbe G. Über die Ernährungskanäle und das Knochenwachstum. *Zeitschr F Anat U Entwgesch* 1876;(1):307-52.
12. Trueta J. Blood supply and the rate of healing of tibial fractures. *Clin Orthop Rel Res* 1974;(105):11-26.