

Original Article

A Six year Study on Neuronal and Mixed Neuronal: Glial Tumours

Boopathi Rajkumar¹, K Rama²**How to cite this article:**

Boopathi Rajkumar, K Rama/A Six year Study on Neuronal and Mixed Neuronal: Glial Tumours/J Pathol Res Pract 2022;11(1):9-16.

Abstract

Context: In this study, we have analyzed the spectrum of Neuronal and mixed Neuronal-Glial tumours and their incidence, age distribution, gender distribution and site of occurrence at a Government tertiary care hospital over a period of six years.

Aims: To assess the spectrum and prognosis of Neuronal and mixed Neuronal-Glial tumours and to review the slides from 2014 in accordance with the recent classification.

Materials and Methods: This study includes cases from over a period of six years from 2014-2019, analyzed both retrospectively and prospectively. The slides were reviewed in accordance with the recent classification.

Results: We identified 38 cases, which included 11 cases of Central Neurocytoma, 10 cases of Ganglioglioma, 10 cases of DysembryoplasticNeuroepithelial tumour, 3 cases of Anaplastic ganglioglioma, 3 cases of Papillary glioneuronal tumour and 1 case of Paraganglioma. 24 cases were WHO grade I, 11 cases grade II and 3 cases grade III. Central Neurocytoma predominantly occurred in the age group 20-30 and commonly affected males. The commonest site was intraventricular region. Ganglioglioma predominantly occurred in the age group 30-50 and males and females were equally affected. The commonest site involved was fronto-temporal region. DysembryoplasticNeuroepithelial tumour occurred predominantly in the age group 10-20 years and commonly affected males. The commonest site was frontal region. Among the three cases of Papillary glioneuronal tumour, which are usually low grade neoplasms, one case presented with recurrence.

Conclusion: The present study helps in gaining experience in the clinical and histological profile of these diverse tumours.

Keywords: Neuronal and Mixed Neuronal-Glial tumours; Central Neurocytoma; DNET; Papillary Glioneuronal tumour.

Keymessages: A case of papillary glioneuronal tumour presented with recurrence which emphasizes the need for molecular profiling of these neoplasms for better understanding.

Author Affiliation: ¹Postgraduate, ²Professor, Department of Neuropathology, Madras Medical College, Chennai 600003, Tamil Nadu, India.

Corresponding Author: K Rama, Professor, Department of Neuropathology, Madras Medical College, Chennai 600003, Tamil Nadu, India.

E-mail: rama63@gmail.com

Received on: 16.10.2021

Accepted on: 03.03.2022

Introduction

Neuronal and mixed Neuronal Glial tumours are a group of rare neoplasms that occur in the brain or spinal cord. In the revised fourth edition of the WHO classification of tumours of the central nervous system, the Neuronal and Mixed Neuronal-Glial tumours include Dysembryoplastic Neuroepithelial tumour, Gangliocytoma,

Ganglioglioma, Anaplastic Ganglioglioma, Dysplastic cerebellar gangliocytoma, Desmoplastic infantile astrocytoma and ganglioglioma, Papillary glioneuronal tumour, Rosette forming glioneuronal tumour, Diffuse leptomeningeal glioneuronal tumour, Central neurocytoma, Extraventricular neurocytoma, Cerebellar liponeurocytoma and Paraganglioma. Their incidence is relatively low. They frequently contain a glial component in addition to the neuronal component.

In this study, we have analyzed both retrospectively and prospectively the spectrum of Neuronal and mixed Neuronal-Glial tumours and their incidence, age distribution, gender distribution and site of occurrence at a Government tertiary care hospital over a period of six years.

Aim

- To assess the spectrum of Neuronal and mixed Neuronal-Glial tumours in a tertiary care hospital.
- Review of slides from 2014 and assessing in accordance with revised fourth edition of the WHO classification of tumours of the central nervous system
- To assess the prognosis

Materials and Methods

This study was conducted over a period of six years from January 2014 to August 2019 both retrospectively and prospectively. Neuronal and mixed neuronal glial tumours were included in this study.

For this study, 38 cases of Neuronal and mixed Neuronal-Glial tumours were identified and histopathological examination was carried out.

Inclusion Criteria

- All age groups diagnosed as Neuronal and mixed Neuronal-Glial tumours.

Exclusion Criteria

- All the non-neoplastic lesions.
- All the glial, embryonal, meningothelial and non-meningothelial tumours.

Results

Of all the cases from 2014-2019, about 2.8 % of cases were Neuronal and mixed Neuronal-Glial tumours (Table 1 and Figure 1).

Table 1: Annual Incidence From 2014-2019

Diagnosis	Annual Incidence From 2014-2019
Diffuse Astrocytic and Oligodendroglial Tumours	22%
Meningiomas	17.35%
Nerve Sheath Tumours	6.85%
Metastatic Deposits	10.25%
Pituitary Tumours	3%
Other Astrocytic Tumours	6.95%
Mesenchymal, Non-meningothelial Tumours	4.3%
Ependymal Tumours	4.2%
Embryonal Tumours	4.2%
Neuronal and Mixed Neuronal-glial Tumours	2.8%
Lymphomas	1%
Others	17.1%

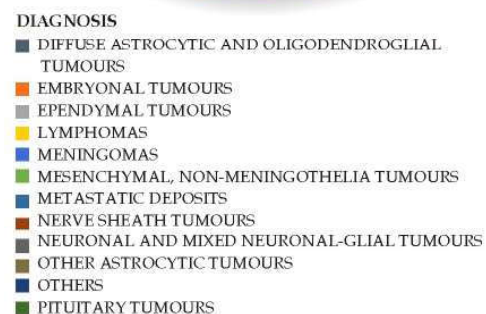
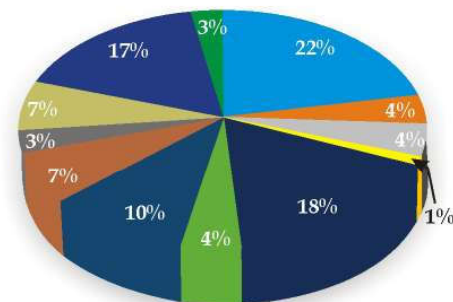


Fig. 1: Annual Incidence From 2014-19.

In this study, 38 cases of Neuronal and mixed Neuronal Glial tumours were identified and histopathological examination was carried out.

Of the 38 cases (Table 2 and Figure 2), 11 cases (28.9%) were found to be Central neurocytoma, 10

cases (26.3%) were found to be Ganglioglioma, 10 cases (26.3%) were found to be Dysembryoplastic Neuroepithelial Tumour, 3 cases (7.89%) were found to be Anaplastic ganglioglioma, 3 cases (7.89%) were found to be Papillary glioneuronal tumour and 1 case (2.63%) was found to be paraganglioma.

Table 2: Distribution of Neuronal and Mixed Neuronal Glial Tumours.

Diagnosis	No. of Cases	Percentage
Central Neurocytoma	11	28.9%
Ganglioglioma	10	26.3%
Dysembryoplastic Neuroepithelial Tumour	10	26.3%
Anaplastic Ganglioglioma	3	7.89%
Papillary Glioneuronal Tumour	3	7.89%
Paraganglioma	1	2.63%

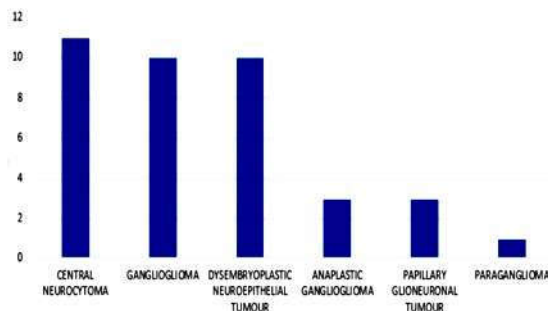


Fig. 2: Case Distribution.

24 cases belonged to WHO grade I, 11 cases belonged to WHO grade II and 3 cases belonged to WHO grade III (Figure 3).

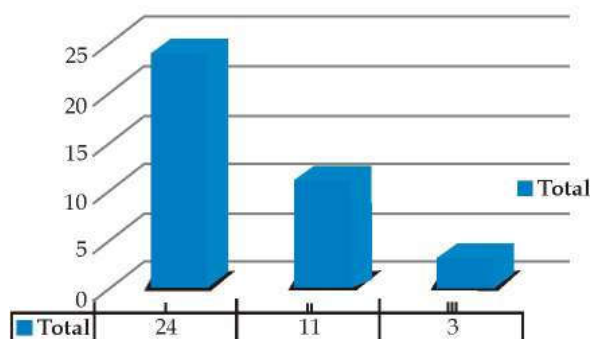


Fig. 3: Who Grade.

Central neurocytoma predominantly occurred in the age group 20-30 (Figure 4) and commonly affected males (Figure 5). The commonest site was intraventricular region (Figure 6).

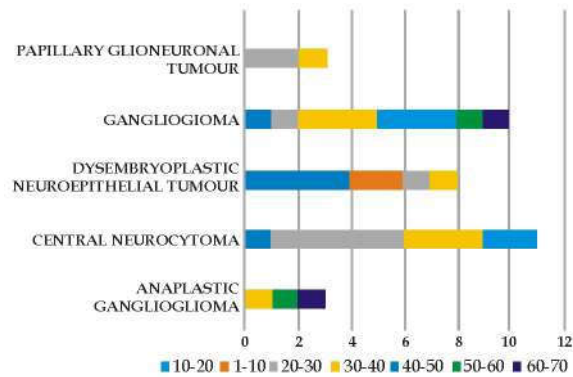


Fig. 4: Age Range

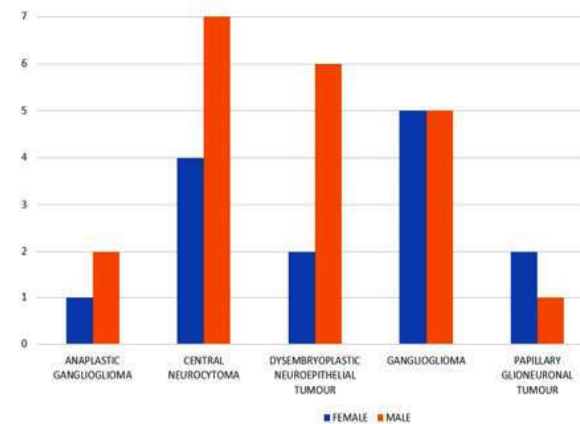


Fig. 5: Gender Predilection.

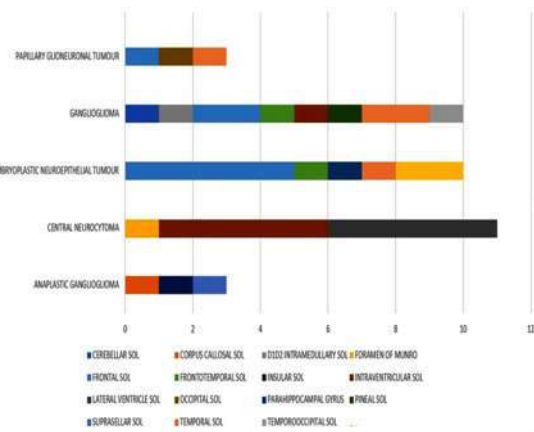


Fig. 6: Site Predilection

Ganglioglioma predominantly occurred in the age group 30-50 and males and females were equally affected. The commonest site involved was fronto-temporal region.

Dysembryoplastic Neuroepithelial Tumour occurred predominantly in the age group 10-20 years and commonly affected males. The commonest site was frontal region.

Discussion

Central Neurocytoma

Central neurocytoma is an uncommon intraventricular neoplasm composed of uniform round cells with a neuronal phenotype and low proliferation index.¹ It was initially described by Hassoun et al² in 1982, where he reported two cases of central neurocytoma and described it as a different pathological entity. It is classified as histologically grade II tumour by World Health Organization.¹ Despite their increased recognition, Central neurocytoma comprises only about 0.1-0.5% of all the brain tumours.^{3,4,5,6} Although being a

benign tumour, poor outcome has also been noted in some cases.⁷

Central neurocytoma is thought to arise from the septum pellucidum. However multiple hypothesis have been proposed regarding their origin, namely from neuronal cells, neuronal progenitor cells and bi-/multipotent precursor cells.⁸⁻¹²

Most of the histopathological features of central neurocytoma closely resemble those of oligodendroglioma and ependymoma. Accurate diagnosis is important since central neurocytoma has a favorable prognosis and complete surgical resection is curative in most patients.¹³⁻¹⁵

Table 3: Comparison of Epidemiological Features of Central Neurocytoma.

Study	AGE (Highest Incidence)	Gender	Localization
WHO Classification of Tumours of the Central Nervous System (Revised 4th edition) ¹	Third decade	Both sexes equally affected	Lateral ventricles
Patel DM et al ¹⁶	Third decade	Both sexes equally affected	Lateral ventricles
Lee SJ et al ¹⁷	Third decade	Both sexes equally affected	Lateral ventricles
Our study	Third decade	Male preponderance	Lateral ventricles

The median age in this study is 29.5 years (Table 3), which correlates with 28.5 years proposed in WHO Classification of Tumours of the Central Nervous System (Revised 4th edition)¹, while in Figarella-branger D et al¹⁸ and Sharma MC et al¹⁹ the median age is 34 years.

The present study demonstrated male preponderance with a male-female ratio of 1.7:1 while in WHO Classification of Tumors of the Central Nervous System (Revised 4th edition)¹, Hassoun J et al⁵, Maiuri et al²⁰, Patel DM at al¹⁶, Lee SJ et al¹⁷, Vasiljevic A et al²¹ demonstrated no gender predilection.

The most common location in this study is the lateral ventricles which corresponded with the findings of WHO Classification of Tumours of the Central Nervous System (Revised 4th edition)¹, Patel DM et al¹⁶ and Lee SJ et al.¹⁷

Grossly Neurocytomas are greyish, well circumscribed, lobulated, with areas of hemorrhage

and cystic degeneration and calcifications.¹⁹ Light microscopy demonstrates uniform, small-to-medium sized cells with rounded nuclei, finely stippled chromatin and inconspicuous nucleoli, scant cytoplasm. On immunohistochemistry, the cells are positive for synaptophysin which is the most appropriate and consistent diagnostic marker. Central neurocytomas also show positivity for neuron specific enolase. GFAP staining is variable.¹⁹

Ganglioglioma

Gangliogliomas are well differentiated, slow-growing glioneuronal Neoplasms composed of dysplastic ganglion cells in combination with neoplastic glial cells.¹ It is classified as grade I tumour by WHO.¹ It along with gangliocytomas accounts for 0.4% of all CNS tumours.¹ Malignant transformation to anaplastic ganglioglioma, WHO grade III has also been reported.²⁹

Gangliogliomas are rare lesions of the CNS accounting for 0.4 to 1.3 % of all brain tumours

Table 4: Comparison of Epidemiological Features of Ganglioglioma

Study	Age (highest incidence)	Gender Predilection	Localization
WHO Classification of Tumours of the Central Nervous System (Revised 4th edition) ¹	8.5-25 Years	Male preponderance	Temporal lobe
Odia Y et al ³⁰	8.5-25 Years	Male preponderance	Temporal lobe
Zentner J et al ³¹	25 years	Male preponderance	Temporal lobe
Isimbaldi G et al ³²	29 years	Male preponderance	Temporal lobe
Our study	38.3 years	Both sexes equally affected	Fronto-temporal region

predominating during infancy.²²⁻²⁷ The term Ganglioglioma was coined by Perkins in 1926.²⁸

In this study, the median age group was 38.3 years (Table 4) and the majority of the cases occurred in the 30-50 age group. While majority of the cases occurred in between 8.5-25 years in WHO Classification of Tumours of the Central Nervous System (Revised 4th edition)¹ and Odia Y et al.³⁰

In the study by WHO Classification of Tumours of the Central Nervous System (Revised 4th edition)¹, Lang FF et al³³, Prayson RA et al³⁴, Thom M et al³⁵, Wolf HK et al³⁶, there was a male preponderance while in the present study both the gender were equally affected.

The majority of the tumours in the study by WHO Classification of Tumours of the Central Nervous System (Revised 4th edition)¹, Lang FF et al³³, Prayson RA et al³⁴, Wolf HK et al³⁶, Blümcke I et al³⁷ and Hirose T et al³⁸ were localized to the temporal lobe while in the present study, the majority of the tumours were located in the Fronto-temporal region.

Microscopically the ganglioglioma is characterized by a mixture of neoplastic ganglion cells and neoplastic glial elements. The glial component is typically astrocytic. Clusters of large cells potentially representing neurons are required for diagnosis. The other features are neoplastic glial cells should not cluster around neoplastic neurons, presence of fibrosis and calcifications. Binucleate neurons are diagnostic but not seen in some cases. Ganglion cells can be identified using Nissl stains and by the presence of a large nucleoli. Immunohistochemically gangliogliomas are reactive for synaptophysin, class 3 betatubulin(100%), NFP(90%), Chromogranin

A(86%), S-100(71%) and GFAP. Synaptophysin staining along the surface of large neoplastic neurons is characteristic of ganglioglioma while coarse granular immunoreactivity in the neuropil background is also common. MAP-2 immunoreactivity is absent in the neoplastic glial component of gangliogliomas while it is seen in most low grade glial tumours.

In this study, we have reported three cases of anaplastic gangliogliomas, which are WHO grade III histologically. Anaplastic ganglioglioma consists of malignant transformation of the glial component and is characterized by increased mitotic activity, prominent micro vascular proliferation, necrosis and high MIB-1 and TP53 labelling indices. Malignant transformation of both neuronal and glial components is extremely rare.³⁹⁻⁴¹

Dysembryoplastic Neuroepithelial Tumour

Dysembryoplastic Neuroepithelial Tumour is a benign, slow growing neoplasm and belongs to WHO grade I. It was first proposed by Daumos-Duport in 1988.⁴² It is associated with good prognosis. It is thought of as a hamartomatous malformation consisting of normal neuronal and glial components with a multi-nodular architecture. But the incidences of malignant transformation and recurrence following subtotal resection demonstrates a neoplastic tendency.

The median age at diagnosis (the median age of seizure onset) is 17.8 years in this study (Table 5) which correlates with the studies by Sharma, mehar et al⁴³-16.5 years and Suh YL et al⁴⁴-14.5 years. In this study there was a male predilection which coincides with the findings of WHO Classification of Tumours of the Central Nervous System (Revised

Table 5: Comparison of Epidemiological Features of Dysembryoplastic Neuroepithelial Tumour

Study	AGE (Highest Incidence)	Gender Predilection	Localization
WHO Classification of Tumours of the Central Nervous System (Revised 4th edition) ¹	25.8 Years	Male preponderance	Temporal lobe
Sharma, mehar et al ⁴³	16.5 years	Male preponderance	Temporal lobe
Suh YL et al ⁴⁴	14.5 years	Male preponderance	Temporal lobe
Our study	17.8 years	Male preponderance	Frontal lobe

4th edition)¹, Sharma, mehar et al⁴³ and Suh YL et al.⁴⁴ The cases in this study showed a propensity for frontal lobe while temporal lobe was commonly involved in the studies by WHO Classification of Tumours of the Central Nervous System (Revised 4th edition)¹, Sharma, mehar et al⁴³ and Suh YL et al.⁴⁴

Grossly, they may present as solitary, well

defined mass or poorly demarcated lesion. Cut surface may show extension into the underlying subcortical white matter in case of large tumours. Multi-nodular appearance can also be present.

There are three histological variants in DNET. Complex variant consists of specific glioneuronal elements with glial nodules and a multinodular architecture. Simple variant consists of specific

glioneuronal elements only. Non-specific variant has no specific glioneuronal elements but resemble complex DNET clinically and radiologically.

Specific glioneuronal elements are small, round monotonous cells, so called oligodendroglia-like cells and may form typical nodules but can also present as diffuse pattern. The oligodendroglia-like cells are arranged in a columnar pattern perpendicular to the cortical surface and separated by a mucinous matrix. Based on the amount of mucinous matrix, OLC are arranged in various patterns namely microcystic, alveolar, compact or targetoid. Floating neurons are observed within the mucinous pool.

Frank nuclear atypia and multinucleated cells are commonly seen in glial components. Non specific DNET consists of poorly demarcated, diffuse cortical lesions with blurred normal anatomic landmarks. Necrosis, mitosis and microvascular

proliferation are uncommon.

Immunohistochemistry in DNET

Within the specific neuronal elements, Floating neurons show positivity for synaptophysin, NeuN, NSE, MAP2 and class III beta-tubulin. Most of the OLC are positive for S-100 and Oligo-2 but are negative for GFAP. Rarely OLC may show positivity for NeuN. In the non-specific variant, synaptophysin positivity is slightly reduced while MAP2 is frequently expressed.

Papillary Glioneuronal Tumour

Papillary glioneuronal tumours are low grade biphasic Neoplasms with astrocytic and neuronal differentiation and are designated as grade I by WHO1 and account for less than 0.02% of intracranial tumours.⁴⁵ It was first described by Komori and colleagues in 1998.⁴⁶ It presents a biphasic and

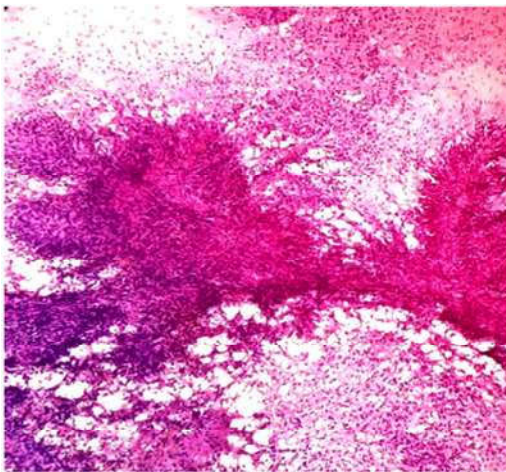


Fig. 7a: Hematoxylin and Eosin Stained Sections of Papillary Glioneuronal Tumour which Presented with Recurrence.

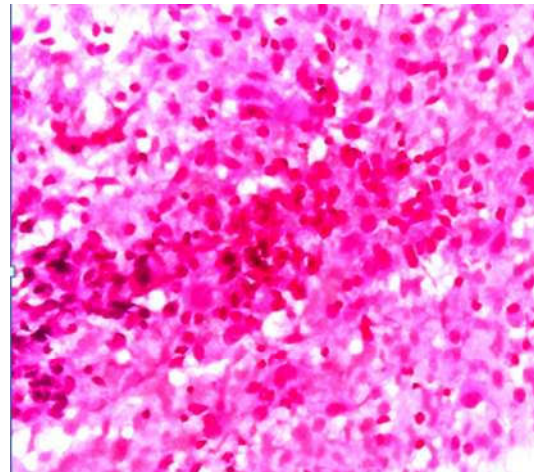


Fig. 7b: Hematoxylin and Eosin Stained Sections of Papillary Glioneuronal Tumour which Presented with Recurrence.

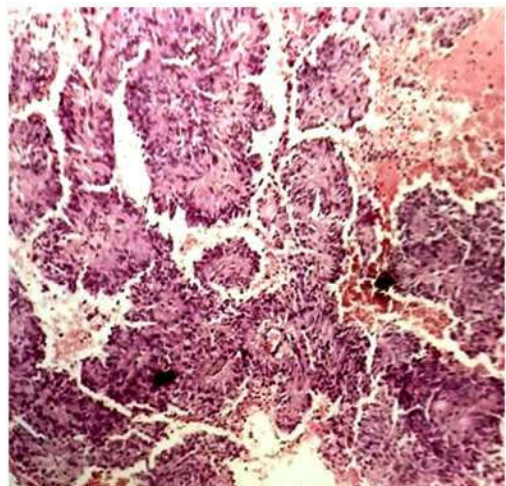


Fig. 7c: Hematoxylin and Eosin Stained Sections of Papillary Glioneuronal Tumour which Presented with Recurrence.

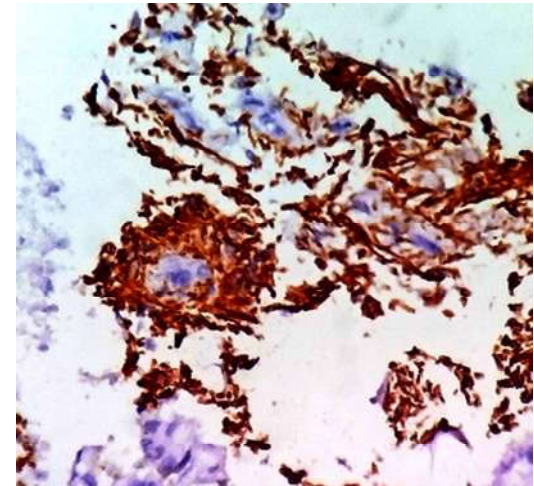


Fig. 7d: IHC (Gfap) Stained Sections of Papillary Glioneuronal Tumour which Presented with Recurrence.

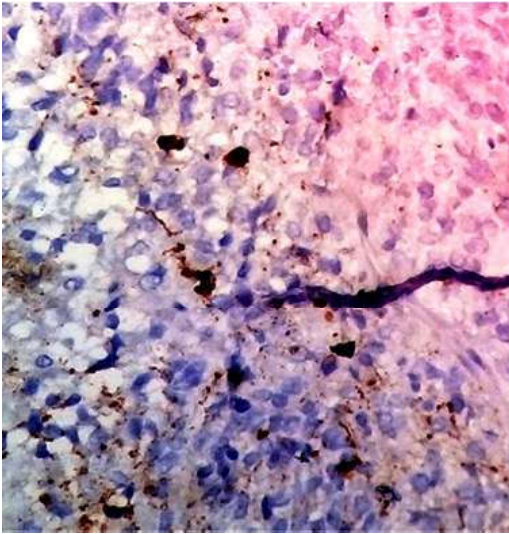


Fig. 7e: Synaptophysin Stained Sections of Papillary Glioneuronal Tumour which Presented with Recurrence.

biphenotypic differentiation. Histologically, it is characterized by a glial component arranged in papillary architecture overlaying hyalinized vessels with interpapillary regions comprising of homogenous oligodendrocyte-like, neurocyte-like cells, ganglioid cells and ganglion cells.⁴⁷ In the present study, one case presented with recurrence (Figure 7a-e).

Conclusion

Glioneuronal tumours because of the overlapping features can be misdiagnosed and the present study helps in gaining experience in the clinical and histological profile of these diverse tumours. Further studies incorporating molecular pathology and electron microscopy with extensive clinical follow-up could contribute to better awareness of the histogenesis and pathology of these tumours aiding in development of a better management regimen.

References

1. David N.Louis, Hiroko Ohgaki, Otmar D. Wiestler, Webster K. Cavenee (Eds): WHO Classification of Tumours of the Central Nervous System (Revised 4th edition). IARC; Lyon 2016.
2. Hassoun J, Gambarelli D, Grisoli F, et al. Central neurocytoma. An electron-microscopic study of two cases. *Acta Neuropathol* 1982; 56:151-6.
3. Coca S, Moreno M, Martos JA, Rodriguez J, Barcena A, Vaquero J. Neurocytoma of spinal cord. *Acta Neuropathol* 1994;87:537-40.
4. Figarella-Branger D, Soylemezoglu F, Kleihues P, Hassoun J. Central neurocytoma. In: Kleihues P, Cavenee WK. Pathology and genetics of tumors of the nervous system. Lyon: IARC Press; 2000.p.107-9.
5. Hassoun J, Soylemezoglu F, Gambarelli D, Figarella-Branger D, von Ammon K, Kleihues P. Central neurocytoma: a synopsis of clinical and histological features. *Brain Pathol* 1993;3:297-306.
6. Kim DG, Chi JG, Park SH, et al. Intraventricular neurocytoma: clinicopathological analysis of seven cases. *J Neurosurg* 1992;76:759-65.
7. Mrak RE. Malignant neurocytic tumor. *Hum Pathol* 1994;25:747-52.
8. Kane AJ, Sughrue ME, Rutkowski MJ, et al. The molecular pathology of central neurocytomas. *J Clin Neurosci* 2011;18:1-6.
9. Chen H, Zhou R, Liu J, et al. Central neurocytoma. *J Clin Neurosci* 2012;19:849-53.
10. Ishiuchi S, Tamura M. Central neurocytoma: an immunohistochemical, ultrastructural and cell culture study. *Acta Neuropathol* 1997;94:425-35.
11. Sim FJ, Keyoung HM, Goldman JE, et al. Neurocytoma is a tumor of adult neuronal progenitor cells. *J Neurosci* 2006;26:12544-55.
12. Tsuchida T, Matsumoto M, Shirayama Y, et al. Neuronal and glial characteristics of central neurocytoma: electron microscopical analysis of two cases. *Acta Neuropathol* 1996;91:573-7.
13. Rades D, Fehlaue F. Treatment options for central neurocytoma. *Neurology* 2002;59:1268-70.
14. Rades D, Fehlaue F, Lamszus K, et al. Well-differentiated neurocytoma: what is the best available treatment? *Neuro-oncol* 2005;7:77-83.
15. Rades D, Schild SE. Treatment recommendations for the various subgroups of neurocytomas. *J Neurooncol* 2006;77:305-9.
16. Patel DM, Schmidt RF, Liu JK. Update on the diagnosis, pathogenesis, and treatment strategies for central neurocytoma. *J Clin Neurosci*. 2013;20(9):1193-1199. doi:10.1016/j.jocn.2013.01.001.
17. Lee SJ, Bui TT, Chen CH, et al. Central Neurocytoma: A Review of Clinical Management and Histopathologic Features. *Brain Tumor Res Treat*. 2016;4(2):49-57. doi:10.14791/btrt.2016.4.2.49.
18. Figarella-Branger D, Soylemezoglu F, Kleihues P, Hassoun J. Central neurocytoma. In: Kleihues P, Cavenee WK. Pathology and genetics of tumors of the nervous system. Lyon: IARC Press; 2000.p.107-9.
19. Sharma MC, Deb P, Sharma S, Sarkar C. Neurocytoma: a comprehensive review. *Neurosurg Rev* 2006;29:270-85; discussion 285.
20. Maiuri F, Spaziante R, De Caro ML, Cappabianca P, Giamundo A, Iaconetta G. Central neurocytoma: clinico-pathological study of 5 cases and review of the literature. *Clin Neurol Neurosurg* 1995;97:219-28.
21. Vasiljevic A, François P, Loundou A, et al. Prognostic

- factors in central neurocytomas: a multicenter study of 71 cases. *Am J Surg Pathol* 2012;36:220-7
22. Demierre B, Sticho FA, Hori A, et al. Intracerebral ganglioglioma. *J Neurosurg* 1986;65: 177-82.
 23. Drake J, Hoffmann HJ, Kobayashi J, et al. Surgical management of children with temporal lobe epilepsy and mass lesions. *Neurosurgery* 1987;21:792-7.
 24. Garrido E, Becker LF, Hoffman HJ, et al. Gangliogliomas in children. A clinicopathological study. *Childs Brain* 1978;4:339-46.
 25. Kalyan-Raman UP, Olivero WC. Ganglioglioma: a correlative clinicopathological and radiological study of ten surgically treated cases with follow-up. *Neurosurgery* 1987;20:428-33.
 26. Sutton LN, Packer RJ, Rorke LB, et al. Cerebral gangliogliomas during childhood. *Neurosurgery* 1983;13:124-8
 27. Zulch KJ. *Adoas of Gross Neurosurgical Pathology*. Berlin: Springer, 1975:49-50.
 28. Perkins OC. Ganglioglioma. *Arch Pathol Lab Med* 1926;2:11-7.
 29. Jay V, Squire J, Blaser S, Hoffman HJ, Hwang P. Intracranial and spinal metastases from a ganglioglioma with unusual cytogenetic abnormalities in a patient with complex partial seizures. *Childs Nerv Syst*. 1997; 13: 550-555.
 30. Odia Y. Gangliocytomas and Gangliogliomas: Review of Clinical, Pathologic and Genetic Features. *Clin Oncol*. 2016; 1: 1017
 31. Zentner, J., Wolf, H. K., Ostertun, B., Hufnagel, A., Campos, M. G., Solymosi, L., & Schramm, J. (1994). Gangliogliomas: clinical, radiological, and histopathological findings in 51 patients. *Journal of Neurology, Neurosurgery & Psychiatry*, 57(12), 1497-1502.
 32. Isimbaldi G, Sironi M, Tonarelli GP, Roncoroni M, Declich P, Galli C. Ganglioglioma: a clinical and pathological study of 12 cases. *Clin Neuropathol*. 1996;15(4):192-199.
 33. Lang FF, Epstein FJ, Ransohoff J, Allen JC, Wisoff J, Abbott IR, et al. (1993). Central nervous system gangliogliomas. Part 2: Clinical outcome. *J Neurosurg*. 79(6):867-73. PMID:8246055
 34. Prayson RA, Khajavi K, Comair YG (1995). Cortical architectural abnormalities and MIB1 Immunoreactivity in gangliogliomas: a study of 60 patients with intracranial tumors. *J Neuropathol Exp Neurol*. 54(4):513-20. PMID:7541447
 35. Thom M, Blümcke I, Aronica E (2012). Long-term epilepsy-associated tumors. *Brain Pathol*. 22(3):350-79. PMID:22497610.
 36. Wolf HK, Muller MB, Spanle M, Zentner J, Schramm J, Wiestler OD (1994). Ganglioglioma: a detailed Histopathological and immunohistochemical analysis of 61 cases. *Acta Neuropathol*. 88(2):166-73. PMID:7985497
 37. Blümcke I, Wiestler OD (2002). Gangliogliomas: an intriguing tumor entity associated with focal epilepsies. *J Neuropathol Exp Neurol*. 61 (7):575-84. PMID:42125736
 38. Hirose T, Scheithauer BW, Lopes MB, Gerber HA, Altermatt HJ, Vanden Berg SR (1997). Ganglioglioma: an ultrastructural and immunohistochemical study. *Cancer*. 79(5):989-1003. PMID:9041162
 39. Jay V, Squire J, Becker LE, Humphreys R. Malignant transformation in a ganglioglioma with anaplastic neuronal and astrocytic components. Report of a case with flow cytometric and cytogenetic analysis. *Cancer*. 1994; 73: 2862-2868.
 40. Kawataki T, Sato E, Sato T, Kinouchi H. Anaplastic Ganglioglioma with malignant features in both neuronal and glial components - A case report. *Neurol Med Chir*. 2010; 50: 228-231.
 41. Mittelbronn M, Schittenhelm J, Lemke D, Ritz R, Nägele T, Weller M, et al. Low grade ganglioglioma rapidly progressing to a WHO grade IV tumor showing malignant transformation in both astroglial and neuronal cell components. *Neuropathology*. 2007; 27: 463-467.
 42. Daumas-Duport C, Scheithauer BW, Chodiewicz JP, Laws ER Jr, Vedrenne C. Dysembryoplastic neuroepithelial tumour: a surgically curable tumor of young patients with intractable partial seizures. Report of thirty-nine cases. *Neurosurgery*. 1988;23:545-56
 43. Sharma, Mehar & Jain, Deepali & Gupta, Aditya & Sarkar, Chitra & Suri, Vaishali & Garg, Ajay & Gaikwad, Sanjay & Chandra, Sarat. (2009). Dysembryoplastic neuroepithelial tumor: A clinicopathological study of 32 cases. *Neurosurgical Review*. 32. 161-170. 10.1007/s10143-008-0181-1.
 44. Suh YL. Dysembryoplastic Neuroepithelial Tumors. *J Pathol Transl Med*. 2015;49(6):438-449. doi:10.4132/jptm.2015.10.05
 45. Agarwal S, Sharma MC, Singh G, Suri V, Sarkar C, Garg A, et al. (2012). Papillary glioneuronal tumor-a rare entity: report of four cases and brief review of literature. *Childs Nerv Syst*. 28(11):1897-904. PMID:22868530
 46. Komori TMD, Scheithauer BW, Anthony DCMD, Rosenblum MK, McLendon RE, Scott RM, et al. Papillary glioneuronal tumor: a new variant of mixed neuronal-glial neoplasm. *J Surg Pathol Oct*. 1998;22:1171-83.
 47. Louis DN, Ohgaki H, Wiestler OD, Cavenee WK, Burger PC, Jouvet, A et al. The 2007 WHO classification of tumours of the central nervous system. *Acta Neuropathol (Berl)*. 2007;114:97-109. doi:10.1007/s00401-007-0243-4.

