

Neural Tube Defects Repair: An Initial Experience at our Institute

¹Basavaraj T Badadal, ²H Vishnu Teja, ³Mallikarjun Utagi,
⁴Tejaswini Vallabha, ⁵M B Patil

Author's Affiliation: ^{1,3} Assistant Professor, ²Junior Resident, ⁴Professor, ⁵Professor and HOD, Department of General Surgery, BLDE (Deemed to be university) Shri B M Patil Medical College and Research Centre, Vijayapur, Karnataka 586101, India.

Corresponding Author: Basavaraj T Badadal. Department of General Surgery BLDE (Deemed to be university) Shri B M Patil Medical college and Research Centre, Karnataka 586101, India.

E-mail: Btbnims2015@gmail.com

How to cite this article:

H Vishnu Teja, Mallikarjun Utagi, Basavaraj T Badadal, et al. Neural Tube Defects Repair: an Initial Experience at Our Institute. Int J Neurol Neurosurg. 2021;13(1):9-14.

Abstract

Neural tube defects are most frequent, costly & deadly of all congenital anomalies. Open neural tube defect has exposed neural tissue and is continuously or intermittently leaking cerebrospinal fluid, extensive changes are almost always present in the CNS. Closed neural tube defect has no visible neural tissue and no leaking CSF. Causes include genetic and environmental factors. They may occur in isolation or as a part of a syndrome or chromosomal disorder. It has been estimated that 60-70% of neural tube defects have genetic component. The occurrence or recurrence of neural tube defects can be prevented with administration of folic acid before and in early pregnancy.

The aim of present study is to assess different types of spinal cord malformation and their outcome of surgery of the patients admitted to our institute.

Methods: This prospective study reports 10 cases of neural tube defects at different levels of spinal cord. Occipital, dorsal and lumbo-sacral regions that are admitted to our hospital for surgical repair between October 2018 to September 2019.

Results- A total of 10 cases have been operated after confirming the diagnosis with MRI, out of which 1-occipital, 1-thoracic and 8 are lumbosacral region. All the patients have improved well and are under regular follow-up. Out of which 6 were male and 4 were female. 3 were neonates, 2 were infants and 5 were children.

Conclusion- All 10 cases are managed accordingly and producing no new neurological deficits post operatively. An early diagnosis, timely intervention and meticulous repair gives good results.

Keywords: Congenital; Neural tube defect; Surgical repair; Prevention.

Introduction

Neural tube defects are most frequent, costly & deadly of all congenital anomalies. Dysraphism is defined as failure of normal midline fusion of vertebra, spinal cord, nerve root. Spina bifida

is defined as failure of fusion of vertebral arch (Aperta, cystica, occulta). Still there is a controversy regarding the classification but broadly, Neural tube defects are divided in to two types- open and closed types. Open neural tube defect has exposed neural tissue and is continuously or intermittently leaking

cerebro-spinal fluid, extensive changes are almost always present in the central nervous system¹ with Chiari II malformation/Hydrocephalus. Closed neural tube defect has no visible neural tissue and no leaking Cerebro Spinal Fluid, only spinal cord is involved and brain is rarely involved. Causes include genetic and environmental factors. They may occur in isolation or as a part of a syndrome or chromosomal disorder². It has been estimated that 60-70% of neural tube defects have genetic component⁶. The occurrence or recurrence of neural tube defects can be prevented with administration of folic acid before and in early pregnancy⁵.

The aim of present study is to assess surgical outcome in open and closed spinal cord defects of the patients admitted to our institute.

Materials and Methods

It's a prospective study done in patients who got admitted in Department of General Surgery at our between November 2018 to September 2019.

Detailed history was taken including Ante natal checkups, supplementation of Iron and folic acid during pregnancy.

Patients underwent necessary investigations, Magnetic Resonance Imaging/Computerized

Tomography – accordingly surgery was planned.

Results

A total of 10 cases have been operated after confirming the diagnosis with Magnetic resonance imaging /Computerized Tomography, out of which 1-occipital, 1-thoracic and 8 are lumbosacral region.

Some presented with very thin transparent layer without any Cerebrospinal fluid leak and some presented to us with healed scar tissue which are leaking previously. Even with huge swelling presented after 3 months complaining that unable to sleep in supine position. All patient undergone surgery with myelomeningocele repair, post operatively no patient developed new onset deficit, wound infection noted and they are under follow up regularly.

None of the patients had signs of meningitis. Open defects were operated on emergency basis.

All patients are subjected for brain screening with Magnetic resonance imaging /Computerized Tomography for hydrocephalus, if present simultaneously Ventriculo-Peritoneal shunt followed by Myelomeningocele repair is done.

Table 1: Case details.

Age	Gender	Diagnosis	Type	Procedure	Hospital stay (in days)
3 months	Male	Lumbar Myelomeningocele	Closed	MMC Repair	8
3 months	Male	Thoraco-lumbar Myelomeningocele with hydrocephalus	Closed	MMC Repair with VP shunt	10
5 days	Male	Sacral meningocele	Closed	Meningocele Repair	6
2 days	Female	Lumbar Myelomeningocele	Closed	MMC Repair	5
20 days	Male	Lumbo-sacral Myelomeningocele	Open	MMC Repair	8
9 days	Female	Limited dorsal myeloschisis	Closed	MMC Repair	7
7 months	Female	Lumbo-sacral Myelomeningocele	Closed	MMC Repair	8
4 months	Male	Sacral Meningocele	Closed	Meningocele repair	5
15 days	Female	Occipital encephalocele	Closed	Repair	9
1 year	Female	Lumbo-sacral Myelomeningocele	Closed	MMC repair	5

*MMC - Myelomeningocele

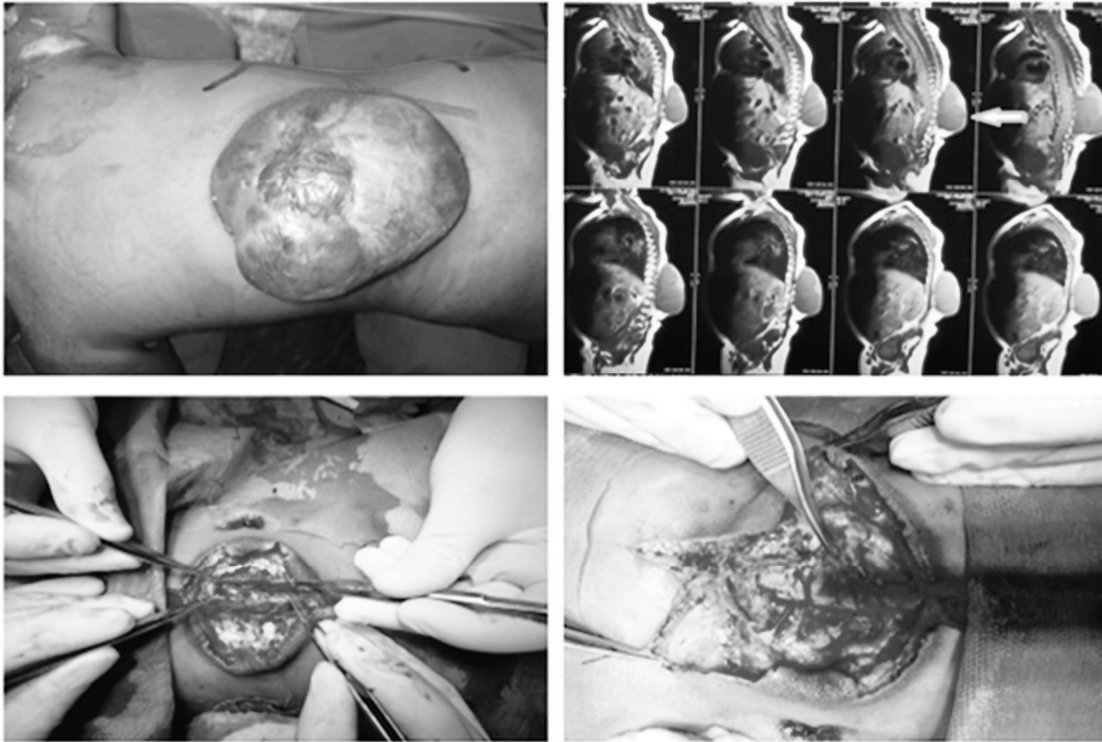

Fig. 1: Thoraco-lumbar MMC with hydrocephalus.

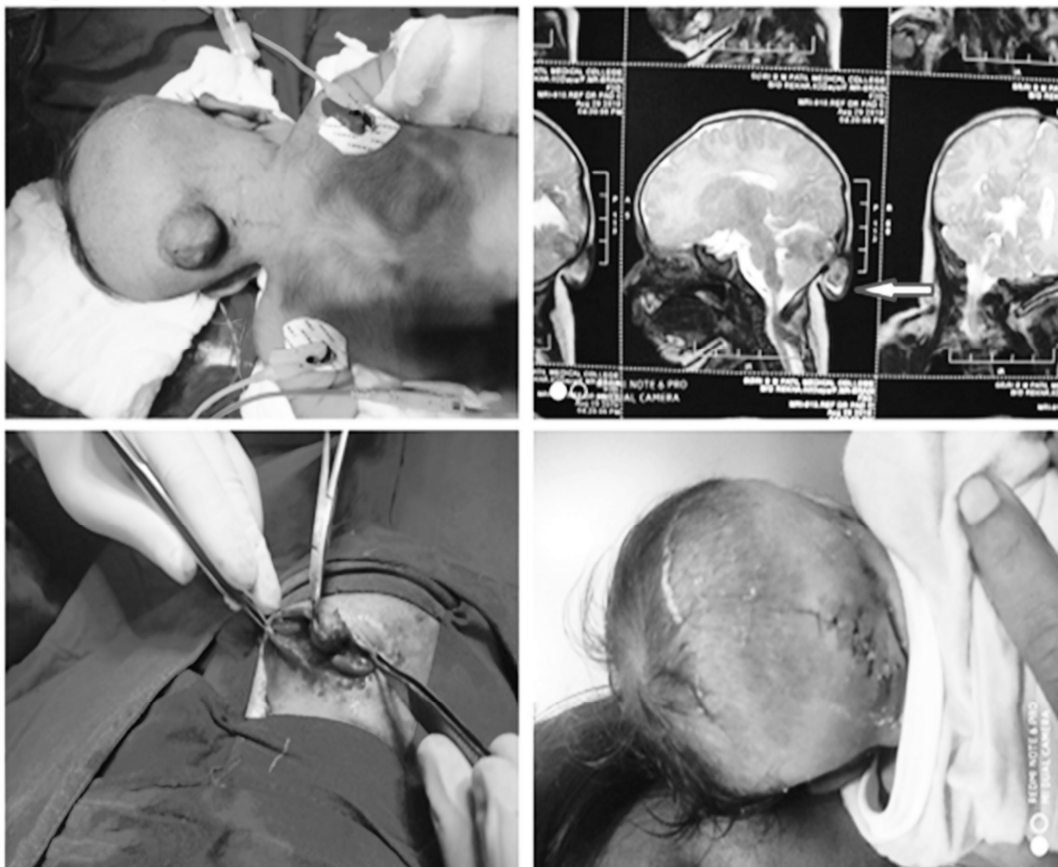


Fig. 2 : Occipital encephalocele.

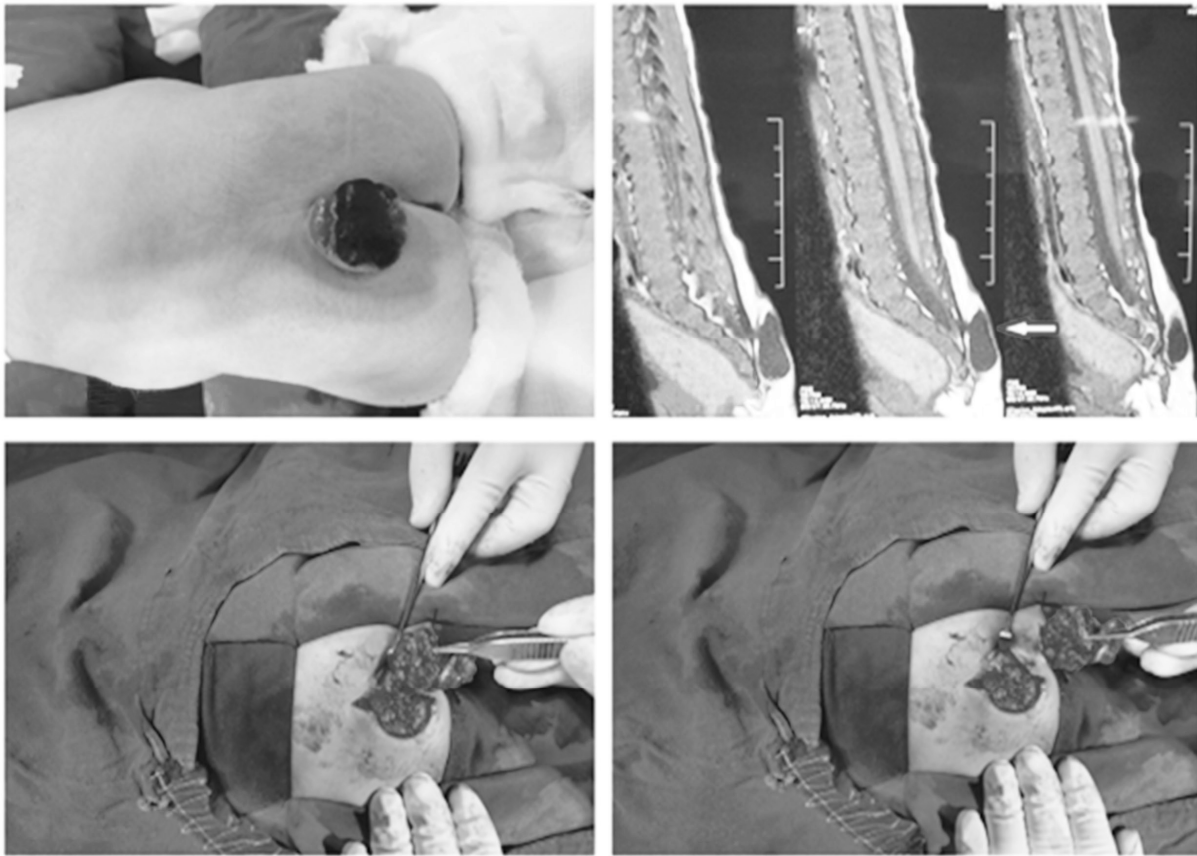


Fig.3: Sacral Myelocoele.

Discussion

Neural tube defects are birth defects of the brain, spine, or spinal cord. They happen in the first month of pregnancy. The two most common neural tube defects are spina bifida and anencephaly. In spina bifida, the fetal spinal column doesn't close completely. In anencephaly, most of the brain and skull do not develop. Babies with anencephaly are usually either stillborn or die shortly after birth¹.

Children born with spina bifida often have a fluid-filled sac on their back that is covered by skin, called a meningocele. If the sac contains part of the spinal cord and its protective covering, it is known as a myelomeningocele. The signs and symptoms of these abnormalities range from mild to severe, depending on where the opening in the spinal column is located and how much of the spinal cord is contained in the sac².

Encephalocele occurs when the tube fails to close near the brain and there is an opening in the skull. The brain and membranes that cover it can protrude through the skull, forming a sac-like bulge. In some cases, there is only a small opening in the nasal cavity or forehead area that

is not noticeable. Infants with Encephalocele may have other problems, such as hydrocephalus, limb paralysis, developmental delays, intellectual disabilities, seizures, vision problems, a small head, facial and skull abnormalities, and uncoordinated movements i.e., ataxia¹.

An established risk factor for neural tube defects like spina bifida is deficiency of vitamin B9 (folic acid). It's recommended that 400 micrograms of folic acid each day from one month before conceiving until 12 weeks of pregnancy are significantly less likely to have a baby with spina bifida or a related neural tube defect. In case of previous pregnancy baby had neural tube defect, they are advised to take a higher dose of 5 milligrams (mg) of folic acid each day until they are 12 weeks pregnant⁵.

Magnetic resonance imaging is the investigation of choice for the treatment of neural tube defects and it helps for planning of surgery. Surgery is the main stay of treatment.

In the present study, out of 10 cases 8 cases had not undergone regular Ante natal checkups and anomaly scan.

In one case intra operatively, in Limited Doral

Myeloschisis (thoracic) is fully epithelialized with primary neurulation (Gastrulation preneurulation defect), it consists of more than one form of neurulation abnormality (Hydrocephalus/cerebellar tonsil herniation), in our case dysplastic glial tissue with stalk extending to the dome of meningocele. No evidence of GIT malformations or other system involvement. Not associated with any other neural tube defects.

There was a case of paraplegia with hydrocephalus, for which VP shunting was done along with the Myelomeningocele repair, all the nerve roots are clumped and attached to the placode forming a gliotic tissue, nerve roots are tried to separate, some are blind ending and some are traversing distally which are spared and dural sheet made from coverings and cord closed in layer, no post op leak noted, paraplegia sustained even after surgery, patient is under follow up.

Even in open spina bifida presented to us after 20 days with leaking CSF, repair was done with reconstruction of dura, post operatively no deficit was noted.

There were cases with sacral mass attached to the dura but not invading the dura, the sacral mass was excised completely and dural repair was done, post operatively no defect was noted the same mass sent for histopathological examination found to be neural element with gliosis, suggestive of faulty migration of neural tissue.

The problems that can be encountered are post operative re tethering of the cord, post operative neural deficits, as in infants bowel and bladder control cannot be assessed till toilet training comes.

No post-operative CSF leak/ Meningitis/wound infections were noted in our study.

Limitations

- Sample size is less
- Bladder & Bowel control cannot be assessed till toilet training is attained in paediatric age group
- No nerve monitor like Motor Evoked Potential (MEP) & Somato Sensory Evoked Potential (SSEP) were used
- Needs long term follow up

Conclusion

- In the present study 10 cases including occipital, thoracic and lumbo-sacral regions, they are managed accordingly and having no new neurological deficits

post operatively.

- An early diagnosis, timely intervention for open neural tube defects gives good results however needs long term follow up.
- In last one year there were more than 15 spina bifida patients at single centre, in spite of adequate education for maternal health check-up and taking care of pregnancy, more than 80% of our patients do not have adequate, Ante natal check (ANC) up's and anomalyscan to intervene during early stages of neural tube defects, needs to educate at ground level for regular ANC's.
- The complex classification of neural tube defects is still questionable, in this series of cases about 9 out of 10 seems to be post neurulation defect as the spinal cord is completely formed.

References

1. McComb, J. G. (2015). A practical clinical classification of spinal neural tube defects. *Child's Nervous System*, 31(10), 1641-1657. <https://doi.org/10.1007/s00381-015-2845-9>.
2. Sewell, M. J., Chiu, Y. E., & Drolet, B. A. (2015, March 1). Neural tube dysraphism: Review of cutaneous markers and imaging. *Pediatric Dermatology*. Blackwell Publishing Inc. <https://doi.org/10.1111/pde.12485>.
3. Saker, E., Loukas, M., Fisahn, C., Oskouian, R. J., & Tubbs, R. S. (2016, November 1). Historical Perspective of Split Cord Malformations: A Tale of Two Cords. *Pediatric Neurosurgery*. S. Karger AG. <https://doi.org/10.1159/000450584>.
4. Schmidt, C., Bryant, E., Iwanaga, J., Oskouian, R. J., Oakes, W. J., & Tubbs, R. S. (2017, July 1). Meningocele manqué: a comprehensive review of this enigmatic finding in occult spinal dysraphism. *Child's Nervous System*. Springer Verlag. <https://doi.org/10.1007/s00381-017-3472-4>.
5. Kondo, A., Matsuo, T., Morota, N., Kondo, A. S., Okai, I., & Fukuda, H. (2017, September 1). Neural tube defects: Risk factors and preventive measures. *Congenital Anomalies*. Blackwell Publishing. <https://doi.org/10.1111/cga.12227>.
6. Lupo, P. J., Agopian, A. J., Castillo, H., Castillo, J., Clayton, G. H., Dosa, N. P., Mitchell, L. E. (2017). Genetic epidemiology of neural tube defects. *Journal of Pediatric Rehabilitation*

- Medicine, 10(3-4), 189-194. <https://doi.org/10.3233/PRM-170456>.
7. Aggarwal, V., Nair, P., Shivhare, P., Jayadevan, E. R., Felix, V., Abraham, M., & Nair, S. (2017). A Case of Evolving Bilateral Sphenoidal Meningoencephaloceles: Case Report and Review of the Literature. *World Neurosurgery*, 100, 708.e11-708.e17. <https://doi.org/10.1016/j.wneu.2017.02.037>.

