

Report of Two Cases of the Trabecular Variant of Juvenile Ossifying Fibroma of the Jaws and Review of the Literature

Ayappali Kalluvalappil Nabeel¹, S S Binisree², Divya Chandran³

How to cite this article:

Ayappali Kalluvalappil Nabeel, S S Binisree, Divya Chandran/Report of Two Cases of the Trabecular Variant of Juvenile Ossifying Fibroma of the Jaws and Review of the Literature/Indian J Dent Educ. 2022;15(4):147-153.

Abstract

Juvenile ossifying fibroma (JOF) is a benign but potentially aggressive fibro-osseous lesion involving craniofacial bones. Children and young adults are commonly affected. Young adults and children are frequently affected. JOF is distinguished from the adult variant, based on age, site, clinical behaviour, and microscopic appearance. Its aggressive nature and high recurrence rate, demand early detection and complete surgical excision. In this article, we'll discuss two cases, that presented with maxillary and mandibular swellings and were later identified as trabecular variants of juvenile ossifying fibroma.

Keywords: Juvenile ossifying fibroma; Maxilla; Mandible; Fibro-osseous lesion.

INTRODUCTION

Juvenile ossifying fibroma (JOF) is an uncommon expansive benign neoplasm with bone formation. It is distinguished from other fibro-osseous lesions by clinical parameters such as the age of onset, clinical presentation, and potential behaviour.¹ The lesion exhibits aggressive growth and a high

recurrence rate. It is commonly seen affecting children between 5 and 15 years of age and results in considerable facial disfigurement.²

Juvenile ossifying fibromas usually arise in the vicinity of paranasal sinuses.^{3,4} Very few cases of mandibular JOF have been reported. El Mofty et al., have reported two histopathological variants: trabecular JOF (TrJOF) and Psammomatoid (PsJOF).^{5,6} One clinical feature that helps to differentiate TrJOF from PsJOF is the site of involvement with PsJOF occurring mainly in paranasal sinuses and TrJOF occurring mainly in jaws, although there is a disagreement, as to which jaw has greater predilection, maxilla, or mandible.⁷ Most of the studies reported an increased predilection for the maxillary region.^{3,8,9} The average age of occurrence of TrJOF is 8.5-12 years, whereas that of PsJOF is 16-33 years. JOF should be treated like a locally aggressive neoplasm due to its high rate of recurrence (30-58%).^{1,3,4}

Author's Affiliation: ¹Consultant, Department of Oral Medicine and Radiology, Dental Home, Pee Key Z Arcade, Ayikkarappadi, Malappuram 673637 Kerala, India, ²Senior Resident, Department of Oral Pathology and Microbiology, ³Senior Resident, Department of Oral Medicine and Radiology, Government Dental College, Thiruvananthapuram 695011, Kerala, India.

Corresponding Author: Ayappali Kalluvalappil Nabeel, Consultant, Department of Oral Medicine and Radiology, Dental Home, Pee Key Z Arcade, Ayikkarappadi, Malappuram 673637 Kerala, India.

E-mail: nabeelsabeel@gmail.com

Received on: 19.09.2022

Accepted on: 08.10.2022

This article aims to report two cases of TrJOF affecting a 6 year old female and a 10 year old male patient with clinical, radiographic, and histopathological features.

CASE REPORTS

Case 1

A 6 year old female patient was referred to the Department of Oral Medicine and Radiology presenting with the complaint of a hard swelling on the right side of the cheek (Fig. 1). Both the patient and his parents were aware of the swelling for approximately two and a half months. They also noticed the upward shifting of the right eye globe 1 month back. The lesion had been rapidly increasing in size since it was first noticed. There was no history of trauma, pain, paraesthesia, or lymphadenopathy.

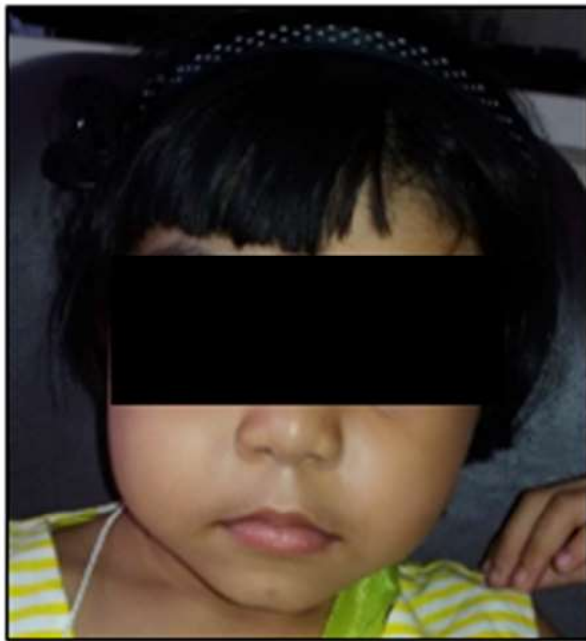

Fig. 1: Facial asymmetry due to diffuse swelling on the right side of the face with the upward shifting of the right eye globe.

On physical examination, the girl was a healthy, normally developed individual with no apparent distress. Significant facial asymmetry with cortical expansion was caused by an approximately 6 x 7cm mass and involved the right side of the maxilla extending from 54 to 16. On palpation, the mass was hard and non tender and was not adherent to the overlying skin. No bruits or pulsations were detected. No palpable intra oral swelling was noted clinically. She had a partial right nasal obstruction and a mild blurred vision of the right eye. There

was no evidence of abscess formation, dehiscence, or malocclusion.

A panoramic radiograph showed a diffuse osteolytic lesion at the right maxilla obliterating the maxillary sinus (Fig. 2).

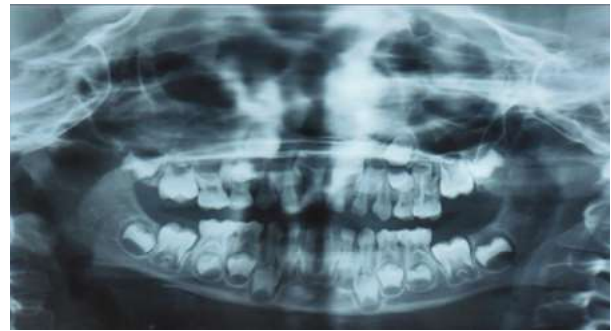


Fig. 2: Panoramic radiograph showing diffuse osteolytic lesion at right maxilla obliterating maxillary sinus.

A Paranasal view showed an ill-defined radiopacity occupying the floor of the right maxillary sinus (Fig. 3).

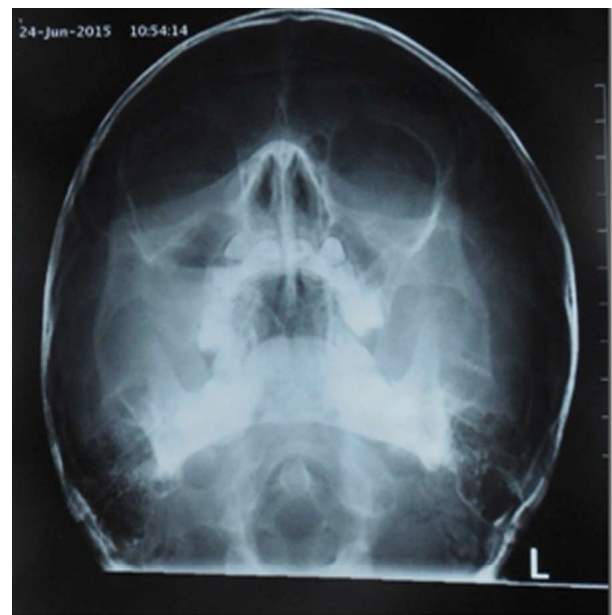

Fig. 3: Paranasal view showing an ill-defined radiopacity occupying the floor of the right maxillary sinus.

A computed tomography scan (CT) of the right maxilla showed a large, well circumscribed mass totally replacing the right maxillary sinus with expansion to the nasal cavity and the infratemporal fossa and bulging into the floor of the orbit compressing the extraocular muscles. The bony walls were thinned out and scalloped. Deep erosion of the cortex of the alveolar bone was noted (Fig. 4-6).

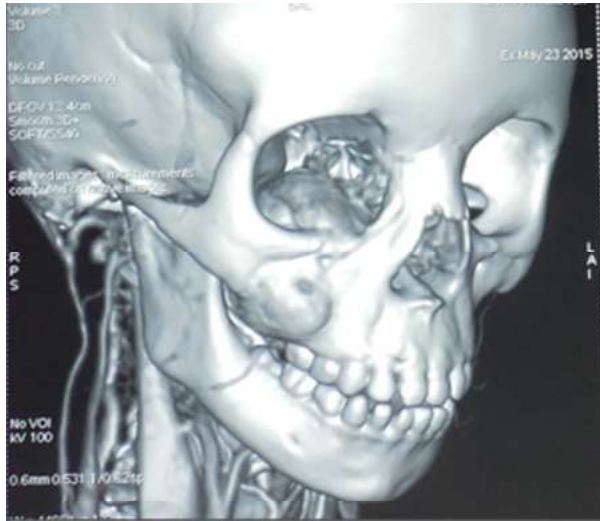


Fig. 4: 3D CT reconstruction showing moderately large nearly spherical mass totally replacing the right maxillary antrum.

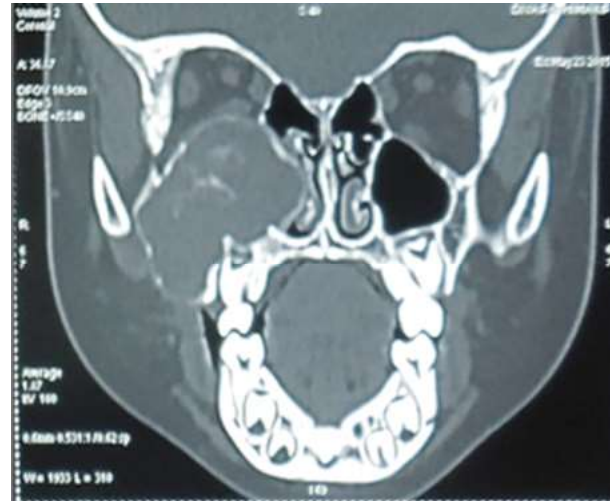

Fig. 5: CT coronal view showing a large, well circumscribed mass totally replacing the right maxillary sinus with expansion to the nasal cavity and the infratemporal fossa and bulging into the floor of the orbit.

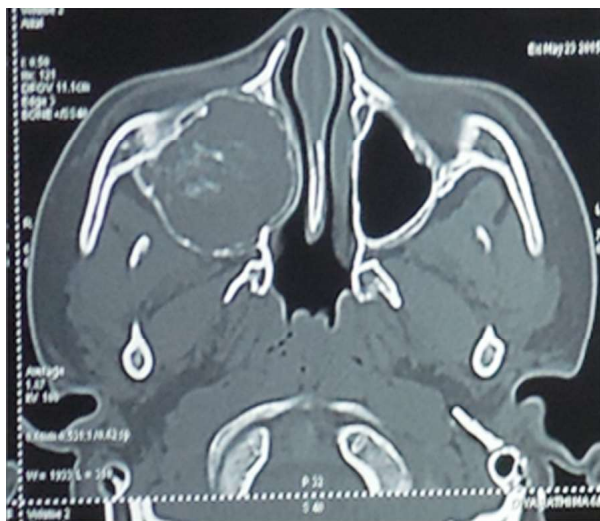

Fig. 6: CT axial view shows moderate heterogeneous enhancement in the mottled pattern with irregular non-enhancing areas in between the enhancing parts.

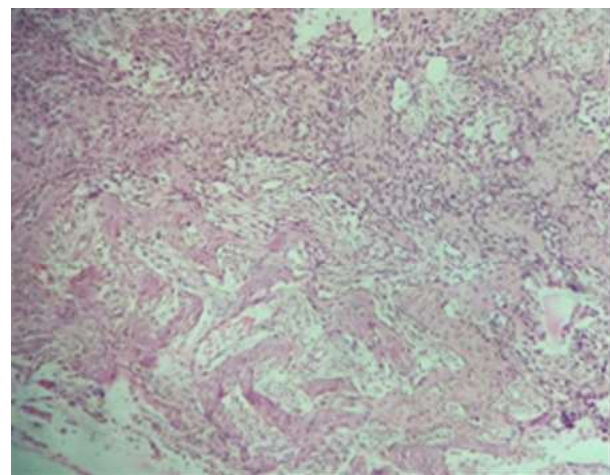


Fig. 7: Photomicrograph showing immature bony trabeculae in a highly cellular stroma 10x (HE).

An incisional biopsy was subsequently performed and referred to the Department of Oral Pathology and Microbiology, providing a diagnosis of ossifying fibroma. Approximately 3 weeks later, the lesion was excised under general anaesthesia and sent for a histopathology examination. Microscopically numerous immature bony trabeculae in a highly cellular stroma were seen. The cells were spindle in shape and resemble fibroblasts. In many areas, the osseous trabecula is seen merging with the stroma. A few giant cells were also noticed especially at the periphery and surrounding the blood vessels (Fig. 7-8).

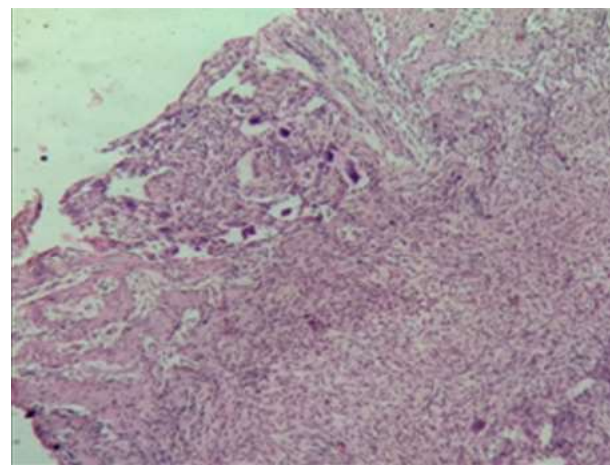


Fig. 8: Photomicrograph showing highly cellular stroma with bony trabeculae merging into the stroma with multinucleated giant cells in the periphery 40x (HE)

Based on the clinical history, histologic features, and radiographic findings it was diagnosed as juvenile ossifying fibroma of trabecular variant. The patient was discharged from the hospital and is under routine follow-up.

Case 2

A 10 year old boy was referred to the Department of Oral Medicine and Radiology presenting with the complaint of swelling on the left side of his face (Fig. 9). Both the patient and his parents had been aware of the swelling for approximately two months. The lesion had been slowly increasing in size since it was first noticed. There was no history of trauma, pain, paraesthesia, lymphadenopathy, or dysphagia.

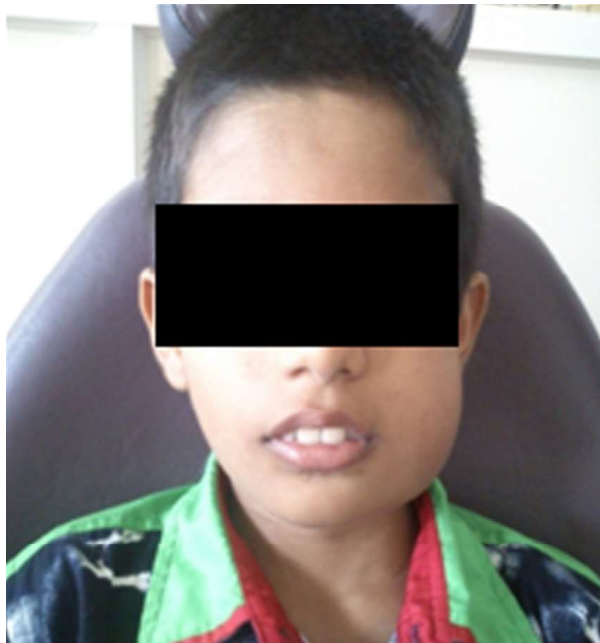

Fig. 9: Extraoral photograph showing significant facial asymmetry on the left side of the face caused due to swelling in the left mandibular body, angle, and ramus region

On physical examination, the boy is a healthy, normally developed individual with no apparent distress. Significant facial asymmetry with cortical expansion was caused by an approximately 6 x 7cm mass and involved the left mandibular body, angle, and ramus. On palpation, the mass was hard and non-tender and was not adherent to the overlying skin. No bruits or pulsations were detected. On intraoral examination, a solitary bony hard swelling was seen on left lower alveolus extending from 74 to 36 region and showed expansion of the left buccal cortex, which was firm to palpation (Fig. 10). Significant medial expansion of the inferior cortical

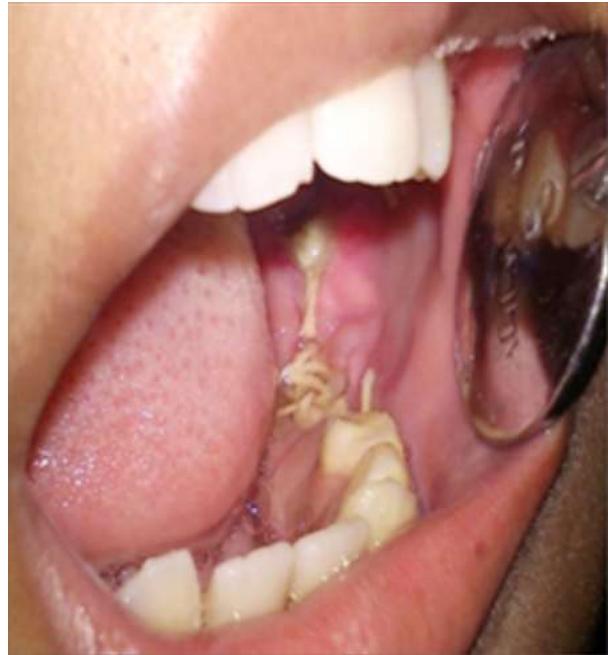

Fig. 10: Intra oral photograph showing obliterated buccal vestibule.

bone also was noted. There was no evidence of abscess formation, dehiscence, or malocclusion. Examination of the neck found no abnormalities.

An oral panoramic radiograph was taken which showed a well circumscribed multilocular lesion involving the left ramus and body of mandible with scalloping border extending from 74 to 36 region with tooth bud of 37 pushed into the ramus and root resorption of 36 is also seen with a faint, linear to irregular central opacities (Fig. 11). A computed tomography (CT) scan of the left mandible showed medial and lateral cortical expansion and areas of central calcification (Fig. 12). Laboratory values were within normal limits.

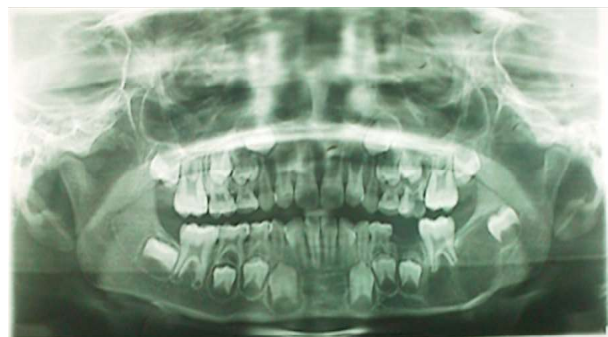

Fig. 11: Panoramic view shows a well circumscribed multilocular lesion involving the left ramus and body of mandible with scalloping border extending from 74 to 36 region with tooth bud of 37 pushed into the ramus and root resorption of 36.

The main characteristic features of JOF are the early age of onset, tumour localisation, clinical presentation, aggressive behaviour, and the high tendency to recur.^{3,12} Clinically it may present as an asymptomatic gradual or rapid expansion of the affected bone leading to facial asymmetry. It can grow to a considerable size and show an aggressive behaviour of rapid growth with cortical thinning, perforation, and involvement of many adjacent anatomical structures.^{2,11} Symptoms are variable and include facial swelling, enlarging hard mass, sinusitis, nasal obstruction, teeth displacement, resorption, perforation of the cortices or bone, eye proptosis, and epistaxis. Pain and paraesthesia are the rare symptoms of JOF. The tumour erodes bone partitions and encroaches on adjacent orbital, nasal, and cranial compartments, distorting the face, displacing orbital contents, and blocking normal sinus drainage.¹³

Radiographically, it can be seen as a unilocular or multilocular radiolucency or a mixture of radiolucent and radio dense areas with well defined borders. Radiographs can show root displacement and resorption though rarely.¹⁴

JOF is thought to arise from the differentiation of mesenchymal cells of the periodontal ligament, multipotent precursor cells, forming into fibrous tissue cementum or osteoid.^{4,12} There are differences in opinion regarding the localization of the lesion, as the maxilla to be most frequent site, while some reported a mandibular predominance.^{10,13} Johnson et al. found a higher incidence in females,

Table 1: Characteristics of the cases of JOF in the jaws

Year	Authors	Location	Gender	Age	Radiographic features
2002	Khoury et al. ¹⁷	Right maxilla	female	6 months	Mixed radiolucency and radiopacity/ cortical expansion
2002	El-Mofty ⁶	Left mandibular ramus	Male	15 years	Mixed radiolucency and radiopacity/ multilocular cortical expansion
2007	Foss and Fielding ¹⁸	Right posterior mandible	Male	4 years	Radiolucent/unilocular/cortical expansion
2009	Yang et al. ¹⁹	Right maxillary sinus	Female	46 years	Radiopaque cortical expansion
2009	Smith et al. ²⁰	Body of the right mandible	Female	12 years	Radiolucent /multilocular /cortical expansion
2009	Thankappan et al. ¹⁶	Body of the right mandible	Female	27 years	Radiolucent/multilocular/cortical expansion
2012	Tolentino et al. ²¹	Body of the right mandible	Male	12 years	Mixed radiolucency and radiopacity/ multilocular/cortical expansion
2012	Tolentino et al. ²¹	Body of the right mandible	Male	20 years	Mixed radiolucency and radiopacity/ multilocular/cortical expansion

The clinical findings, radiographic features, duration, and extension of the lesion into soft tissue, tooth displacement, resorption and perforation of cortices or bone in addition to the rapid growth of the lesion favour the diagnosis of an aggressive variety of JOF.^{14,15}

and Bertrand et al. found that it is equally seen in both genders.¹⁴ Typically, the tumour involves the maxilla, paranasal sinuses, orbital, frontal and ethmoidal bones; however, single cases of mandibular lesions have also been reported.^{7,15}

Lawton et al. did a literature review which revealed 17 cases reported between 2003 and 2010 with a sex ratio of five females for one male in adults, while a male predominance is observed in the juvenile with a mean age of 11 years.^{15,16} The age of the patients in our case are 6 and 10 years which is inconcurrent with the previous reports. Clinically JOF is asymptomatic most of the time, however less commonly it is aggressive and symptomatic. This asymptomatic nature was also appreciated in both cases presented here. Here the right side of the maxilla and the left side of the mandible is affected.

In the present cases, swelling of the duration of two and two and a half months was reported. The variation in the duration was reported from slowly growing over a period of years to a rapid increase in weeks. The spectrum of radiographic features of JOF varies from a well defined unilocular to multilocular with central opacification. This radiographic variation of JOF is due to the stage, duration, and histology of the neoplasm. 50% of cases of sinus JOF are reported in multiple sinuses with the remaining occurring in a single sinus. The JOF also was seen in a single sinus as it is in one of our cases presented here. The different Characteristics of the cases of JOF in the jaws reported in the literature are summarized in table 1.

Furthermore, differential diagnoses considered were other fibro-osseous lesions of the jaw such as fibrous dysplasia, cemento-ossifying fibroma, osteoid osteoma, and osteosarcoma. Radiographically, in JOF demarcation of the tumor from the surrounding bone is well defined, unlike

fibrous dysplasia which is having a typical ground glass appearance and poorly defined margins as it blends with the surrounding normal bone. In contrast to cemento-ossifying fibroma which histologically is characterized by uniformity of pattern, JOF is expected to show a more heterogeneous morphology. Aggressive growth pattern, destruction of cortices with an outgrowth of the soft tissue component, widening of the periodontal ligament spaces and destruction of lamina dura differentiate osteosarcoma from JOF.¹⁶

Complications of JOF include ocular disturbances, intracranial extension, cysts, and recurrences. Though the lesion is aggressive and has a high rate of recurrence, malignant transformation to sarcoma has not been reported yet.^{12,16}

CONCLUSION

Though benign, juvenile ossifying fibroma has an aggressive clinical behaviour and a strong tendency to recur. JOF is a progressively growing lesion which can attain enormous sizes and cause considerable facial deformity if left untreated. Hence radical surgery is often necessary. Because the recurrence rate for JOF ranges from 30% to 58%, continued follow-up is essential. Early and correct identification of these distinct entities is important for academic purposes and more importantly, for proper diagnosis and therapeutic management.

REFERENCES

1. Kashyap RR, Nair GR, Gogineni SB. Asymptomatic Presentation of Aggressive Ossifying Fibroma: A Case Report. *Case Rep Dent* 2011; 2011: 1-4.
2. Williams HK, Mangham C, Speight PM. Juvenile ossifying fibroma. An analysis of eight cases and a comparison with other fibro-osseous lesions. *Journal of oral pathology & medicine* 2000; 29: 13-18.
3. Johnson L, Yousefi M, Vinh TN, et al. Juvenile active ossifying fibroma. Its nature, dynamics and origin. *Acta Otolaryngol Suppl* 1991; 488: 1-40.
4. Bendet E, Bakon M, Tadmor R, et al. Juvenile cemento-ossifying fibroma of the maxilla. *Ann Otol Rhinol Laryngol* 1997; 106: 75-78.
5. Guna Shekhar M, Bokhari K. Juvenile aggressive ossifying fibroma of the maxilla. *J Indian Soc Pedod Prev Dent* 2009; 27: 170-174.
6. El-Mofty S. Psammomatoid and trabecular juvenile ossifying fibroma of the craniofacial skeleton: Two distinct clinicopathologic entities. *Oral Surg Oral Med Oral Pathol Oral Radiol Endod* 2002; 93: 296-304.
7. Kramer IRH, Pindborg JJ, Shear M. The World Health Organization histological typing of odontogenic tumours. Introducing the second edition. *Eur J Cancer B Oral Oncol* 1993; 29: 169-171.
8. Slootweg PJ, Müller H. Juvenile ossifying fibroma. Report of four cases. *Journal of cranio-maxillofacial surgery* 1990; 18: 125-129.
9. Leimola-Virtanen R, Vähätalo K, Syrjänen S. Juvenile active ossifying fibroma of the mandible: A report of 2 cases. *Journal of Oral and Maxillofacial Surgery* 2001; 59: 439-444.
10. Rathore A, Ahuja P, Chhina S. Juvenile Ossifying Fibroma-WHO Type. *Journal of Case Reports and Studies* 2014; 2: 1-4.
11. Slootweg PJ, Panders AK, Koopmans R, et al. Juvenile ossifying fibroma. An analysis of 33 cases with emphasis on histopathological aspects. *Journal of oral pathology & medicine* 1994; 23: 385-388.
12. Sun G, Chen X, Tang E, et al. Juvenile ossifying fibroma of the maxilla. *Int J Oral Maxillofac Surg* 2007; 36: 82-85.
13. Bertrand B, Eloy Ph, Cornelis JPh, et al. Juvenile aggressive cemento-ossifying fibroma: case report and review of the literature. *Laryngoscope* 1993; 103: 1385-1390.
14. Lawton MT, Heiserman JE, Coons SW, et al. Juvenile active ossifying fibroma. Report of four cases. *J Neurosurg* 1997; 86: 279-285.
15. Abuzinada S, Alyamani A. Management of juvenile ossifying fibroma in the maxilla and mandible. *J Maxillofac Oral Surg* 2010; 9: 91.
16. Thankappan S, Nair S, Thomas V, et al. Psammomatoid and trabecular variants of juvenile ossifying fibroma-two case reports. *Indian J Radiol Imaging* 2009; 19: 116-119.
17. Khoury NJ, Naffaa LN, Shabb NS, et al. Juvenile ossifying fibroma: CT and MR findings. *European Radiology* 2003 12:3 2002; 12: 109-113.
18. Foss RD, Fielding CG. Juvenile Psammomatoid Ossifying Fibroma. *Head Neck Pathol* 2007; 1: 34.
19. Yang HY, Zheng LW, Mds JL, et al. Psammomatoid juvenile cemento-ossifying fibroma of the maxilla. *Journal of Craniofacial Surgery* 2009; 20: 1190-1192.
20. Smith SF, Newman L, Walker DM, et al. Juvenile aggressive psammomatoid ossifying fibroma: an interesting, challenging, and unusual case report and review of the literature. *Journal of oral and maxillofacial surgery* 2009; 67: 200-206.
21. Tolentino ES, Centurion BS, Tjioe KC, et al. Psammomatoid juvenile ossifying fibroma: an analysis of 2 cases affecting the mandible with review of the literature. *Oral Surg Oral Med Oral Pathol Oral Radiol* 2012; 113: 40-45.