

Combination Therapy for Acute Management of Yellow Oleander Poisoning: A Case Report

Mohammed Mubashir Ahmed Subhani¹, Ashima Sharma², Suneel Kumar G³,
Mohammed Ismail Nizami⁴

How to cite this article:

Mohammed Mubashir Ahmed Subhani, Ashima Sharma et al./Combination Therapy for Acute Management of Yellow Oleander Poisoning: A Case Report/Indian J Emerg Med 2022;8(4):149-151.

Author's Affiliation: ¹Junior Resident, ²Professor, ³Additional Professor and Head, ⁴Associate Professor, Department of Emergency Medicine, Nizam's Institute of Medical Sciences, Hyderabad 500082.

Corresponding Author: Mohammed Ismail Nizami, Associate Professor, Department of Emergency Medicine, Nizam's Institute of Medical Sciences 500082

E-mail: ismail_nizami@rediffmail.com

Received on: 04.08.2022

Accepted on: 02.05.2022

Abstract

Ingestion of yellow oleander as a mode of suicide is common in India and Southeast Asia. It is associated with severe cardiac toxicity. A combination therapy is suggested in a resource limited setting as Digoxin specific antibody fragments are not easily available for treatment of serious cardiac glycoside poisoning. Severe atrio-ventricular block can be treated with atropine or temporary cardiac pacing. Ventricular tachycardia can be treated with low dose cardioversion and ventricular fibrillation with low dose defibrillation depending on the presentation.

Keywords: Yellow Oleander Poisoning; Digoxin specific antibody fragments; Defibrillation; Cardioversion.

INTRODUCTION

Yellow oleander poisoning is a common method of deliberate self harm in developing countries in Southeast Asia. Toxicity after acute ingestion of cardiac glycoside containing plants is similar to medicinal digitalis poisoning and is associated with severe cardiac toxicity and a mortality rate of about 10%.¹ Digoxin-specific antibodies (Fab) fragments bind to naturally occurring cardiac glycosides, including those found in plants, and reverses toxicity in human poisoning. It is recommended that patients who ingest cardiac glycoside-containing plants and develop life threatening

arrhythmias (eg, atrioventricular node or severe sinus node block) or serum potassium >5.0 to 5.5 mEq/L receive digoxin-specific Fab fragments.

CASE

An 18 years old male with no prior comorbidities presented to ED with alleged history of deliberate self harm by consuming 5-8 seeds of yellow oleander. He was found semi-conscious by family members and brought to ED within 3-4 hours of intake. He had 3 episodes of vomiting during transit. On arrival, his BP was 100/60 mm Hg, Pulse 55 bpm, SpO₂- 97% on room air and GCS

of E2 V3M5. Random blood glucose was 94 mg/dl. The ABG was suggestive of mild metabolic acidosis with severe hyperkalemia and the ECG showed third degree heart block with *Reverse tick sign/ Salvador Dali appearance* (Fig. 1). We managed our patient with combination therapy with glucose, insulin and bicarbonate in absence of Digifab.

Regular Insulin 10 units in 100 mL 25% dextrose was used to decrease the serum potassium to <5.5 mEq/L and repeated, if required. Additionally, sodium bicarbonate 8.4% 50 mL intravenous boluses were given six hourly. Patient was continuously monitored for brady arrhythmias and serum potassium levels.

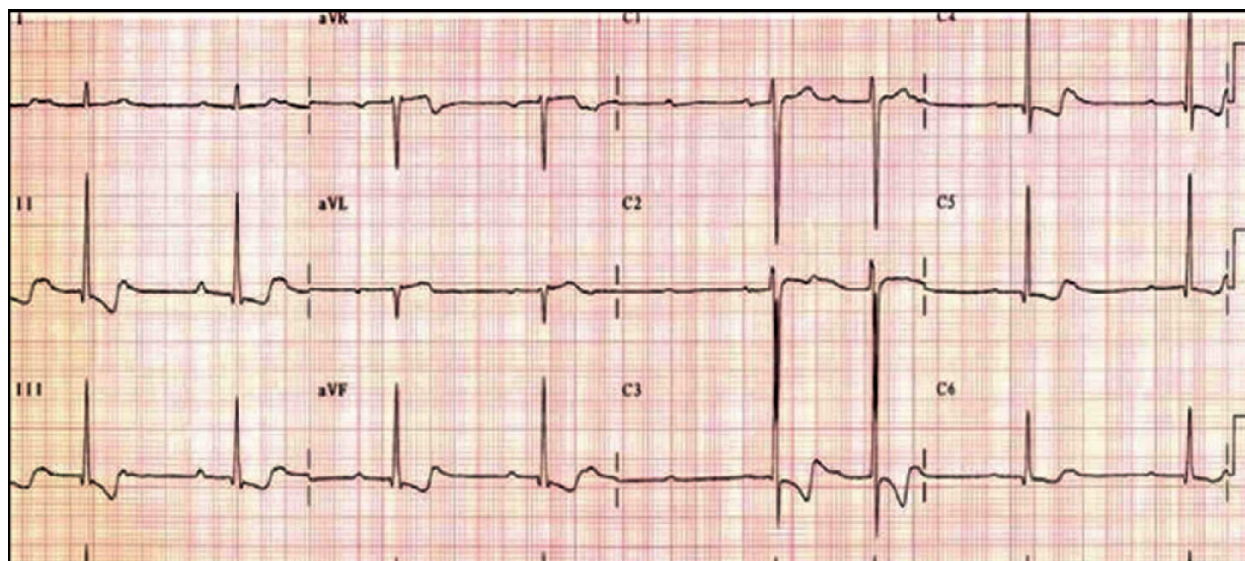


Fig. 1: ECG showing second degree heart block with Reverse tick sign/ Salvador dali appearance.

DISCUSSION

Vomiting, diarrhea, weakness and confusion are typical presentations with this poisoning. Reversible inhibition of the Na⁺/K⁺ ATPase pump leads to hyperkalemia which, in acute ingestions, correlates with cardiac toxicity. Patients may develop bradycardia with AV block, atrial tachycardias, ventricular tachycardia including bidirectional ventricular tachycardia and ventricular fibrillation. Sinus bradycardia and second degree heart blocks were the most common arrhythmias followed by junctional arrhythmias.² The dose administration of atropine was boluses of (0.6–2.0) mg with a target heart rate of 80/min.³ Hyperkalemia is due to extracellular shift of potassium rather than an increase in total body potassium and is best treated with insulin dextrose infusion. The role of calcium is controversial in management of hyperkalemia due to cardiac glycoside poisoning. It results in a dose dependent increase in intracellular calcium ions which results in calcium overload and cessation of cardiac contraction.⁴ Intravenous calcium also increases the risk of cardiac arrhythmias and is not recommended in treating hyperkalemia. Hypomagnesaemia should be corrected as it can worsen cardiac glycoside toxicity.⁵

CONCLUSION

T. peruviana poisoning is most prevalent in India and Southeast Asia where intentional ingestion of the seeds by suicidal adolescents and adults commonly occurs. Ingestion of 5 to 15 N. oleander leaves or 8 to 10 *T. peruviana* seeds can be fatal in an adult. Digoxin specific Fab fragments are not always available for treatment of serious poisoning. In resource limited settings, we suggest the modified combination therapy for treatment of serious cardiac glycoside poisoning. Severe atrioventricular block can be treated with atropine and if it is not responsive to atropine, cardiac pacing is an option. Ventricular tachycardia can be treated with low dose cardioversion (eg, 0.25 to 0.5 joules/kg) and ventricular fibrillation with low dose defibrillation (eg, 2 joules/kg, maximum dose 100 joules) in this poisoning.

REFERENCES

1. De Silva HA, Fonseka MM, Pathmeswaran A, Alahakone DG, Ratnatilake GA, Gunatilake SB, Ranasinha CD, Lalloo DG, Aronson JK, De Silva HJ. Multiple-dose activated charcoal for treatment of yellow oleander poisoning: a

- single-blind, randomised, placebo-controlled trial. *The Lancet*. 2003 Jun 7;361(9373):1935-8.
2. Pandit VR, Kadiravan T, KNJ PR. Cardiac arrhythmias, electrolyte abnormalities and serum cardiac glycoside concentrations in yellow oleander (*Cascabelathevetia*) poisoning-a prospective study. *Clinical toxicology (Philadelphia, Pa.)*. 2018 Aug 3;57(2):104-11.
 3. Fonseka MM, Seneviratne SL, De Silva CE, Gunatilake SB, De Silva HJ. Yellow oleander poisoning in Sri Lanka: outcome in a secondary care hospital. *Human & experimental toxicology*. 2002 Jun;21(6):293-5.
 4. Poindexter BJ, Feng W, Dasgupta A, Bick RJ. Oleandrin produces changes in intracellular calcium levels in isolated cardiomyocytes: a real-time fluorescence imaging study comparing adult to neonatal cardiomyocytes. *Journal of Toxicology and Environmental Health, Part A*. 2007 Feb 13;70(6):568-74.
 5. Rajapakse S. Management of yellow oleander poisoning. *Clinical Toxicology*. 2009 Mar 1;47(3):206-12.

