

Post Covid Acute Necrotizing Pancreatitis

Arun Kaushik¹, Kishalay Datta², Anita Rawat³, Ashar Khan⁴

Author's Affiliation:

^{1,4} Emergency Medicine Resident, ²Associate Director and HOD, ³Senior Consultant, Department of Emergency Medicine, Max Hospital, Shalimar Bagh, New Delhi 110088, India.

Corresponding Author:

Kishalay Datta, Associate Director and HOD, Department of Emergency Medicine, Max Hospital, Shalimar Bagh, New Delhi 110088, India.

E-mail: drkishalay@gmail.com

Received on 02.02.2021, Accepted on 31.03.2021

How to cite this article:

Arun Kaushik, Kishalay Datta, Anita Rawat et al / Post Covid Acute Necrotizing Pancreatitis. Indian J Emerg Med. 2021;7(1):35-38.

Abstract

The Coronavirus Pandemic began in China in December 2019. In a short time, this pandemic spread globally. World has been challenged by SARS COV-2, a new virus causing pneumonia and acute respiratory distress syndrome. There is lack of literature implicating COVID-19 in Pancreatitis, yet virus is generally understood to be a cause of pancreatitis in children. We present a case of previously well 12-year-old girl who presented to emergency department with a chief complain of abdominal pain, anorexia and bilious vomiting. She was diagnosed with acute pancreatitis with an abnormal lipase, ultrasound and computed tomography and was found to be COVID-19 positive by polymerase chain reaction. Our case suggest that in current pandemic, consideration for SARS COV-2 testing in children with gastrointestinal symptoms and pancreatitis may be considered. Additionally, this case highlights the need for appropriate personal protective equipment for providers, even when COVID is not initially on the differential.

Keywords: Pandemic; Covid 19; Acute Pancreatitis; Pediatric.

Introduction

Coronavirus disease 2019 (COVID-19) is an infectious disease caused by severe acute respiratory syndrome virus coronavirus 2 (SARS-CoV-2). The disease was first seen in December 2019 in Wuhan, and has been spreading globally, resulting in an global pandemic. Since its discovery, there has been scientific pressure to characterize the symptomatology caused by SARS COV-2 virus. Common symptoms in pediatric population include fever (36-80%), dry cough (1965), tachycardia (42), tachypnea (29%) and less commonly diarrhea, vomiting, and abdominal pain (4-10%). A majority

of pediatric patients presenting with SARS COV-2 present with mild symptoms including acute URI, fever, fatigue, myalgia, nausea, vomiting, abdominal pain and diarrhea.

Acute pancreatitis in children occurs in approximately 1/10,000 children per year. Viral infections are identified as a cause of acute pancreatitis in approximately 8-10% of cases in children with other common cause being biliary/obstructive, medications, trauma.

Case Report

We present a case of a previously well 12-year-

old girl who initially complained of 48 hours of abdominal pain and anorexia. She was afebrile, with elevated lipase (676, normal 80-360 U/L) and an abdominal ultrasound and CT suggestive of necrotizing pancreatitis. The lower chest on the abdominal CT showed a normal-sized heart, small bilateral pleural effusions, and clear lung bases. Her pancreatitis was managed with IV fluids, ketorolac, and hydralazine; she was started on ceftriaxone and metronidazole. She improved with supportive care and was discharged on hospital day 4 with a normal lipase. Two weeks later her abdominal pain returned and was associated with reported fever (101°F).

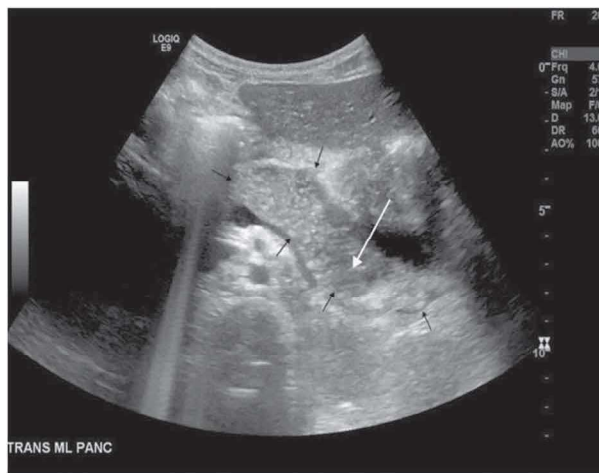


Fig. 1: Usg (at level of pancreas).

Midline transverse grayscale sonographic image at the level of the pancreas (black arrows) reveals diffuse pancreatic enlargement and heterogeneous pancreatic echogenicity (white arrow) concerning for acute pancreatitis. (Fig. 1)

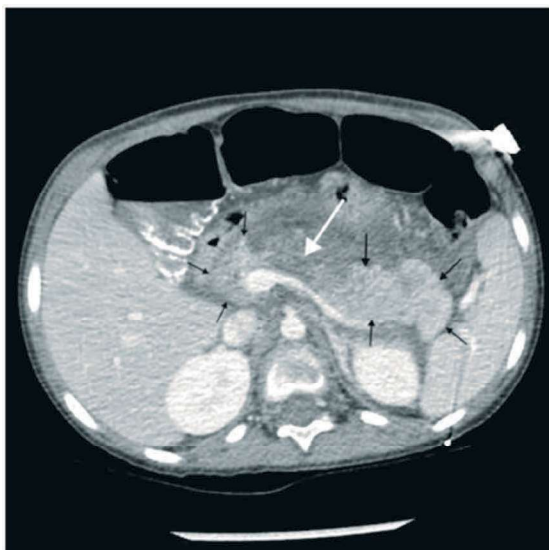


Fig. 2: Post-Contrast Ct (at level of pancreas)

Postcontrast axial CT image at the level of the pancreas (black arrows) reveals diffuse pancreatic edema/enlargement with peripancreatic fluid and increased attenuation of the adjacent peripancreatic fat representing acute pancreatitis. An area of pancreatic parenchymal hypoenhancement (white arrow) is suspicious for pancreatic necrosis (necrotizing pancreatitis).

Simultaneously, her mother, a warehouse worker was experiencing fever, cough, and shortness of breath. Our patient denied shortness of breath or cough. She also presented with nonbloody, nonbilious emesis left lower quadrant, and epigastric pain. (Fig. 2)

On examination, her vital signs were BP: 130/92, P: 128, T: 99.9°F, RR: 24, BMI 13.79. She appeared uncomfortable, but nontoxic. Her abdominal exam was significant for distension and tenderness to palpation in the left upper and left lower quadrant, and the epigastric regions. There was fullness noted in the left upper, but no splenic edge was felt and there was no guarding, rebound, right lower quadrant tenderness, Rovsing, or psoas sign.

Her lipase this time was 1672 U/L, and due to fever and potential family exposure in a COVID-19 pandemic she was tested for SARS CoV-2 by polymerase chain reaction which was positive. She had thrombocytosis (498 thou/cmm), an elevated LDH (271 U/L), and an elevated IL-6 (13 pg/mL). A complete respiratory viral panel was negative including influenza A, B and RSV. She was managed again with bowel rest, IV, ketorolac, acetaminophen, and ceftriaxone and metronidazole until blood cultures returned. Over the next 2 days, she improved significantly and was discharged with a lipase that was trending down. Of note, the patient's mother, her mother's partner, and her older sister all tested positive for COVID-19 after the patient.

Discussion

Several aetiological factors are described for acute pancreatitis. The most common causes for acute pancreatitis are gallstones and heavy alcohol consumption.¹ However, in 10%–20% of cases an aetiological factor cannot be identified.² The patient denied excessive alcohol intake and an ultrasound scan did not show any evidence of gallstones.

A number of infectious agents, including viruses, parasites and bacteria are known to infect the pancreas.³ Viral pancreatitis has been extensively described in literature to be most ordinarily caused

by mumps, Coxsackie B virus and hepatitis A virus.⁴ there have been neither reasons for clinical suspicion, nor evidence of the above-mentioned viruses in our case. This increases the suspicion of COVID-19-induced pancreatitis. Corona virus or corona virus-like virus has been identified in pigeons with severe pancreatitis but no similar studies are wiped out humans.⁵

A study of 52 patients with COVID-19 pneumonia showed that there was a 17% incidence of pancreatic injury. This study defined pancreatic injury as any abnormality within the serum amylase or lipase level.⁶ However, it's known that the pancreas isn't the sole source of the pancreatic enzymes (PE) amylase and lipase. For example, gastroenteritis may be a well-recognised explanation for raised PE. Furthermore, a meta-analysis of patients with COVID-19 showed that 18% had gastrointestinal symptoms.⁷ This indicates that raised PE in patients with COVID-19 cannot be directly attributed to pancreatitis.

In the previous global outbreak of severe acute respiratory syndrome (SARS) caused by SARS-associated coronavirus (SARS-CoV) in 2003, studies were done using immunohistochemistry and in place hybridisation on autopsy samples of patients who died of SARS-CoV. These showed the presence of SARS-CoV antigen and RNA in pancreatic tissue.⁸ Genome sequences of SARS-CoV and SARS-CoV-2 are almost identical and share a 79.6% sequence identity.⁹ In a study that explored the expression and distribution of ACE2 receptor of SARS-CoV-2, it had been reported that ACE2 is expressed more within the pancreas than the lungs. This potentiates the pancreas as a target for SARS-CoV-2. Although the precise pathogenesis of pancreatitis caused by COVID-19 is unclear, it's thought to develop from the direct cytopathic effect mediated by the local replication of SARS-CoV-2.

The most serious complication of COVID-19 is sepsis-like inflammation leading to a dysregulated inflammatory response resulting in a cytokine storm. Excessive systemic inflammatory response syndrome in acute pancreatitis results in distant organ damage and multiple organ dysfunction. Inflammatory mediators such as tumour necrosis factor-alpha, interleukin (IL)-6 and IL-10 play a critical role in the inflammatory response of both acute pancreatitis and COVID-19. Coexisting pancreatitis and COVID-19 cause an accelerated clinical course and should be extremely challenging for the clinician to handle. In cases of ANP complicated by a secondary infection, interventions like necrosectomies could also be warranted. Such

procedures pose as increased risks to the surgeon. This is thanks to the very fact that SARS-CoV-2 is prevalent throughout the alimentary canal and peritoneal fluid features a higher viral load than the upper respiratory secretions. The risk of exposure to healthcare workers is far higher in aerosol-generating procedures like endoscopic or minimally invasive drainage/necrosectomy.

In conclusion, this report highlights the importance of the consideration of COVID-19 as a possible cause in patients presenting with idiopathic pancreatitis, especially during the pandemic. Operating surgeons and interventional radiologists who are involved in handling complications related to pancreatitis got to remember of the danger of infection.

Conflict of Interest

None declared

References

1. Forsmark CE, Swaroop Vege S, Wilcox CM. Acute pancreatitis. *N Engl J Med Overseas Ed* 2016;375:1972-81.doi:10.1056/NEJ Mra 1505202 Google Scholar
2. Whitcomb DC. Acute pancreatitis. *N Engl J Med Overseas Ed* 2006;354:2142-50.doi:10.1056/NEJMcp054958 Google Scholar
3. Steinberg W, Tenner S. Acute pancreatitis. *N Engl J Med* 1994;330:1198-210.doi:10.1056/NEJM199404283301706pmid:http://www.ncbi.nlm.nih.gov/pubmed/7811319 Cross Ref Pub Med Web of Science Google Scholar
4. Kottanattu L, Lava SAG, Helbling R, et al. Pancreatitis and cholecystitis in primary acute symptomatic Epstein-Barr virus infection - Systematic review of the literature. *J Clin Virol* 2016;82:515.doi:10.1016/j.jcv.2016.06.017pmid:http://www.ncbi.nlm.nih.gov/pubmed/27434148 Pub Med Google Scholar
5. Qian DH, Zhu GJ, Wu LZ, et al. Isolation and characterization of a coronavirus from pigeons with pancreatitis. *Am J Vet Res* 2006;67:15759. doi:10.2460/ajvr.67.9.15759pmid:http://www.ncbi.nlm.nih.gov/pubmed/16948604 Pub Med Google Scholar
6. Wang F, Wang H, Fan J, et al. Pancreatic injury patterns in patients with coronavirus disease 19 pneumonia. *Gastroenterology* 2020;159:36770. doi:10.1053/j.gastro.2020.03.055pmid:http://www.ncbi.nlm.nih.gov/pubmed/32247022 Pub Med Google Scholar
7. Cheung KS, Hung IFN, Chan PPY, et al. Gastrointestinal manifestations of SARS-CoV-2 infection and virus load in fecal samples from

- a Hong Kong cohort: systematic review and meta-analysis. *Gastroenterology* 2020;159:8195. doi:10.1053/j.gastro.2020.03.065pmid:http://www.ncbi.nlm.nih.gov/pubmed/32251668CrossRefPub MedGoogle Scholar\
8. Ding Y,He L,Zhang Q, et al. Organ distribution of severe acute respiratory syndrome (SARS) associated coronavirus (SARS-CoV) in SARS patients: implications for pathogenesis and virus transmission pathways. *JPathol* 2004;203:62230. doi:10.1002/path.1560pmid:http://www.ncbi.nlm.nih.gov/pubmed/15141376 Cross Ref Pub Med Web of Science Google Scholar
9. Zhou P,Yang X-L,Wang X-G, et al. A pneumonia outbreak associated with a new coronavirus of probable bat origin. *Nature* 2020;579:270-3. doi:10.1038/s41586-020-20127pmid:http://www.ncbi.nlm.nih.gov/pubmed/32015507 Cross Ref Pub Med Google Scholar

