

Case Report

Amyloidosis of Urinary Bladder

Archana N Rijhsinghani

Consultant Histopathologist, Department of Histopathology, SRL Diagnostics Dr Avinash Phadke lab, Dadar, Mumbai 400028, India.

Corresponding Author:

Archana N Rijhsinghani, Consultant Histopathologist, Department of Histopathology, SRL Diagnostics, Dr Avinash Phadke lab, Dadar, Mumbai 400028, India.

E-mail: archana2188@gmail.com

Abstract

Primary urinary bladder localised amyloidosis is a very uncommon condition and can appear like a neoplastic etiology clinically and radiologically. Hence, histological examination is necessary for confirmation of diagnosis. Further investigation is necessary to exclude systemic amyloidosis.

Key words: Primary; Amyloidosis; urinary bladder.

How to cite this article:

Archana N Rijhsinghani/ Amyloidosis of Urinary Bladder/ Indian J Pathol Res Pract. 2021;10(1):51-52.

Introduction

Amyloidosis occurs due to disordered protein metabolism. Amyloid protein fibrils deposits in extracellular spaces of different body tissues. It can be localised to a single organ or present as a systemic disorder. Primary localised amyloidosis of the urinary bladder was first described by Solomin in 1897.¹

Amyloid deposits in urinary tract, kidney, renal pelvis, bladder, urethra, and penile tissues. On cystoscopy and radiology, it mimicks tumor, and thus microscopic examination of Congo red stained of biopsy specimens is used as the gold standard diagnostic method.²

Case Report

48 years-old/ male presented with painless hematuria since last 7 days, with no other significant past medical or surgical history. Urine

routine examination revealed pus cells (10-15/hpf), red blood cells (400-500/hpf), protein (+++), sugar absent. Urine cytology was negative for malignancy.

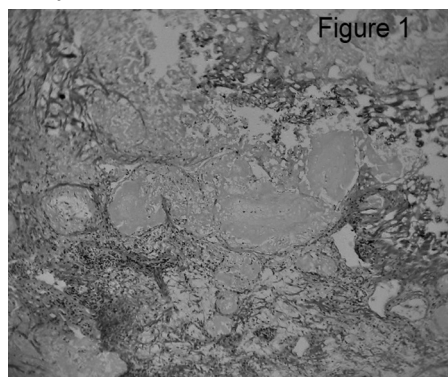


Fig. 1: (HEX100) Eosinophilic acellular amorphous material beneath the denuded and cauterised surface epithelium.

Cystoscopy revealed nodular lesions in posterior urinary bladder wall ranging from 0.2 to 1.5cms, over an area of 3 x 2 cms, suspicious of neoplastic

etiology. Biopsy of this lesion was performed and revealed deposits of eosinophilic acellular amorphous material (Figure1) beneath the denuded and cauterised surface epithelium, within the lamina propria, in the muscularis propria and in the vessel wall.




Fig. 2: (Congo red x400) Bright staining with Congo red.

The deposits stained brightly with Congo red stain (Figure 2) and apple green birefringence was noted on polarized microscopy. The final diagnosis of Amyloid deposits in urinary bladder wall was given.

Further work up turned out to be negative on bone marrow biopsy, rectal biopsy and fat pad examination. Patient was treated with transurethral resection and was disease free on two years follow up. Thus ours was a case of primary localised urinary bladder amyloidosis.

Discussion

Amyloidosis is a non-neoplastic disease and shows localised or multisystem deposition of extracellular fibrillar protein in tissues. Primary amyloidosis localized in the bladder is very rare and may mimic bladder cancer at presentation.²

Amyloidosis first described by Virchow in 1853. In the urinary tract, amyloid deposition usually starting from kidney to renal pelvis, ureters, urinary bladder and urethra. The kidney is nearly always involved in secondary amyloidosis and in around 50% of primary amyloidosis cases.

However, urinary bladder is usually affected in primary localized amyloidosis.

Primary amyloidosis affecting only the bladder may be easily confused with an infiltrating tumor on imaging and cystoscopy. Accurate diagnosis depends on biopsy of the bladder lesion. Patients usually presents with painless hematuria.

Cystoscopy shows nodular-to-polypoidal, single or multiple masses.³

Histological examination successfully diagnose the condition, which will be confirmed by the apple-green birefringence on Congo red staining when viewed with polarised light.

Further work up to exclude systemic amyloidosis is essential as treatment differs on diagnosis of systemic illness.

Treatment of localised bladder amyloid is by transurethrally resection of lesions and subsequent cystoscopic follow up, as recurrence rate is 50%. Previous authors have suggested follow up with cystoscopy every 1-3 years.⁴

Conclusion

Histologic examination in cases of amyloidosis presenting with hematuria and showing bladder lesions/masses on cystoscopic examination is essential, which raises suspicion of neoplastic pathology. It is important to diagnose this condition as it can have systemic involvement, thus changing the management altogether.

References

1. Gomha FS, Smain AM, Sohail N, Yousif AA, Abdelrahman KM, Amir E, Bhatti KH. Primary localised amyloidosis of the urinary bladder: a recurrent and progressive disease. *J Taibah Univ Med Sci.* 2018;13(4):398-401.
2. Bayrak Ö, Bozdağ Z, Urgan G, Yağcı F. Primary amyloidosis of the bladder mimicking bladder tumor. *Turk J Urol.* 2014;40(1):59-61.
3. Altwairgi A. Primary amyloidosis of the urinary bladder presenting as painless hematuria. *Int J Health Sci (Qassim).* 2011;5(2):181-5.
4. Ho A, Davies MC, Guran R, Brewin J. Primary amyloidosis of the bladder. *Urol Case Rep.* 2018;17:111-113.

