

## Original Research Article

## Prevalence of Adenomyosis, Leiomyomas and Their Concomitance in Hysterectomy Specimens: A Study from Rural Center in South India

Anusha N

<sup>1</sup>Associate Professor, Department of Pathology, Vinayaka Missions Medical College, Karaikal, Puducherry 6096W09, India.

**Corresponding Author:**

Anusha N, Associate Professor, Department of Pathology, Vinayaka Missions Medical College, Karaikal, Puducherry 609609, India.

E-mail: drgrwife@yahoo.com

Received on 05.03.2020

Accepted on 14.03.2020

**Abstract**

*Background:* It is not uncommon for most women to suffer from abnormal uterine bleeding (AUB) at some point of their lifetime which results in anemia, interferes with daily activities and raises concern about uterine cancer and they frequently undergo hysterectomy in our country. *Aim and Objective:* 1. To evaluate the prevalence of adenomyosis, leiomyomas and of their concomitance in hysterectomy specimens. 2. To study the type of leiomyomas on the basis of their location in uterus. *Materials and Methods:* A retrospective study of 120 pathological specimens those underwent hysterectomy during the period of January 2015 to December 2018. Data including age, symptoms and clinical indication for hysterectomy was collected for the study. The specimens were processed routinely and stained with haematoxylin and eosin stain and examined microscopically. We looked for prevalence of adenomyosis alone, of leiomyomas alone and of their concomitance were evaluated. *Results:* Mean age of the patients was 45.2 years. Pathological findings included adenomyosis in 25%, leiomyoma in 60%, and both in 15%. 72 specimens had fibroid which were evaluated for number and its location. *Conclusion:* leiomyoma was the most common histopathological finding in hysterectomy specimens and prevalence of adenomyosis in our study was nearly equal. So gynecologist must pay attention to adenomyosis as one of the common underlying causes of AUB.

**Keywords:** Hysterectomy; Abnormal Uterine Bleeding; Adenomyosis Leiomyoma.

**How to cite this article:**

Anusha N. Prevalence of Adenomyosis, Leiomyomas and Their Concomitance in Hysterectomy Specimens: A Study from Rural Center in South India. Indian J Pathol Res Pract. 2020;9(1 Part II):135-139.

**Introduction**

Abnormal uterine bleeding affects large number of people on regular basis with consequences at both individual and social levels. The diagnosis of AUB can be made when conditions within the acronym PALM-COEIN are implicated. - PALM (polyps, adenomyosis, leiomyoma, malignancy) and

COEIN (coagulopathies, ovulatory dysfunction, endometrial, iatrogenic, not otherwise classified).<sup>1,2</sup> The treatment success will ultimately improve physical, emotional, social and material quality of life of a woman.<sup>3</sup> Though large number of new promising techniques like endometrial ablation, thermal balloon therapy and uterine artery embolization are available for AUB, due to cost

factor and limited availability in our country hysterectomy is the ultimate and widely accepted treatment for AUB for any cause.<sup>4</sup>

Uterine adenomyosis is a pathological condition characterized by the presence of endometrial glands and stroma within the myometrium. Its frequency is more common in perimenopausal age group and common in multiparous females. It is also associated with subfertility and women otherwise labelled as having unexplained infertility and its prevalence vary widely from 5 to 70%.<sup>5</sup>

Leiomyoma have high prevalence upto 70% in Caucasians and 80% in women with African ancestry and its clinical presentation depends upon its size and location.<sup>6</sup> The most common symptoms are AUB, pelvic pain and pressure symptoms and it has varying rates of growth even in a single individual.<sup>7</sup>

Our study was a retrospective to find the prevalence of adenomyosis and leiomyoma as a cause of AUB in hysterectomy specimens, as both the entities are most common cause of the same and have a similar clinical presentation, unfortunately which cannot be differentiated and requires histopathological examination.

## Materials and Methods

The study was retrospective, conducted in department of pathology, vinayaka missions medical college and hospital, Karaikal between January 2015 to December 2018. During four years 176 hysterectomy specimens were received in our department and 120 were included in our study. We had inclusion and exclusion criteria.

### Inclusion criteria

1. Woman with complaint with AUB, pelvic pain and pressure symptoms
2. Patient whose endometrial biopsy was inconclusive for AUB and underwent hysterectomy.
3. Women between age group of 30 to 70 years both pre and post menopausal.

### Exclusion criteria

1. Adenomyosis and myomas associated with any other uterine pathology
2. Malignancies.

The data retrieved included patient's age, symptoms, sonography reports and clinical indication of hysterectomy. The specimen was grossly examined for any apparent abnormality. Fibroid, polyp, asymmetrical enlargement of the whole uterus, hemorrhage, necrosis and endometrial thickening was noted. Leiomyoma was recorded on the basis of number, size and location in the cut sections. The specimens were processed routinely and stained with haematoxylin and eosin stain and examined microscopically. A minimum of two sections were taken from cervix and the corpus, one section each from both tubes and ovaries and additional section was taken from leiomyoma or any other abnormality. The adenomyosis was diagnosed using following criteria.<sup>8</sup>

1. Grossly-pinpoint/small cystic areas of hemorrhage seen within the myometrium.
2. Microscopic criteria - the presence of endometrial glands and stroma in the myometrium more than one low power field away from the endomyometrial junction.

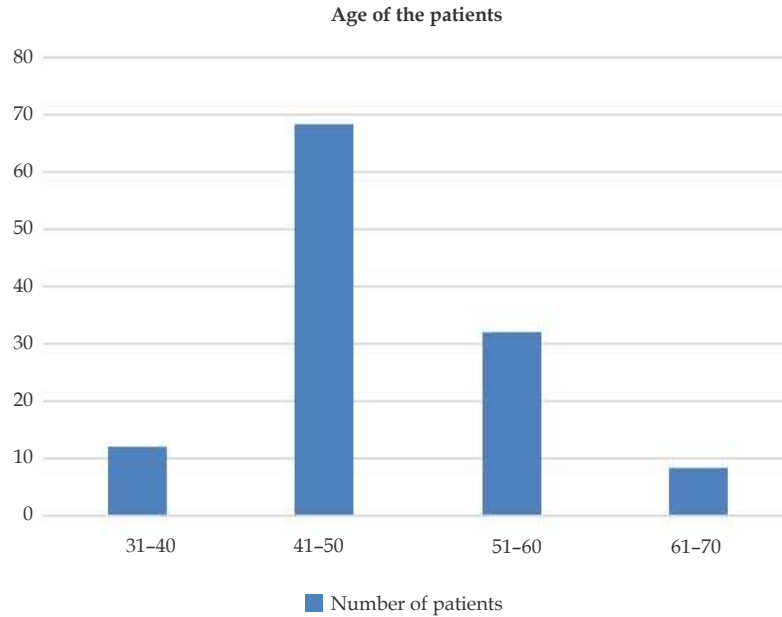
We looked for the prevalence of adenomyosis alone, leiomyomas alone and their concomitance in our study. Data were statistically evaluated with IBM SPSS statistics for windows, version 20, IBM corp, Chicago, Illinois

## Results

A total of 120 cases were evaluated in our study. Mean age of the patients was 45.2 years. Age of the patients ranged from 30 to 70 years (Fig. 1). Pathological findings included adenomyosis in 25% ( $n = 30$ ), leiomyoma in 60% ( $n = 72$ ), and both in 15% ( $n = 18$ ). In our study most cases had leiomyoma as a histopathological lesion who presented with AUB (Table 1). The largest group 56.6% ( $n = 68$ ) was in the perimenopausal age group (41–50 years).

**Table 1:** Distribution of patients according to the histopathological lesion

S. No.	Age in years	leiomyoma	Adenomyosis	Concomitance
1	31–40	8	3	1
2	41–50	43	15	10
3	51–60	17	10	5
4	61–70	4	2	2
	<b>Total</b>	72	30	18



**Fig. 1:** Age distribution of patients with AUB

In our study we looked for locations of fibroids in hysterectomy specimens. Intramural and submucous fibroid was nearly equal in number. Subserous fibroid was the least. 15.2% of patients

had fibroid in all three layers of the uterus (Table 2).

In our study most patients had single fibroid. 25% of patients had multiple fibroids (Table 3).

**Table 2:** Leiomyoma Based on Location in Uterus

S. No.	Location	Number	Percentage
1	SubMucous	15	20.9
2	Intra Mural	16	22.3
3	Sub Serous	2	2.7
4	Sub Mucous (+) Intra Mural	13	18.0
5	Sub Serous (+) Intra Mural	9	12.5
6	Sub Mucous + Sub Serous	6	8.4
7	Sub Mucous + Sub Serous + Intra Mural	11	15.2
	<b>Total</b>	72	100.0

**Table 3:** Leiomyoma Uterus Based on Number

S. No.		Number	Percentage
1.	Single	30	41.6
2.	Two	24	33.4
3.	Multiple	18	25.0
	<b>Total</b>	72	100.0

All patients underwent abdominal sonography and only small number of patients 43% ( $n = 52$ ) undergone Trans Vaginal Sonography (TVS) preoperatively. The diagnostic findings correlated well with histopathological findings in 60 cases of fibroid uterus, 28 cases of adenomyosis and 8 cases of dual pathology. The clinicopathological

correlation was better for leiomyoma (83.3%) than adenomyosis (70%).

We also looked for correlation of histopathological lesion with the presenting symptoms. Most patients had AUB. Pressure symptoms were the least. Few patients had both or all three symptoms together (Table 4).

**Table 4:** Presenting Symptoms Based on Number

Presenting symptoms	Leiomyoma	Adenomyosis	Concomitance
AUB	60	38	18
Pelvic pain	22	10	12
Pressure symptoms	18	2	8

## Discussion

Abnormal uterine bleeding is often an early sign of menopause and it is suspected when bleeding occurs in irregular times and in excessive amounts.<sup>9,10</sup> It is diagnosed when all other possible causes associated with PALM-COEIN after thorough clinical history regarding menstrual flow, physical examination, laboratory evaluation, sonography and endometrial sampling. The treatment modalities include, NSAIDs, oral contraceptive pills, hormonal therapy, dilatation and curettage, endometrial ablation, etc. If all these modalities fail, women finally end up with traditional surgical treatment, the hysterectomy.<sup>11</sup>

In our study fibroids were more common accounting to 60% and most common presenting symptom was AUB. The relationship between AUB and fibroids remain incompletely understood. Many postulated theories say fibroids increase the size of uterus and its endometrial surface area resulting in endometrial hyperplasia, hyperestrogenism and vascular alterations in uterus by fibroid leading to dilation of venules resulting in congestion of myometrium and endometrium. The end result is fragile engorged vasculature in the perimyoma environment resulting in AUB.<sup>12-15</sup>

The prevalence of adenomyosis alone in our study was 25%. Similar prevalence was reported in other studies like Sharqill et al. (26%) and Vavilis (24.9%).<sup>16,17</sup> The adenomyosis being asymptomatic, is not clinically diagnosed routinely. Various factors such as hyperestrogenism, multiparity, prior uterine surgeries are possible etiological factors. The clinical symptoms include AUB, intermenstrual pelvic pain, subfertility, infertility and dyspareunia. It is a diagnosis of exclusion.<sup>18</sup>

Fibroids on the other hand get detected easily on sonography and gynecologist are more familiar to suspect fibroids for AUB rather than adenomyosis. It can be missed histopathologically also if limited tissue sections are taken in cases with no clinical suspicion. Though MRI is helpful in diagnosing adenomyosis, cost factor and availability in most medical center limits its utility.<sup>19,20</sup> The concomitance of adenomyosis and leiomyoma was 15%.

The limitation of our study was, small sample size, it was retrospective, single centered. We did not include adenomyosis and leiomyoma associated with any other uterine pathologies.

## Conclusion

The overall prevalence of adenomyosis in our study was 40%. In hysterectomy specimens of women with AUB in perimenopausal age group both the clinician and pathologist should have high suspicion of adenomyosis. AUB without any important ultrasonographic findings can still be medically treated by gynecologist and delay hysterectomy unless there is no alarming symptoms. However, the approach of the treatment needs further prospective cohort studies in large numbers.

## References

- Munro MG, Critchley HO, Broder MS, et al. Disorders FWGoM. FIGO classification system (PALM-COEIN) for causes of abnormal uterine bleeding in nongravid women of reproductive age. *Int J Gynaecol Obstet* 2011;113:3-13. <https://www.ncbi.nlm.nih.gov/pubmed/21345435>
- Munro MG, Critchley HO, Fraser IS. Group FMDW. The FIGO classification of causes of abnormal uterine bleeding in the reproductive years. *Fertil Steril* 2011 Jun;95(7):2204-8, 2208.e1-3. <https://www.ncbi.nlm.nih.gov/pubmed/21496802>
- Thomas SL, Ellertson C. Nuisance or natural and healthy: should monthly menstruation be optional for women. *Lancet* 2000;355:922-4. <https://www.ncbi.nlm.nih.gov/pubmed/10752720>
- Bhosle A, Fonseca M. Evaluation and histopathological correlation of abnormal uterine bleeding in perimenopausal women. *Bombay Hosp J* 2010;52:69-72. <http://www.ijmsph.com/fulltext/67-1492829885.pdf>
- Dueholm M. Transvaginal ultrasound for diagnosis of adenomyosis: A review. *Best Pract Res Clin Obstet Gynaecol* 2006;20:569-82. <https://www.ncbi.nlm.nih.gov/pubmed/16545618>
- DD Baird, Dunson DB, Hill MC, et al. High cumulative incidence of uterine leiomyoma in black

- and white women: Ultrasound evidence. *Am J Obstet Gynecol* 2003;188:100-7. <https://www.ncbi.nlm.nih.gov/pubmed/12548202>
7. Rizvi G, Pandey H, Pant H, et al. Histopathological correlation of adenomyosis and leiomyoma in hysterectomy specimens as the cause of abnormal uterine bleeding in women in different age groups in the Kumaon region: A retrospective study. *J Midlife Health* 2013;4(1):27-30. doi:10.4103/0976-7800.109631 <https://www.ncbi.nlm.nih.gov/pubmed/23833530>
  8. A Maheshwari, S Gurunath, F Fatima. Adenomyosis and subfertility: a systematic review of prevalence, diagnosis, treatment and fertility outcomes, *Human Reproduction Update* July 2012;18(4):374-92, <https://doi.org/10.1093/humupd/dms006>
  9. Shapley M, Jordan K, Croft PR. An epidemiological survey of symptoms of menstrual loss in the community. *Br J Gen Pract* 2004;54:359-63. <https://www.ncbi.nlm.nih.gov/pubmed/15113519>
  10. Hallberg L, Hogdahl AM, Nilsson L, et al. Menstrual blood loss: A population study. Variation at different ages and attempts to define normality. *Acta Obstet Gynecol Scand* 1966;45:320-51. <https://www.ncbi.nlm.nih.gov/pubmed/5922481>
  11. Finco A, Centini G, Lazzeri L, et al. Surgical management of abnormal uterine bleeding in fertile age women. *Womens Health (Lond)* 2015;11:513-25. <https://www.ncbi.nlm.nih.gov/pubmed/26238216>
  12. Donnez J, Dolmans MM. Uterine fibroid management: from the present to the future. *Hum Reprod Update* 2016. <https://www.ncbi.nlm.nih.gov/pubmed/27466209>
  13. Rashida Hafiz, Muhammad Ali, Mansoor Ahmad. Fibroid as a causative factor in menorrhagia and its management. *Pakistan J Med Res* 2003;42:90-6.
  14. Munro MG. *Rev Endocr Metab Disord* 2012 Dec;13(4):225-34. doi: 10.1007/s11154-012-9220-x. <https://www.ncbi.nlm.nih.gov/pubmed/22851041>
  15. Donnez J, Tomaszewski J, Vázquez F; PEARL II Study Group. *N Engl J Med*. 2012 Feb 2;366(5):421-32. doi: 10.1056/NEJMoa1103180. <https://www.nejm.org/doi/full/10.1056/NEJMoa1103180>
  16. Sharqill SK, Sharqill HK, Gupta M, Kaur S. A clinicopathological study of hysterectomy. *J Indian Med Assoc* 2002;100:238-9. <https://www.ncbi.nlm.nih.gov/pubmed/12405332>
  17. Vavilis D, Agorastos T, Tzafetas J, et al. Adenomyosis at hysterectomy: Prevalence and relationship to operative findings and reproductive and menstrual factors. *Clin Exp Obstet Gynecol* 1997;24:36-8. <https://www.ncbi.nlm.nih.gov/pubmed/9107456>
  18. Siddegowda MS, Manjunath MR, Shivakumar S. Occurrence of Adenomyosis in Hysterectomy Specimen and its Clinical Correlation in a Tertiary Care Hospital in Mandya, Karnataka, India. *Int J Sci Stud* 2015;3(6):61-64. [https://www.ijss-sn.com/uploads/2/0/1/5/20153321/ijss\\_sep\\_oa14.pdf](https://www.ijss-sn.com/uploads/2/0/1/5/20153321/ijss_sep_oa14.pdf)
  19. Reinhold C, McCarthy S, Bret PM, et al. Diffuse adenomyosis: comparison of endovaginal US and MR imaging with histopathologic correlation. *Radiology*, 1996;199:151-58. <https://www.ncbi.nlm.nih.gov/pubmed/8633139>
  20. Kim SH, Kim JK, Chae HD, et al. Rapidly growing adenomyosis during the first trimester: Magnetic resonance images, *Fertil Steril* 2006;85:1057-58. 10.1016/j.fertnstert.2005.11.036

