

Aggressive Sebaceous Carcinoma of Extremity: A Rare Case Report

Amresh Kumar, Jayeeta Sen, Vividha Dubey, Saurabh Karnawat, Virendra

Author's Affiliation: ¹⁻³Registrar, ⁴Associate Professor, ⁵Professor, Department of Radiation Oncology, Sri Aurobindo Medical College & PG Institute, Indore, Madhya Pradesh 453555, India.

Corresponding Author: Virendra Bhandari, Professor, Department of Radiation Oncology, Sri Aurobindo Medical College & PG Institute, Indore, Madhya Pradesh 453555, India.

E-mail: virencancer@yahoo.co.in

How to cite this article:

Amresh Kumar, Jayeeta Sen, Vividha Dubey et. al. Aggressive Sebaceous Carcinoma of Extremity : A Rare Case Report. Indian J Canc Educ Res 2020;8(1):15-22.

Abstract

Sebaceous carcinoma is an uncommon aggressive malignant tumour derived from the adnexal epithelium of sebaceous gland either from ocular or extraocular sites.

Extraocular sebaceous carcinoma is a rare malignancy when compared to periocular variant. The aggressive types of extraocular sebaceous neoplasm are reported with lymph node and visceral metastasis associated with poor prognosis. Here we report a case of aggressive recurrent extraocular sebaceous cell carcinoma of palm (upper extremity) with recurrence to post op site and ipsilateral axillary lymph node metastasis.¹

Keywords: Sebaceous carcinoma, Upper extremity.

Introduction

Sebaceous carcinoma, first described by Allaire in 1891 accounts for less than 1% of all cutaneous malignancies.² Sebaceous carcinoma either be ocular (75%) or extraocular³ types (25%)⁴ Extraocular sebaceous carcinoma has been reported more commonly on the head and neck region^{4&5} followed by trunk, salivary glands, genitalia, breast, ear canal and intra oral cavity. Extraocular sebaceous carcinoma involving trunk or extremity is very rare but aggressive malignant tumour arising from sebaceous glands. It is more common in sixth decade of life (mean-63 years) with no sex predilection.⁶ Which is also evident with our patient reported at the age of 65 years.

Case Report

A 62 year, old male, presented to us with a complaint of swelling over left forearm which was gradually progressive since 5-6 months. On examination there was a single, non tender, well defined and demarcated swelling over subcutaneous plane of ulnar aspect of forearm with no discharge / bleed. His past medical history was unremarkable and there is no family history of similar lesion or any malignancy. Biopsy revealed poorly differentiated carcinoma. Patient then underwent resection with negative surgical margins and histology was inconclusive.

The patient presented after 2 months after resection with complaint of appearance of a nodular swelling 5 x 3 cm, skin coloured, hard without any signs of

inflammation over skin of left axillary region and ipsilateral axillary lymph node metastasis (fig. 1). A subcutaneous soft tissue nodular lesion 3 x 2 cm on lateral aspect of palmar region, left hand and two other soft tissue lesion 1 x 1 cm at anterolateral aspect of left 4th metacarpophalangeal joint. Patient underwent amputation of left forearm along with left axillary lymph node dissection (fig. 2). The frozen section revealed skin adnexal carcinoma with involvement of medical resection margin shows tumour deposits. In frozen section, tumour composed of round to polygonal cells with high N:C ratio, hyperchromatic nuclei, scanty to moderate cytoplasm; forming lobules, cords and acini, infiltrating subcutaneous tissue (fig. 3). The postoperative course was uneventful. The analysis of surgical specimen revealed sebaceous carcinoma (Grade 2) (fig. 4). Left hand with metastasis to left axillary lymph node with extra nodal extension (pT4 N1b Mx). Tumour infiltrating overlying skin with ulceration LVE +, PNI +, left axillary matted lymph node level 1 and 2 show metastasis with extra nodal extension. Left axillary level 2 lymph node (2/18) showed tumour metastasis. Patient was planned for 1 cycle neoadjuvant chemo with Paclitaxel and Carboplatin followed by EBRT to axilla and then to continue chemo with Paclitaxel and Carboplatin but patient delayed the treatment and reported after 1 and 1/2 month of amputation, to us with multiple tiny nodules over flexor aspect of amputated (fig. 7) left forearm (cutaneous metastasis) then he was planned for EBRT to axilla by photons and EBRT to forearm by electron followed by chemotherapy. Patient was taken to mould room for preparation of mould (fig. 5) to ensure immobilization during the course of treatment. After CT simulation with proper immobilization technique, treatment plan was generated with contoured target volumes and organ at risk. (Fig. 6) He was planned for a prescription dose of 54 Gy/30# (@1.8 Gy/#) to left axilla and 60 Gy/30# (@ 2 Gy/#) to arm using 6 MV photon on DMX Varian Linear accelerator. He tolerated the treatment well. (fig. 8) And is now being treated with chemotherapy with Paclitaxel and carboplatin.

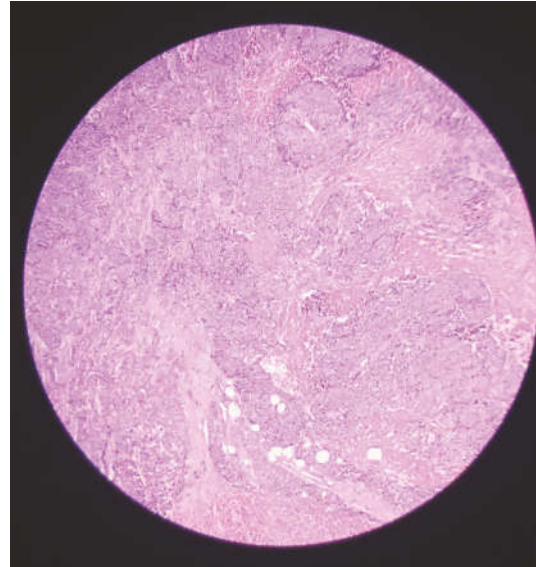


Fig. 1: Frozen Section Histopathology Image.

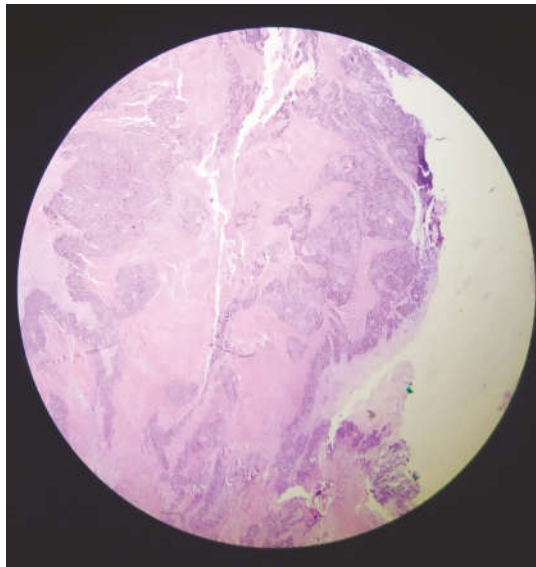


Fig. 2: Post Op Histopathology Image.

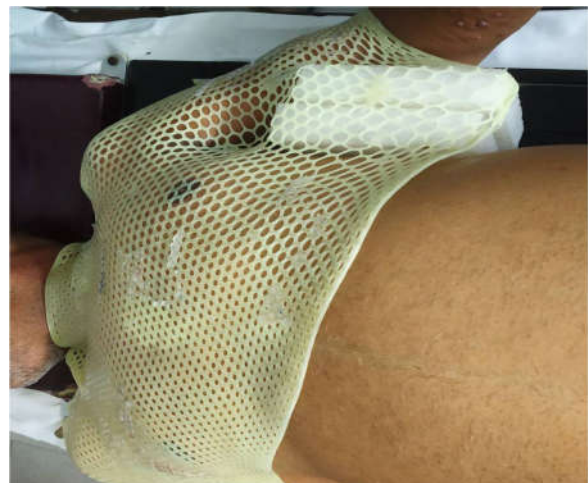

Fig. 3: Mould Preparation.

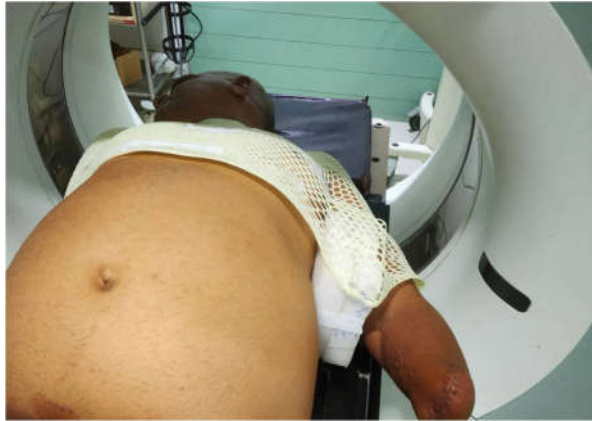

Fig. 4: CT Simulation.

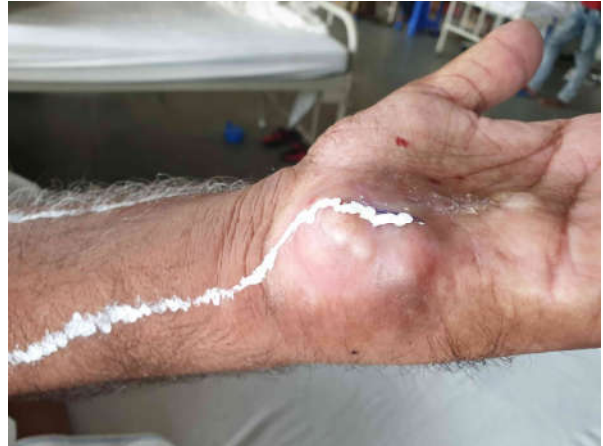

Fig. 7: Nodular Swelling Lt hand Before Excision.

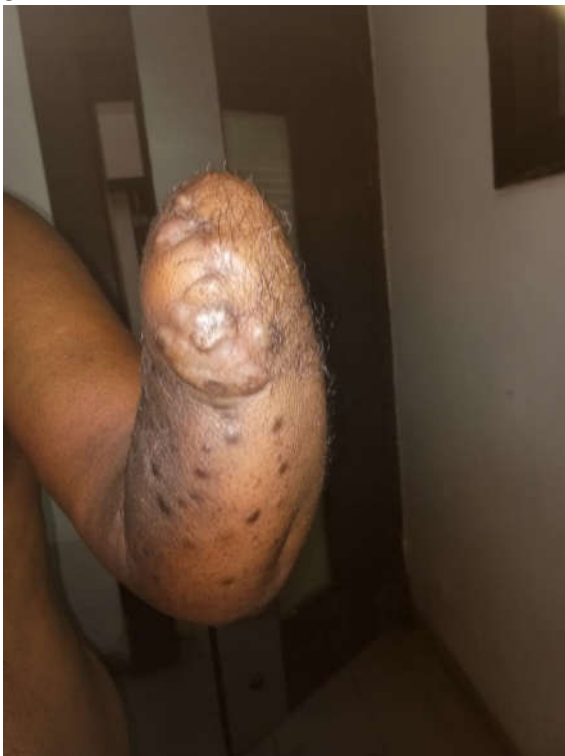

Fig. 5: Image of Amputated arm During Course of Radiotherapy.

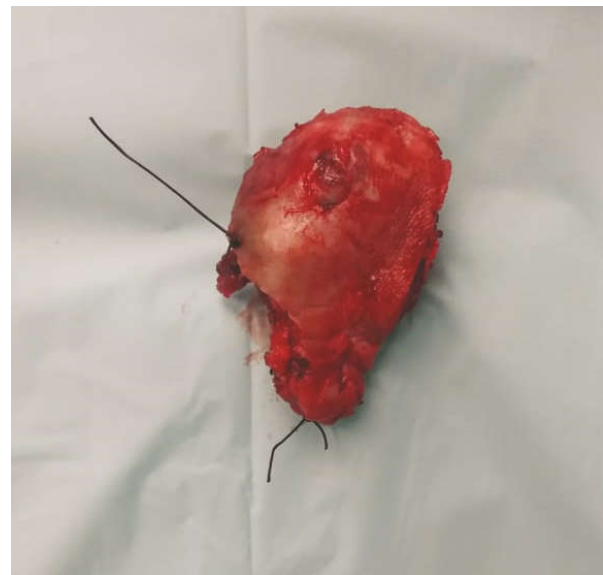


Fig. 8: Nodular Excised Tumor.

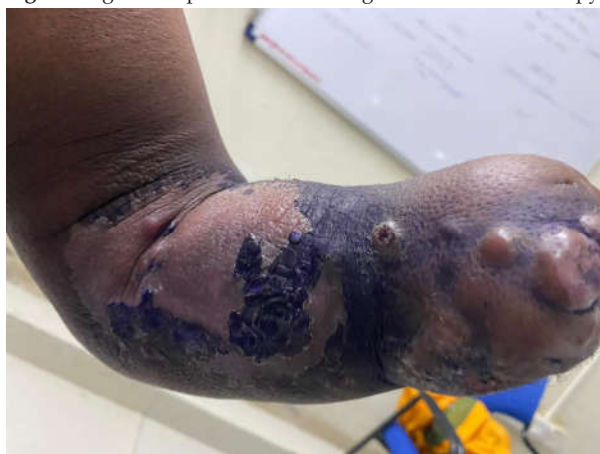

Fig. 6: Image of Amputated arm After Completion of Radiotherapy.

Discussion

Extra ocular sebaceous carcinoma involving the extremity is very uncommon, aggressive malignant tumor arising from sebaceous glands. Mean age of occurrence is 63 years involving both sexes in equal proportion. The disease exhibits a variety of histologic growth patterns and diverse clinical presentation that diagnosis is often delayed for months to years.⁷ The most frequent clinical presentation is a painless subcutaneous firm nodules (79%) located in dermis or hypodermics of variable size (0.5to 5cm). Our patient reported to us with a similar presentation of painless swelling. Sebaceous carcinoma of extremity can also present as pedunculated lesions, irregular mass or diffuse thickening of skin. This protean appearance frequently masquerades as other benign tumours or

inflammatory conditions, thereby leading to delay in diagnosis, inappropriate treatment, increased morbidity and mortality. The lesions usually present as pink to red yellow nodular growth in skin and may clinically resemble pyogenic granuloma, haemangioma or squamous cell carcinoma. The draining lymph nodes may be involved in few cases only like in our case.

Regardless of the location, this malignancy is highly aggressive with a potential for regional and distant metastasis. Our patient also presented with recurrence of multiple cutaneous nodules at post op site along with ipsilateral axillary lymph node metastasis although there was neither distant metastasis nor any sign of internal visceral malignancy.

Sebaceous carcinoma histologically may be classified as well, moderately or poorly differentiated. The morphological hallmark of sebaceous differentiation is the detection of sebaceous cells and demonstration of fat in vacuolated tumour cells. Other differential diagnosis includes basal cell carcinoma with sebaceous differentiation for poorly differentiated sebaceous cell carcinoma. Basal cell carcinoma exhibit peripheral palisading and clefting from the adjacent stroma.

Sebaceous carcinoma express immunohistochemical markers such as cytokeratin, epithelial membrane antigen(EMA), Cam 5.2 and anti breast carcinoma associated antigen-225 antibody.

The common associations of sebaceous carcinoma are Muir-Torre syndrome; an autosomal dominant condition comprising of sebaceous neoplasm with one or more low grade visceral malignancies and Nevus sebaceous of Jadassohn⁸ in the absence of other participating factors such as radiotherapy and AIDS.⁹

Distant metastasis and recurrence rates are more common in the ocular type of sebaceous carcinoma [3,10] when compared to extraocular sebaceous carcinoma.

Treatment of sebaceous carcinoma requires wide local excision with removal of involved regional lymph nodes. But Nelson showed that the chances of local recurrence are very high as seen in our patient also.¹¹ Bailet reported a review of 92 patients with extraocular sebaceous carcinoma and found a recurrence rate of 28% and metastasis in 21% of cases after local excision.¹² Bhandari V¹³ also reported a case report of sebaceous carcinoma focussing on its aggressive nature where limited response was seen after chemotherapy. Radiotherapy has been considered as an adjunctive or palliative treatment but is generally not recommended as a primary

treatment. The role of chemotherapy has not been defined due to scarcity of these lesion

Conclusion

Extraocular sebaceous carcinoma is a rare malignancy; the arm localisation is even rarer. This is an uncommon but aggressive malignant tumour with higher incidence of recurrence and distant metastasis. The diagnosis is essentially histological; the treatment of choice is radical surgery. More diagnosed is early and more the surgery is extensive more the prognosis is better. Regular follow up is necessary to detect local recurrence, locoregional or metastatic spread.

Reference

1. <https://www.ncbi.nlm.nih.gov/pmc/articles/PMC3481818/>
2. Ghosh SK, Bandyopadhyay D, Gupta S, Chatterjee G, Ghosh A. Rapidly Growing Extraocular Sebaceous Carcinoma Occurring During Pregnancy: A Case Report. *Dermatol Online J.* 2008;14:8.
3. Nelson BR, Hamlet KR, Gillard M, Railan D, Johnson TM. Sebaceous carcinoma. *J Am Acad Dermatol.* 1995;33:1-15.
4. Wick MR, Goellner JR, Wolfe JT, 3rd, Su WP. Adnexal carcinomas of the skin. II. Extraocular sebaceous carcinomas. *Cancer.* 1985;56:1163-72.
5. Lazar AJ, Lyle S, Calonje E. Sebaceous neoplasia and Torre-Muir syndrome. *Curr Diagn Pathol.* 2007;13:301-19.
6. Graham RM, Mckee PH, Megibbon D. Sebaceous carcinoma. *Clinical Exp Dermatol.* 1984;9:466-471
7. Sudip Ghosh, Debabrata Bandyopadhyay, Sandip Gupta, Rapidly growing extra sebaceous carcinoma occurring during pregnancy: A case report. *Dermatology online journal.* 14(8): 8
8. Schwartz RA, Torre DP. The Muir-Torre syndrome: A 25-year retrospect. *J Am Acad Dermatol.* 1995;33:90-104.
9. Pettey A, Walsh J. Muir - Torre Syndrome : a case report and review of the literature. *Cutis.* 2005; 75 : 149-155
10. Muqit MM, Roberts F, Lee WR, Kemp E. Improved survival rates in Sebaceous Carcinoma of the eyelid. *Eye.* 2004;18:49-53.
11. Nelson BR, Hamlet KR, Gillard M, Johnson TM. Sebaceous carcinoma. *J Am Acad Dermatol.* 1995; 33(1): 1-15
12. Bailet JW, Zimmerman MC, Arnstein DP, Wollman JS, Mickel RA. Sebaceous carcinoma

of the head and neck. Case report and literature review. Arch Otolaryngeal Head Neck Surg. 1992; 118(11) : 1254 - 1249

13. 1.Bhandari V. Sebaceous carcinoma of the extremity : a rare case report. Ijcer. 2013;Vol1(1095): 25-27.

