

Case Report on Xanthogranulomatous Oophoritis

Alka Patankar¹, Bhakti Deshpande², Shweta Walke³

How to cite this article:

Alka Patankar, Bhakti Deshpande, Shweta Walke. Case Report on Xanthogranulomatous Oophoritis. Indian J Obstet Gynecol. 2020;8(2):102-105.

¹Associate professor, ²Assistant professor, ³Senior Residency, Department of Obstetrics and Gynecology, Indira Gandhi Government Medical College, Nagpur, Maharashtra 440018, India.

Corresponding Author: Shweta Walke, Senior Resident, Department of Obstetrics and Gynecology, Indira Gandhi Government Medical College, Nagpur, Maharashtra 440018, India.

E-mail: swkg999@gmail.com

Received on 26.04.2020; Accepted on 17.06.2020

Abstract

This is a case report of 30 year old lady married since 10 years, with two living issues, previous two cesarean sections and tubectomised 5 years back, with complaints of pain in lower abdomen, on and off since 3 months. Also presented with lump in abdomen, which was slowly increasing since 3 months. Xanthogranulomatous oophoritis is chronic inflammatory condition, characterized by presence of large number of lipid laden histiocytes admixed with other inflammatory cells leading to destruction of affected tissue. It is commonly seen in kidney and gallbladder, stomach, anorectal areas, bones, urinary bladder, testis, epididymis, ovary, vagina and endometrium. Xanthogranulomatous inflammation of female genital tract is rare.

Keywords: Xanthogranulomatous oophoritis; Female genital tract; Ovary.

Introduction

Xanthogranulomatous oophoritis is chronic inflammatory condition, characterized by presence of large number of lipid laden histiocytes admixed with other inflammatory cells leading to destruction of affected tissue. It is commonly seen in kidney and gallbladder. Other areas in which Xanthogranulomatous inflammation has been reported are stomach, anorectal areas, bones, urinary bladder, testis, epididymis ovary,

vagina and endometrium.¹ Xanthogranulomatous inflammation of female genital tract is rare. Xanthogranulomatous oophoritis usually occurs in third decade of life in age group 30-35 years, with lower abdominal or suprapubic pain, fever, per vaginal discharge or spotting, Adnexal tenderness and pelvic mass are the findings commonly seen on clinical examination. The inflammatory process is characterized by massive infiltration of tissue by lipid laden histiocytes admixed with lymphocytes, plasma cells and polymorphonuclear leucocyte. The involved ovary is replaced by solid and yellow circumscribed lobulated mass mimicking malignancy. Only 29 cases of Xanthogranulomatous oophoritis and salpingitis are documented in literature. Pelvic inflammatory disease is main etiological factor.

Case Report

Here we report a case of 30 year old lady married since 10 years, with two living issues, previous two cesarean sections and tubectomized 5 years back. Patient presented with complaints of pain in lower abdomen, which was on and off since 3 months. She also presented with lump in abdomen, which was slowly increasing since 3 months. Her previous menstrual cycles were regular. Her last menstrual period was on 2/12/18. On per abdominal

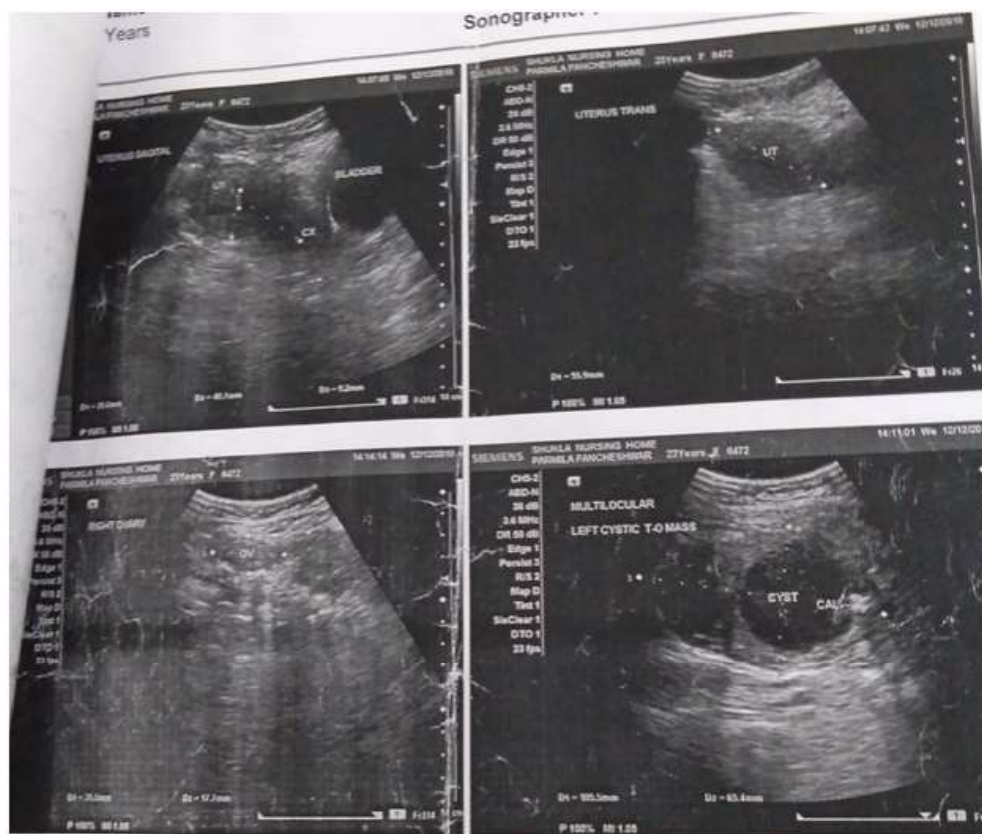


Image 2

examination there was a mass around 20 weeks size, with irregular borders, arising from pelvis, mass was immobile and hard in consistency, more on left side reaching upto anterior superior iliac spine.

On speculum examination, cervix and vagina were healthy. On per vaginal examination 20 weeks size mass was felt, which was fixed, obliterating left fornix and was hard in consistency. Uterine size could not be made out, whereas right fornix was free. Clinical diagnosis of ovarian neoplasm, possibly malignant or tuboovarian abscess was entertained and patient was investigated further.

Ultrasound imaging revealed enlarged Bilateral ovaries showing multiple cystic masses within with thin and thick septations and organized debris with areas of calcifications in cystic mass of size 1x0.8 cm, adherent to wall of lesions. Left ovary was bulky and adhered to omentum. Surrounding perilesional and right iliac fossa collection was seen. Left ovary measured around 9.8x6.7x8.3 cm with a volume of around 290cc and Right ovary measured around 5.3x3.7x5.9 cm with a volume of around 60.65cc. There was no abdominal lymphadenopathy. Uterine dimensions were 9.9x5.3x4.5 cm, Bulky with periuterine collection,

with spiky adhesions with omentum. Endometrial thickness was around 1.1 cm. Her hemoglobin was 8.6gm%, with total leucocytes count 10.54cu/mm. Her CA125 was 13.19U/ml. Contrast enhanced CT abdomen and pelvis was not done due to cost constraints but other tumor markers were done (Beta HCG, Serum LDH, Serum AFP and CEA) and were found to be negative. Patient underwent exploratory laparotomy. Intraoperative findings: Large thick walled tuboovarian mass on left side of approximately 7x6x4 cm containing pus, adhered to anterior abdominal wall, posteriorly to bowel and medially to uterus. Grossly cyst was multilocular filled with dirty foul smelling thick pus yellowish fluid. Right ovary measured around 4x3x2cm with hemorrhagic cyst. Uterus was bulky and adhered to anterior abdominal wall and the mass on left side. Bowel loop adhesions were present over right lateral abdominal wall. Segmental thickening of bowel was present. Left sided ovary with Fallopian tube was removed along with right sided hemorrhagic cyst and sent for histopathological examination. Patient received one unit of blood transfusion pre and postoperatively. Pus culture report was negative for AFB or other organism.

The histopathological report of bilateral tuboovarian masses of left ovarian mass and Right ovarian cyst wall was suggestive of:

On gross appearance left ovary was containing single mass of size 8 X 6 X 4 cm, externally it was greyish white glistening and on culture sensitivity multiple cysts were present which were filled with pus and surrounding necrotic area. Largest cyst was of size 2 x 2 cm and right ovarian cyst wall was containing multiple tissue of around size 5x5x 2 cm, externally was blackish, brownish and congested.

On microscopy - multiple section from left ovary showed sheets of foamy histiocytes, plasma cells, lymphocytes & foreign body giant cells in the ovarian stroma, histological features were suggestive of xanthogranulomatous oophoritis and sections from right ovarian cyst wall shows histological features of corpus luteal haemorrhagic cyst.

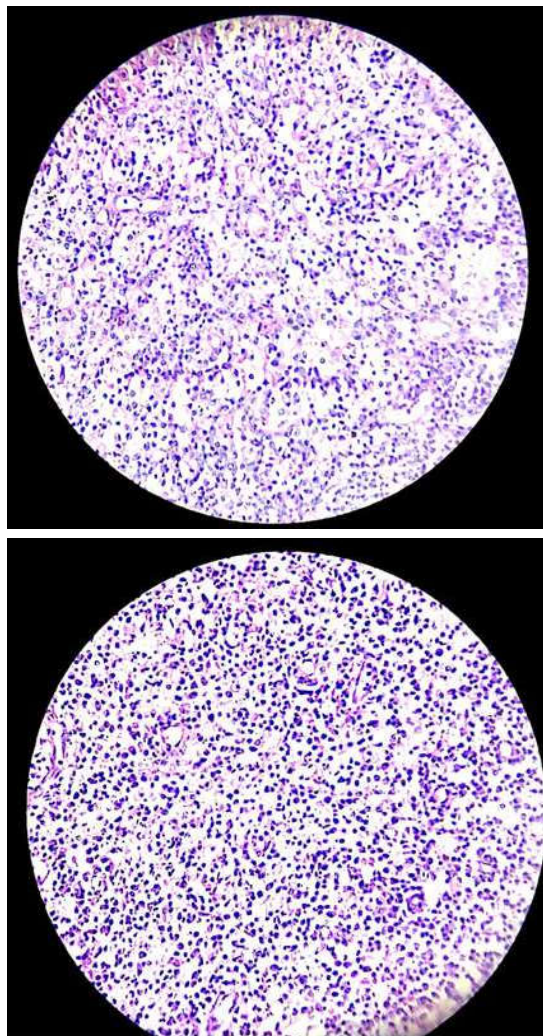


Image 2 and 3 are sections of ovary showing sheets of foamy histiocytes, plasma cells, lymphocytes and foreign body giant cells in ovarian stroma.

Discussion

Xanthogranulomatous inflammation of female genital tract most commonly affects endometrium and rarely ovary. This is a disease of reproductive age with an average of 35.2 year. The youngest case document report of xanthogranulomatous inflammation of ovary is of 2 year old girl.² The most common etiology is infection such as E.coli, Bacteriodes fragillis, proteus vulgaris which are confirmed by tissue culture of affected tissue. Clinical manifestation & imaging findings often lead to diagnosis of either a tubo-ovarian mass or a malignancy.³

Cases of Xanthogranulomatous oophoritis associated with premature ovarian failure, bowel obstruction, diverticulitis and occurrence of the typhoid, uterine artery embolization have been reported.⁴ It is often misdiagnosed as ovarian malignancy due to unusual appearance on imaging as well as in situ. Out of the very few female genital tract cases reported in literature, 7 cases involved unilateral ovary, 5 cases involved unilateral fallopian tubes simultaneously. The mass may grow large in size upto 3-7 cm in maximum directions and inflammation may extend to the neighbouring organs, pelvic structures & peritoneum. On gross appearance the mass has clear borders without intact capsule, with areas of hemorrhagic necrosis. On histology the normal ovarian structure is replaced by chronic inflammatory cell infiltrate mixed with focal or mixed with sheets of foam cells, fibroplasia, avascular proliferation. Presence of foam cells makes malakoplakia an important differential diagnosis as suggested by walther, et al. which is then distinguished from Xanthogranulomatous oophoritis by presence of basophilic Michaelis - gutmann bodies which are absent in latter.⁵

Conclusion

Xanthogranulomatous oophoritis is a rare entity. It should be kept in mind in differential diagnosis of tuboovarian masses. This helps to prevent misdiagnosis as neoplasm and overzealous treatment & for correct diagnosis & management.

References

1. Bindu SM, Mahajan MS. Xanthogranulomatous oophoritis: A case report with review of literature. *Int J Health Allied Sci* 2014;(3)187-9.

2. Tanwar H, Joshi A, Wagaskar V, et al. Xanthogranulomatous salpingo oophoritis: The youngest documented case report. *Case Rep Obstet Gynecol* 2015;2015:237250.
3. Sharma S, Phadnis P, Kudva R, et al. Xanthogranulomatous salpingo-Oophoritis presenting as a tubo-Ovarian mass: A case report with brief review of literature. *Int J Health Sci Res* 2016;6(3);316-9.
4. Son J, Raetskaya-Sointseva O, Tirman PA, et al. Xanthogranulomatous oophoritis presenting as an adnexal mass and bowel obstruction: A case report. *J Reprod Med* 2015;60:273-6.
5. Kishore SH, Rajshri OP, Dravid NV. Xanthogranulomatous oophoritis mimicking as an ovarian neoplasm. *J Case Reports* 2014;4:100-3.

