

Variant Formations of Median Nerve

Sudke Geetanjali B*, Kulkarni P.R.**, Dope Santoshkumar A.***

Abstract

Variations in formation of median nerve by more than two roots are relatively uncommon as compared to other variations. During routine dissection for undergraduates, we observed two variations in the formation of median nerve. In one case unilateral variation was observed in 40 year old male cadaver in left axillary region. Here the formation of median nerve was by four roots. Three roots coming from lateral cord joined single root from medial cord leading to median nerve formation. In other case formation was by three roots, two roots from lateral cord and one from medial cord. This variation was present bilaterally. However, in both the cadavers the distribution of the anomalous median nerve was normal in arm, forearm and palm. Presence of such additional roots must be kept in mind during surgery to avoid their injury. It can also explain some unusual clinical symptoms.

Key words: Median nerve; Variations; Lateral cord.

Introduction

Variations in arrangement and branching pattern of brachial plexus are common and have been thoroughly studied and reviewed earlier.^[1-3] These variations are more observed at the level of its formation of trunks, divisions, cords and its terminal branches. The median nerve is one of the branches of the brachial plexus which shows frequent variation in its formation. Usually, Median nerve is formed in axilla by two roots by contributions from the lateral cord originating from ventral roots of C5, C6 & C7 and medial cord from ventral roots of C8 & T1. Lateral root arises from lateral cord of brachial plexus, medial root from medial cord. Medial root crosses in front of third part axillary artery to unite with lateral root in a Y shaped manner either in front of

or on the lateral side of the artery to form the median nerve. It lies lateral to third part axillary artery and enters arm at the lower border of Teres major^[4].

The knowledge of the anatomical variations of the peripheral nerves in the upper limbs are important as these abnormal nerves could be injured during surgical procedures. It can also explain some of the unusual clinical symptoms.

Case report

We encountered two relatively uncommon variations in the formation of median nerve by more than two roots while dissecting for undergraduates in the Department of Anatomy, Government Medical College, Latur.

Case 1

During routine dissection, unilateral variation in formation of median nerve was observed in a 40 year old male cadaver. Variation was observed in left axillary region. Median nerve is formed by one medial and

Author's Affiliation: *+***Assistant Professor, Department of Anatomy, Government Medical College, Latur (Maharashtra). **Professor & Head, Department of Anatomy, Government Medical College, Latur, Maharashtra.

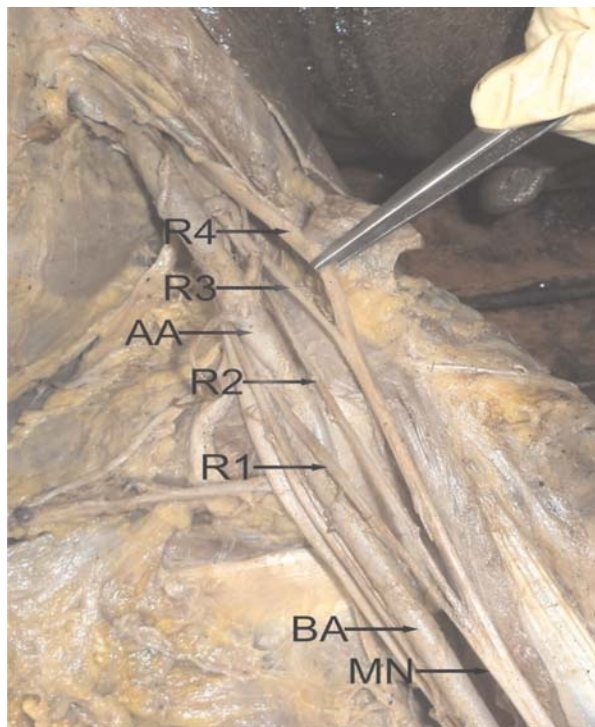
Reprint's request: Dr. Sudke G.B., C/o B. T. Sudke, Sakshi, Bhagya nagar, Old Ausa Road, Latur- 413512, Maharashtra.

Email : drsudkegeeta@gmail.com

(Received on 05.11.2012, accepted on 27.11.2012)

three lateral roots coming from medial and lateral cords of brachial plexus respectively. Medial root crossed in front of axillary artery to join the three lateral roots forming median nerve lateral to brachial artery. The two lateralmost roots from lateral cord joined with each other, the trunk thus formed joined with the formation of median nerve. Median nerve thus formed by single root from medial cord and three roots from lateral cord continued lateral to brachial artery. The other branches from lateral cord were musculocutaneous and lateral pectoral nerve. Branches from medial cord were ulnar, medial pectoral, medial cutaneous nerve of arm and medial cutaneous nerve of forearm. Arterial pattern of upper limb was normal. Right axillary region was meticulously dissected but formation of median nerve on right side was as routinely described. (Figure 1)

Figure 1: Shows four roots forming median nerve

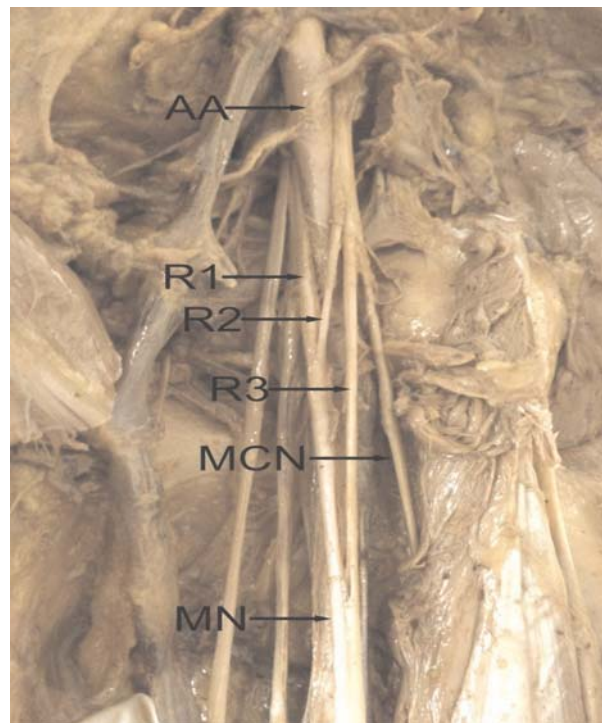


R1: Medial root of median nerve, R2: Lateral root of median nerve, R3,R4: Additional roots from lateral cord, AA: Axillary artery, BA: Brachial artery, MN: Median nerve

Case 2

A bilateral variation was observed in a 50 year old male cadaver. Median nerve is formed by lateral and medial roots coming from lateral and medial cords of brachial plexus respectively in front of third part of axillary artery. After its formation, median nerve trunk continued anterior to the brachial artery. At the level of the insertion of coracobrachialis muscle, the median nerve trunk received a communicating branch from the lateral cord of brachial plexus, after the latter gave off the musculocutaneous nerve. Finally, the median nerve trunk consisting of lateral root, medial root and communicating branch from lateral cord continued lateral to the brachial artery. The distribution of median and musculocutaneous nerves was normal in arm. The arterial pattern in arm was also normal. The pattern of supply of median nerve in forearm and palm was also found to be normal. (Figure 2)

Figure 2: Shows three roots forming median nerve



R1: Medial root of median nerve, R2: Lateral root of median nerve, R3: Additional root from lateral cord, AA: Axillary artery, MCN: Musculocutaneous nerve, MN: Median nerve

Discussion

To know about the variations of brachial plexus is helpful to anatomists, radiologists, anesthesiologists and surgeons to prevent any postoperative complications during surgery.

There is mounting evidence that connections between the musculocutaneous nerve and the median nerve are very frequent.^[1,5] Unilateral median nerve formation of four roots, where three of them were from the lateral fascicle and two of them were communicating with the musculocutaneous nerve was also observed^[5]. There may be formation of median nerve posterior to axillary artery^[6,7] or two roots may traverse separately. The median nerve may directly coming from the lateral cord^[8].

In the present study we observed multiple roots forming median nerve. Some of the research workers has shown the variations in the formation of median nerve. In a study involving 196 upper limbs, three roots forming median nerve was found in 22.4% cases and formation by 4 roots was found in 3.57% cases^[9,10]. The medial root of the median nerve was found to receive a supplementary branch from the medial aspect of the terminal portion of the lateral cord^[11].

The variations encountered in the present study can be explained embryologically. The upper limb buds are visible by day 26 or 27 which elongate by proliferation of mesenchyme. It lies opposite to the lower five cervical and upper two thoracic segments. As soon as buds form, the ventral primary rami of the spinal nerves penetrate into the mesenchyme of limb bud and establish intimate contact with differentiating mesodermal condensations^[12]. The early contact between nerve and muscle cell is a prerequisite for their complete functional differentiation^[13]. Thus the limb muscles develop from the mesenchyme of local origin, while the axons of the spinal nerves grow distally to reach the muscles and/ or the skin^[12]. The alterations in signaling between mesenchymal cells and neuronal growth cones can lead to variations which once formed would persist postnatally.

Result of an exploratory intervention of the arm for peripheral nerve repair with these variations could be successful only if surgeon is aware of such variations. Signs of median nerve lesion can be observed in a patient with intact median nerve if such a variation is present and additional roots are injured.

References

1. Kerr AT. The brachial plexus of nerve in man, the variations in its formation and branches. *Am J Anat* 1918; 23: 285-395.
2. Uzun A, Bilgic S. Some variations in the formation of the brachial plexus in infants. *Turk J Med Sci* 1999; 29: 573-7.
3. Venieratos, D. and Anagnostopoulou, S. Classification of communications between the musculocutaneous and median nerves. *Clinical Anatomy* 1998; 11: 327-31.
4. Williams PL, Bannister LH, Berry MM. *Gray's Anatomy*, 38th Ed. Edinburgh; Churchill Livingstone, 1998; 1266-72.
5. S. Uzun, Seelig L. A variation in the formation of the median nerve: communicating branch between the musculocutaneous and median nerves in man. *Folia Morphol* 2001; 60(2): 99-101.
6. Pandey S. K. Anatomical variations of the cords of brachial plexus and the median nerve. *Clin Anat* 2007; 20(2): 150-6.
7. Chitra R. A rare variant formation of median nerve: a case report. *Internet Journal of Neurology* 2007; 8(2).
8. S Bhanu P. Formation of median nerve without medial root of medial cord and associated variations of brachial plexus. *International Journal of Anatomical Variations* 2010; 3: 27-9.
9. Budhiraja V. Anatomical variations of median nerve formation: embryological and clinical correlation. *J Morphol Sci* 2011; 28(4): 283-6.
10. Satyanarayana N. Rare variations in the formation of median nerve - embryological basis and clinical significance. *Nepal Med Coll J* 2009; 11(4): 287-90.
11. Pais, D, Casal D. A variation in the origin of the median nerve associated with an unusual origin of the deep brachial artery. *J Morphol Sci* 2010; 27(1): 35- 8.
12. Moore KL, Persaud TVN. *The Developing Human Clinically Oriented Embryology*, 8th Ed. Philadelphia; Saunders, 2008; 365- 417.
13. Saddler TW. *Langman's Medical Embryology*. In: Muscular system, 10th ed. Philadelphia; Lippincott Williams and Wilkins, 2006; 146-7.