

Variations in the Shape of Human Hyoid Bone in Western Maharashtra

Jadhav Ashwini S, MS (Anatomy)*, Kulkarni P.R, MS (Anatomy)**

Abstract

A study of 91 human hyoid bones consisting of 51 male and 40 female bones obtained from medicolegal postmortems and dissected cadavers from the department of Anatomy was conducted. The hyoid bones were classified according to its shape into 5 different types based on the studies of Papadopoulos et al [1] and Harjeet and Jit^[2]. The V-type was dominant in males (29.4%) and U-type in females (30%). An attempt was also made to classify the hyoid bone according to its symmetry and isometry.

Key words: Hyoid bone; Sexual dimorphism; Western Maharashtra.

Introduction

Hyoid bone is a symmetric, U-shaped bone suspended from the tips of the styloid process by the stylohyoid ligament. The name hyoid is derived from the greek word 'hyoides' meaning shaped like the letter 'upsilon' or letter 'U'^[1]. The Hyoid bone is present in many mammals; it allows a wider range of tongue, pharyngeal and laryngeal movements by bracing these structures alongside each other in order to produce variation. Due to its position, the Hyoid bone is not susceptible to easy fracture. In a suspected case of murder, a fractured hyoid strongly indicates throttling or strangulation^[3]. In the year 1979, Koebeke and Saternus^[4] first classified the hyoid bone into 4 types-Parabolic (40.9%), Hyperbolic (35%), Horseshoe (13.1%) and Asymmetric (11%). This classification was modified in the year 1989 by Papadopoulos et al^[1] and the hyoid bone was classified into 5 different

types – Type U, Type V (triangular), Type H (horseshoe), Type B (boat shape) and Type D (deviating). In their study it was seen that type D was the leading type in men covering almost half of the male population. On the contrary Type H and B occurred with equal frequency in females covering almost two-third of the female population.

Harjeet and Jit (1996)^[2] have classified the shapes of the hyoid bone based on the study of Papadopoulos et al^[1] in adults, children, neonates and fetuses. According to their study, in adult males, V-type and in adult females, U-type hyoid bones were the leading types. Significant sexual difference was found in U and V type bones.

O'Halloran, Miller and Walker (1998)^[5] studied age and sex related variation in hyoid bone morphology by taking a series of 30 measurements on digitized radiograph of 315 hyoid bones from people of known age and sex. They concluded that most of the bones were highly symmetrical. Pollanen and Ubelaker (1997)^[6] studied forensic significance of the polymorphism of hyoid bone shape. The reason why some hyoids fracture in strangulation and others do not is related to anatomic features of hyoid bone. They studied dimensions and shape of 100 hyoid bones and compared the metric parameters of fractured

Author's Affiliation: *Associate Professor, **Professor and Head, Department of Anatomy, Dr. V.M. Govt. Medical College, Solapur, Maharashtra.

Reprint's request: Dr. Ashwini Jadhav, 145, Vishal Nagar, Opp. V.M. Mehta High School, Jule Solapur, Solapur, Maharashtra.

E-mail: ashwinihar2011@gmail.com

(Received on 02.05.2012, accepted on 08.06.2012)

hyoid bones from ten cases (8 females and 2 males) of strangulation. The length and breadth of female hyoid bones were smaller than that of the male bones. Based on qualitative assessment they classified hyoid bones into hyperbolic (55%) and Parabolic (45%) types.

The present study was done to determine the incidence of various shapes in adult male and female hyoid bone. The hyoid bones were also classified according to their symmetry and isometry.

Material and methods

Ninety-one human hyoid bones from different religion and caste were collected from medicolegal postmortems as well as dissected cadavers from the department of Anatomy. The study included 51 male and 40 female bones.

Each hyoid bone was collected by dissecting neck. Midline incision was taken on neck and the incision was extended from symphysis menti to suprasternal notch. Strap muscles of neck were dissected and were reflected to both sides and the front part of larynx was exposed. Hyoid bone was identified which is present above the thyroid cartilage. It was separated from base of tongue and then it was separated from larynx. The bone was obtained with partial attachment of muscle fibres and ligaments. It was cleaned and kept in a labeled container indicating the serial number and sex of the bone to avoid mixing of the specimens. The bone was kept for maceration for 2 weeks and then dried for 1 week. Each bone was photographed and was classified on the basis of its shape into following 5 types:

1) U-Type: It is half circle anteriorly and the greater cornua are almost straight. (Photograph-1a)

2) V-type: It is half circle anteriorly and resembles the letter V. (photograph-1b)

3) Horse shoe-type: It is half circle anteriorly and the greater cornua face each other. (Photograph-1c)

4) Boat-type: It resembles a boat and the two greater cornua deviate from each other. (Photograph-2a)

5) Deviated-type: One greater cornua deviates more than the other making the cornua asymmetrical. (Photograph-2b).

The percentage of asymmetric and anisometric bones was also calculated.

A bone is symmetric if the middle of all its transverse diameters fall on the sagittal axis (photograph 3) otherwise it is an asymmetric hyoid bone (Photograph 4).

A bone is isometric if the tips of both greater cornua fall on the same horizontal line (photograph 5) otherwise it is an anisometric bone and the tips of both greater cornua do not coincide on the same axis (Photograph 6).

The data thus obtained was tabulated separately for male and female and was analyzed statistically by univariate method.

Observation

After drying the bones were photographed and classified into five different types based on the classification of Papadopoulos et al^[1] and Harjeet and Jit^[2]. The incidence of various shapes of hyoid bones in males and females is given in Table1. In males V-type is common (29.4%) followed by U-type (25.4%). In females U-type is common (30%) followed by V-type (17.5%).

Table 2 shows the incidence of asymmetric and anisometric hyoid bones. In the present study 19 male (37.2%) and 10 female (25%) hyoid bones were classified as asymmetric. Similarly 15 male hyoid bones (29.4%) and 8 female hyoid bones (20%) were classified as anisometric.

Discussion

The hyoid bones were first classified according to their shape by Koebke and Saternus^[4] into 4 types: Parabolic (40.9%), Hyperbolic (35%), Horseshoe type (13%), and Asymmetric (11%). They observed

that the Parabolic was commonest type in men (45.4%) followed by Hyperbolic (30.6%) and in females the Hyperbolic was the leading type (43.7%) followed by Parabolic (31.7%).

Papadopoulos et al^[1] examined the shapes of 38 male and 38 female bones and classified the hyoid bones into 5 types: U-type (18.4%), V-type (5.3%), B-type (26.3%), H-type (21.1%) and D-type (28.9%). Their U-type corresponds to Hyperbolic and their V and B types to Parabolic types of Koebke and Saturnus^[4]. In their study Deviated type was dominant in males (47.1%) and in females the Horseshoe and Boat types were present in equal proportion in about two-third of the female bones.

Harjeet and Jit^[2] classified the hyoid bones based on the study of Papadopoulos et al^[1] in North-West Indians. They found U-type in 24.7%, V-type in 28.3%, B-type in 5.7%, H-type in 10.7% and D-type in 20.1% of bones. They observed a significant sexual difference in U and V type of bones. In males V-type and in females U-type hyoid bones were the leading types which covered about one-third of the specimens.

Table 3 shows a comparison between the observation of the two previous workers and the present findings regarding the shape of hyoid bones. In our study V-type was dominant in males(29.4%) and U-type in females(30%). The incidence of V and U type

hyoid bones is much higher than that recorded by Papadopoulos et al^[1] but corresponds with the observations of Harjeet and Jit(1996)^[2]. The increase in the incidence of V-shaped hyoid bones in males could be related to a decrease in superior thyroid angle in males which occurs with increasing age. (Harjeet and Jit)^[7].

Table 2 shows the frequency of asymmetric hyoid bones according to their shape and sex distribution. A total of twenty-nine hyoid bones (19 male and 10 female) were classified as asymmetric. Papadopoulos et al^[1] observed asymmetry in 52.6% male and 42.1% female bones. Similarly in the study by Harjeet and Jit^[2] asymmetry was 56% in males and 51% in females. In the present study the asymmetry of hyoid bone was common in Deviated type in males (47.3%) and in U-type in females (40%).

Similarly twenty-three hyoid bones (15 male and 8 female) were classified as anisometric in the present study. The frequency of anisometry was also greater in males (29.4%) as compared to females (20%). In males the frequency of anisometry was highest in Deviated type (33.3%) while in females anisometry was seen in equal proportions in V-type, Boat-type and Deviated types (10%).

Source of funding and conflict of interest:
Nil

Table 1: Incidence of various shapes of hyoid bones in males and females

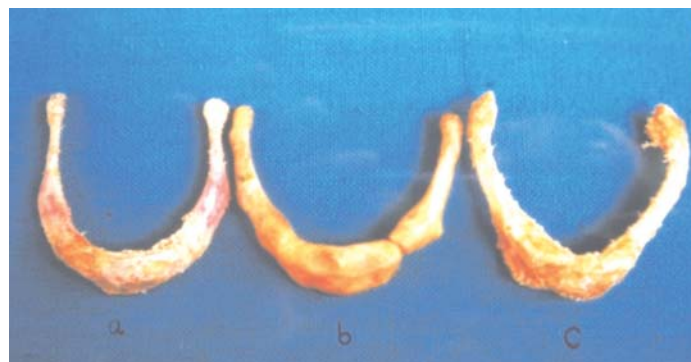Sr. No.	Shape	Male (n=51)	Female (n=40)	Total (n=91)
1	U -type	13 (25.4%)	12 (30%)	25 (27.4%)
2	V -type	15 (29.4%)	07 (17.5%)	22 (24.1%)
3	Boat -type	04 (7.8%)	07 (17.5%)	11 (12%)
4	Horse-shoe type	07 (13.7%)	08 (20%)	15 (16.4%)
5	Deviated-type	12 (23.5%)	06 (15%)	18 (19.7%)

Table 2: Incidence of asymmetric and anisometric hyoid bones in males and females

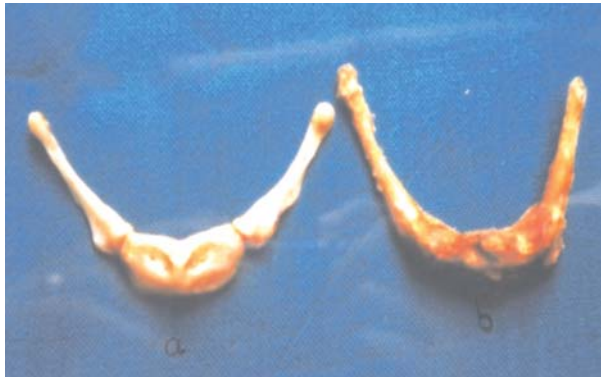
Sr. No.	Shape	Sex	Asymmetric bones	Anisometric bones
1	U type	M	2 (10.5%)	2 (13.3%)
		F	4 (40%)	1 (5%)
2	V-type	M	4 (21%)	4 (26.6%)
		F	3 (30%)	2 (10%)
3	Boat type	M	1 (5.2%)	1 (6.6%)
		F	Nil	2 (10%)
4	Horse-shoe type	M	3 (15.7%)	3 (20%)
		F	1 (10%)	1 (5%)
5	Deviated type	M	9 (47.31%)	5 (33.3%)
		F	2 (20%)	2 (10%)
6	Total	M	19 (37.2%)	15 (29.4%)
		F	10 (25%)	8 (20%)

Table 3: Comparison of present study with previous studies

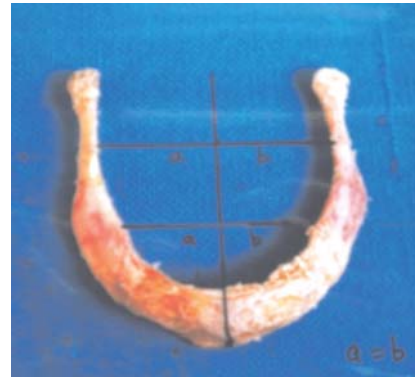
Shape	sex	Papadopoulos et al	Harjeet and Jit I	Present study
U-type	M	6(15.4%)	41(20.5%)	13(25.4%)
	F	8(21.1%)	33(33%)	12(30%)
V-type	M	2(5.3%)	67(33.5%)	15(29.4%)
	F	2(5.3%)	18(18%)	7(17.5%)
H-type	M	4(10.5%)	20(10%)	7(13.7%)
	F	12(31.6%)	12(12%)	8(20%)
B-type	M	8(21.1%)	28(14%)	4(7.8%)
	F	12(31.6%)	19(19%)	7(17.5%)
D-type	M	18(47.1%)	44(22%)	12(23.5%)
	F	4(10.5%)	18(18%)	6(15%)

Photograph 1: Shapes of hyoid bone a) U-type) V-type c) Horse shoe type

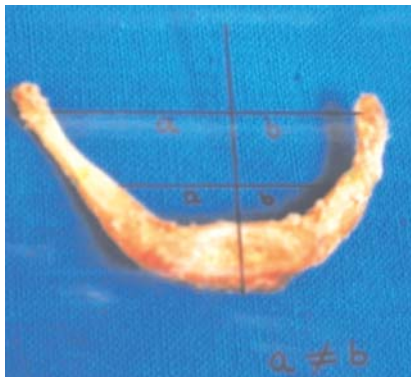Photograph 2: Shapes of hyoid bone a) Boat -type b) Deviated -type



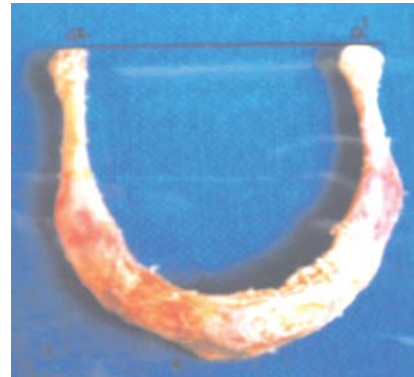Photograph 3: A symmetric hyoid bone



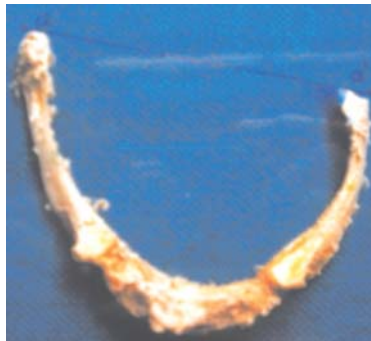Photograph 4: An asymmetric hyoid bone



Photograph 5: An isometric hyoid bone



Photograph 6: An anisometric hyoid bone



References

1. Papadopoulos N, Lykaki G, Anastopoulou et al. The shape and size of the human hyoid bone and a proposal for an alternative classification. *Journal Anatomy* 1989; 163: 249-260.
2. Harjeet, Jit I. Shape, size and sexual dimorphism of the hyoid bone in northwest Indians. *Journ Anat Soc India* 1996; 45(1): 4-22.
3. Hyoid bone-Wikipedia, the free encyclopedia. <http://en.wikipedia.org/wiki/Hyoid-bones>.
4. Koebke J, Saternus KS. Zur morphologie des adulten menschlichen. *Zungenbeins zeitschrift fur Rechtsmedizi* 1979; 84 :7-18.
5. O'Halloran, Miller and Walker. Age and sex related variation in hyoid bone morphology. *Journal Forensic Science* 1998; 43(6): 1138-1143.
6. Pollanen M.S. and Ubelaker D.H. Forensic significance of hyoid bone shape. *Journal Forensic Science* 1997; 42(5): 890-892
7. Harjeet, Jit I. Dimensions of thyroid cartilage in neonates, children and adults in northwest Indian subjects. *Journ Anat Soc India* 1992; 41: 81-92.