

## Case Report on a Cocktail Drug Abuser Developing Rhabdomyolysis

Domadala Sai Prateek<sup>1</sup>, Kamal Preet Palta<sup>2</sup>, Bibhash Roy<sup>3</sup>

### How to cite this article:

Domadala Sai Prateek, Kamal Preet Palta, Bibhash Roy/ Case Report on a Cocktail Drug Abuser Developing Rhabdomyolysis/  
Indian J Emerg Med 2023;9(4):225-227.

### Abstract

Rhabdomyolysis is a medical emergency characterized by the break down of skeletal muscle leading to the release of intracellular contents into the blood stream, which can lead to acute kidney injury and even death. Drug abuse is one of the potential causes of rhabdomyolysis. This case report describes a 18-year-old male with a history of drug abuse who presented to the emergency department with severe muscle pain, weakness, dark and reduced amount of urine. The patient was diagnosed with rhabdomyolysis, which was likely due to a combination of high doses Marijuana, Chlorpheniramine, Dextromethorphan (Corex Syrup), Dicyclomine, Tramadol, Acetaminophen and cigarette smoking over period of 4-5 years, landed up in rhabdomyolysis after joining gym. The patient was immediately started on aggressive intravenous fluid resuscitation, and his urine output and electrolyte levels were closely monitored. Patient required initiation of Hemodialysis over period of 15 days. Patient's muscle pain and weakness gradually improved over the next few days, and he was discharged with a diagnosis of AKI due to Rhabdomyolysis due to drug abuse. Prompt recognition and treatment of rhabdomyolysis are crucial to prevent serious complications, and addiction treatment should be pursued to prevent future episodes of rhabdomyolysis and other drug-related complications.

**Keywords:** Rhabdomyolysis; Muscle Pain; Substance Abuse; Marijuana; Corex Syrup; CPK; Fluid Resuscitation; Acute Kidney Injury; Hemodialysis; Myoglobinuria; Critical Care; Emergency Management.

**Author's Affiliation:** <sup>1</sup>Post Graduation 3rd Year Resident, <sup>2</sup>Senior Consultant Head of Department, <sup>3</sup>Consultant, Department of Emergency, Max Smart Superspecially Hospital, Saket 110017, Delhi, India.

**Corresponding Author:** Kamal Preet Palta, Senior Consultant Head of Department, Department of Emergency, Max Smart Superspecially Hospital, Saket 110017, Delhi, India.

**E-mail:** [kamal-palta@yahoo.com](mailto:kamal-palta@yahoo.com)

**Received on:** 01-06-2023

**Accepted on:** 15-07-2023

### INTRODUCTION

Rhabdomyolysis is a severe condition characterized by the breakdown of skeletal muscle fibers and the release of their contents into the bloodstream. It can occur due to various causes, including traumatic injuries, extreme physical exertion, drug toxicity, and electrolyte imbalances. We present here a case of an 18-year-old boy who developed rhabdomyolysis following a fall, coupled with a history of substance abuse and

intense weight training exercises.

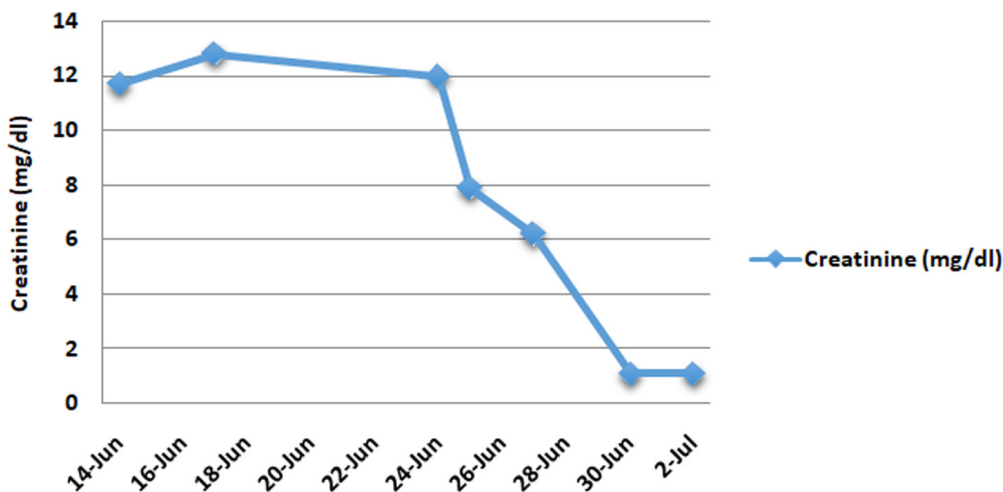
Rhabdomyolysis is a relatively uncommon but potentially life-threatening condition that requires prompt recognition and management. It can lead to significant complications, including acute kidney injury, electrolyte imbalances, and compartment syndrome. Timely intervention is crucial to prevent long-term damage and ensure a favorable outcome.

In this case report, we discuss the clinical presentation, diagnostic findings, treatment approach, and the subsequent recovery of an 18-year-old boy diagnosed with rhabdomyolysis. This report emphasizes the importance of a

comprehensive history, including substance abuse and physical activities, in the evaluation of patients presenting with rhabdomyolysis. It also highlights the critical role of aggressive fluid resuscitation and hemodialysis in the management of severe cases. Furthermore, it serves as a reminder of the potential consequences associated with substance abuse and the need for education and support in preventing such incidents.

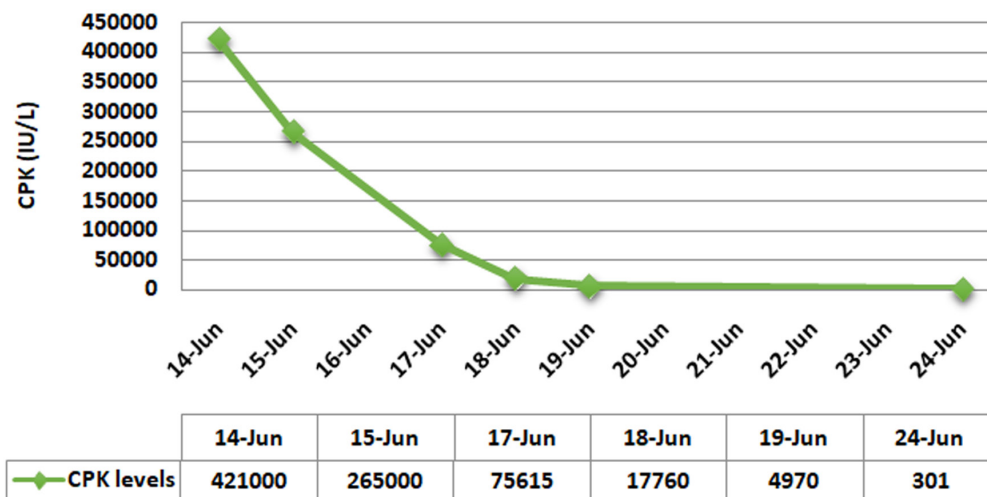
Understanding and sharing clinical experiences like this can contribute to increased awareness, improved diagnosis, and better management of rhabdomyolysis, thereby helping healthcare

### Creatinine levels



Graph 1: Creatinine Levels

### CPK levels



Graph 2: CRK Levels

professionals provide optimal care for patients facing similar challenges.

## CASE REPORT

An 18-year-old boy was admitted to the emergency department with complaints of severe muscle pain, weakness, and dark colored urine and decreased amount of urine for the past 2-3 days. He gave history of fall and loss of consciousness few days ago. He reported a history of consuming 2 bottles (250 ml each) of Corex syrup (Dexmeorphan, Chlorpheniramine), marijuana, paracetamol, and tramadol for the past few years, increased in last few days to get a "high."

On physical examination, the patient was extremely dehydrated, tachycardic and hypotensive, anuric on arrival, patient had not passed urine since last 2 days. Patient gave history of urine was dark colored 2 days ago.

Laboratory tests revealed elevated levels of Serum Creatinine - 11.7, CPK - 421000 IU/L.

The patient was diagnosed with rhabdomyolysis and was immediately started on aggressive fluid resuscitation with intravenous fluids to prevent acute kidney injury. Initially patient did not respond to fluid resuscitation. The patient was then started on hemodialysis to remove the circulating myoglobin and other toxins from the blood stream. The patient's urine output and renal function gradually improved, so did the creatinine and CPK levels over the period of 8 days. He was then discharged from the hospital after 8 days of hospitalization, with creatinine level of - 1.1mg/dl.

## DISCUSSION

Rhabdomyolysis is a rare but serious complication of drug abuse, and it can be caused by a variety of drugs, including Corex syrup, marijuana, paracetamol, and tramadol. Corex syrup is a cough syrup that contains codeine and promethazine, dextromethorphan, which are central nervous system (CNS) depressants that can cause muscle breakdown. Marijuana has been shown to cause muscle breakdown in animal studies, and paracetamol and tramadol can cause rhabdomyolysis through unknown mechanisms.

Hemodialysis is an effective treatment for rhabdomyolysis induced acute kidney injury, as it can remove the circulating myoglobin and other toxins from the bloodstream. However, it is important to note that prevention is the best

approach to managing rhabdomyolysis. Patients should be educated on the dangers of drug abuse and should be encouraged to seek help if they are struggling with addiction.

## CONCLUSION

Rhabdomyolysis is a serious medical condition that can be caused by a variety of factors, including drug toxicity. In this case report, we presented the case of an 18-year-old boy who developed rhabdomyolysis as a result of using Corex syrup, marijuana, paracetamol, and tramadol. The patient was successfully treated with hemodialysis and aggressive fluid resuscitation. This case highlights the importance of educating patients about the dangers of drug abuse and the need for prompt medical intervention if rhabdomyolysis is suspected.

## REFERENCES

1. Aiyu Zhao, Maybel Tan, AungMaung, Moro Salifu, Mary Mallappallil, "Rhabdomyolysis and Acute Kidney Injury Requiring Dialysis as a Result of Concomitant Use of Atypical Neuroleptics and Synthetic Cannabinoids", *Case Reports in Nephrology*, vol. 2015, Article ID 235982, 4 pages, 2015. <https://doi.org/10.1155/2015/235982>.
2. Yousef Khan F, Yousef H, Errayes M. Tramadol toxicity-induced rhabdomyolysis. *J Emerg Trauma Shock*. 2010 Oct;3(4):421-2. doi: 10.4103/0974-2700.70766. PMID: 21063575; PMCID: PMC2966585.
3. Khan FY. Rhabdomyolysis: a review of the literature. *Neth J Med*. 2009 Oct;67(9):272-83. PMID: 19841484.
4. Deaths due to abuse of dextromethorphan sold over-the-counter in Pakistan Humera Shafi, Muhammad Imran, Hafiz Faisal Usman, Muhammad Sarwar, Muhammad Ashraf Tahir a, Rabia Naveed a, Muhammad Zar Ashiq a, Ammar M. Tahir.
5. Chlorpheniramine poisoning as a potential cause of rhabdomyolysis Author links open overlay panel Qingqing Guo MD, MS a b 1, Hao Lin MD, MS , Jiandong Lin PhD.
6. Dextromethorphan Abuse Boyer, Edward W. MD, PhD, *Pediatric Emergency Care* 20(12): p858-863, December 2004. |DOI: 10.1097/01.pec.0000148039.14588.d0.
7. Rhabdomyolysis and drugs of abuse John R Richards MD a [https://doi.org/10.1016/S0736-4679\(00\)00180-3](https://doi.org/10.1016/S0736-4679(00)00180-3).