

## Caudal Displacement of Fractured Coronary Guidewire

Josephine Leshiini<sup>1</sup>, Siddharth Verma<sup>2</sup>, Kishalay Datta<sup>3</sup>

### How to cite this article:

Josephine Leshiini, Siddharth Verma, Kishalay Datta/Caudal Displacement of Fractured Coronary Guidewire/Indian J Emerg Med 2023;9(3):75-77.

### Abstract

Coronary angiography and catheterisation of the heart are most widely performed tests for the diagnosis and quantification of coronary artery diseases, identification of structural abnormalities of the heart (including valvular heart diseases), and hemodynamic status monitoring. There are very high risks and complications associated with these procedures that relate to the patient's conditions and also, the skill and operational abilities of the operator. In this case report we see a very interesting case of fractured coronary guide wire retention in the heart, its migration to distant artery and later its retrieval through surgical approach.

**Keywords:** Coronary Angiography complications; Fractured Coronary Angiography Guide Wire; Chest Pain; Migration of Coronary Guide Wire.

## INTRODUCTION

Coronary angiography is the gold standard and diagnostic test of choice in detecting coronary artery disease (in large) and structural heart diseases.<sup>1</sup> Like in any invasive procedure, there are specific procedure related and patient dependent complications associated with coronary angiography tests. These complications range from minor problems to life threatening situations that may cause irreversible damage, if urgent care is not provided.<sup>2</sup>

Patient dependent factors include age (old age), underlying disease (uncontrolled diabetes mellitus, renal insufficiency), underlying cardiac diseases (coronary artery disease, congestive heart failure, recent stroke or myocardial infarction bleeding diathesis).<sup>2-4</sup> Procedure related factors include poor skilled operator, improper technique, poor quality of tools, poor equipment.<sup>3,4</sup>

Various steerable guidewires are used to open occluded vessels and improve balloon and stent placement. However, these guide wires itself may be hazardous: they can perforate or dissect the vessel, but fracture or entrapment is uncommon. The management in these cases depends on the clinical situation of the patient, as well as the position, location and length of the retained product.

## CASE

A 65 year old male was brought to the emergency room from another secondary care hospital. The patient was on oxygen support with complaints

**Author's Affiliation:** <sup>1</sup>Post Graduate Trainee, <sup>2</sup>Consultant, <sup>3</sup>Director and HOD, Emergency Medicine, Max Super Speciality Hospital, Shalimar Bagh 110088, Delhi, India.

**Corresponding Author:** Josephine Leshiini, Post Graduate Trainee, Emergency Medicine, Max Super Speciality Hospital, Shalimar Bagh 110088, Delhi, India.

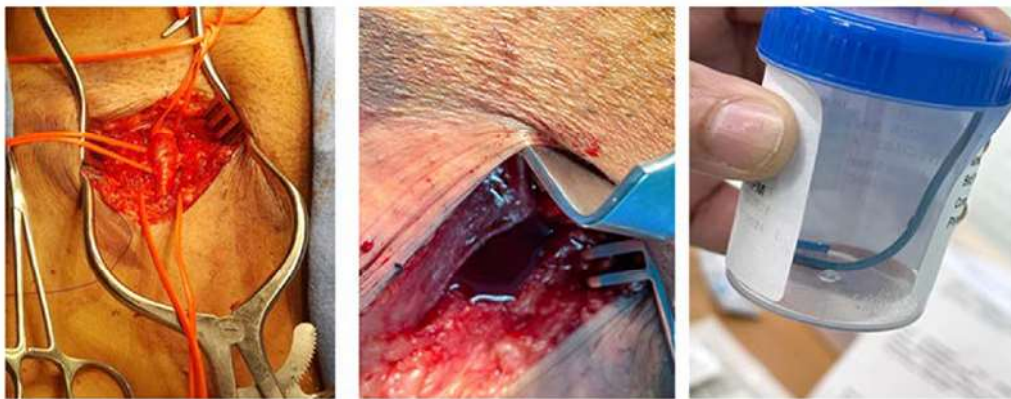
**E-mail:** josephineleshiinii@gmail.com

**Received on:** 25-02-2023 **Accepted on:** 27-03-2023

of retrosternal chest pain radiating down the abdomen up to the pubic region. Patient initial vital stats - pulse rate: 126/min, Blood pressure: 90/40 mmHg, oxygen saturation: 90% on 10 litres oxygen. Patient records stated that he was under going a coronary angiography test for his chest pain (diagnosed as unstable angina), when on retraction of guide sheath, it was observed the guidewire tip was broken. Without any delay, the patient was transferred to our setup for further management. Patient underwent contrast CT angiography which showed a filling defect near the femoral artery

artery.

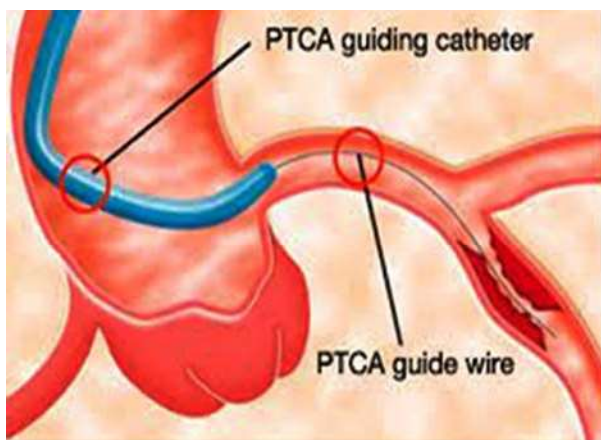
After initial resuscitation of the patient, he was shifted to the operating room. The vascular surgery team located the fractured entrapped fragment in the femoral artery. The patient underwent active surgical intervention for removal of the fractured fragment. The patient recovered well, no underlying vessel wall injury was noted due to the migration of the fractured fragment. Patient was discharged well and happy from our institute and recovered well during the further follow ups.



(Image Source: Hospital Department, Max Shalimar Bagh, New Delhi)

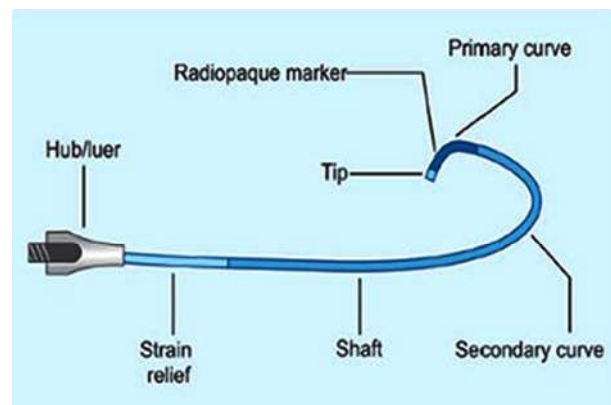
## DISCUSSION

The entrapment and fracture of coronary guide wire is a rare complication of coronary angiography and percutaneous coronary interventions. The rate of incidence of these complications is approximately around 0.1- 0.2%.<sup>5,6</sup> The most common mechanism in fracture or entrapment of coronary guide wire is over rotation of the distal tip of the guide wire leading to wire rupture.<sup>7</sup>



The possible mechanism understood so far is: during the usual practice of PTCA, the guide wire is advanced across the stenosis lesion to a minimal

distance to facilitate guidance of the balloon and stent easily across the stenosis. The rotational maneuver should never exceed 180 degrees which is sometimes done vigorously to advance the guide wire in the correct course.<sup>8</sup>



Extensive bending in the wire produces a high tensile load in the guide wire, especially when applied at the junction between the flexible distal 3 cm tip and the remainder of the guide wire.<sup>9</sup>

The management of patients with retained wire fragments within the coronary artery tree is complicated. Small fractured components can be left within a chronically occluded coronary artery without sequelae.<sup>10,11</sup> But these wire fragments are

highly thrombotic and thus, immediate surgical removal is indicated if percutaneous retrieval is difficult or unsuccessful.<sup>12</sup>

There are three options available for removal of fracture entrapped fragment: percutaneous retrieval, surgical extraction, or leaving the corpus alienum in-situ. The most acceptable method is the non-surgical procedure, by catch holding the fragment. This depends on the operator's comfort and experience. However, this approach also has risks for further damage of myocardial structure. Surgical approach is generally used when there is failed percutaneous retrieval.

In this case, the fracture fragment has traveled to a distant location by the pressure within the arterial wall, thus, making it possible for extraction. Though the fragment was easily accessible and removed, it traveled away from the coronaries to the femoral artery!

## CONCLUSION

Coronary guide wire fracture and entrapment during coronary angiography or percutaneous coronary interventions is a very rare complication. Extensive rotation of the guide wire in the coronary vessel is the major cause for fragment fracture. The fractured entrapped segment can either be removed by percutaneous procedure or surgical intervention. Leaving the fragment within the stenotic vessel can increase the chances of thrombosis. The fractured fragment can travel to distant locations by the arterial pressure. The fractured fragment can cause damage within the vessel wall. Because this is a rare complication and not much details are mentioned in literatures available online, we further need extensive research and documentation for future references.

## REFERENCES

1. Adams D. F, Fraser D. B, Abrams H. L. The complications of coronary arteriography. *Circulation*. 1973;48(3):609-618.
2. Babu S. C, Piccorelli G. O, Shah P. M, et al. Incidence and results of arterial complications among 16,350 patients undergoing cardiac catheterization. *J Vasc Surg*. 1989;10(2):113-116.
3. Braunwald E, Gorlin R. Cooperative study on cardiac catheterization. Total population studied, procedures employed, and incidence of complications. *Circulation*. 1968;37(5 Suppl):III8-16.
4. Gruberg L, Pinnow E, Flood R, et al. Incidence, management, and outcome of coronary artery perforation during percutaneous coronary intervention. *Am J Cardiol*. 2000;86(6):680-682. A688.
5. Hartzler GO, Rutherford BD, McConahay DR. Retained percutaneous transluminal coronary angioplasty equipment components and their management. *Am J Cardiol*. 1987;60(16):1260-4.
6. Steffenino G, Meier B, Finci L, et al. Acute complications of elective coronary angioplasty: a review of 500 consecutive procedures. *Br Heart J*. 1988;59(2):151-8.
7. Lotan C, Hasin Y, Stone D, Meyers S, Applebaum A, Gotsman MS. Guide wire entrapment during PTCA: a potentially dangerous complication. *Catheterization and cardiovascular diagnosis*. 1987;13(5):309-12.
8. Ghosh PK, Alber G, Schistek R, Unger F. Rupture of guide wire during percutaneous transluminal coronary angioplasty. Mechanics and management. *J Thoracic Cardiovasc Surgery*. 1989;97(3):467-9.
9. Vrolix M, Vanhaecke J, Piessens J, De Geest H. An unusual case of guide wire fracture during percutaneous transluminal coronary angioplasty. *Catheterizat Cardiovasc Diagnosis*. 1988;15(2):99-102.
10. Krone RJ. Successful percutaneous removal of retained broken coronary angioplasty guidewire. *Catheterizat Cardiovasc Diagnosis*. 1986;12(6):409-10.
11. Savas V, Schreiber T, O'Neill W. Percutaneous extraction of fractured guidewire from distal right coronary artery. *Catheterizat Cardiovasc Diagnosis*. 1991;22(2):124-6.
12. Keltai M, Bartek I, Biro V. Guidewire snap causing left main coronary occlusion during coronary angioplasty. *Catheterizat Cardiovasc Diagnosis*. 1986;12(5):324-6.
13. Ghosh PK, Alber G, Schistek R, Unger F. Rupture of guide wire during percutaneous transluminal coronary angioplasty. Mechanics and management. *J Thoracic Cardiovasc Surgery*. 1989;97(3):467-9.