

Sheer Sinisterness of Uncontrolled Diabetes Mellitus: Parapharyngeal Abscess

Apoorva P¹, Rajesh Radhakrishna Havaladar², Shilpa Mallapur³,
Redkar Aditya Achyut⁴, Neema K⁵

How to cite this article:

Apoorva P, Rajesh Radhakrishna Havaladar, Shilpa Mallapur, *et al.*/Sheer Sinisterness of Uncontrolled Diabetes Mellitus: Parapharyngeal Abscess/RFP J ENT Allied Sci 2023;8(1):15-19.

ABSTRACT

Diabetes mellitus is a common disease in developing countries and the complications are feared by many physicians and surgeons. One such rare and dangerous complication is parapharyngeal abscess which can spread via its intricate anatomical site to other deep neck spaces. We present the case of a young male who is a known uncontrolled diabetic presented to us with neck swelling and toxic symptoms and managed successfully with timely surgical intervention by exploring all neck planes to evacuate purulent material thus speeding up the recovery process.

Keywords: Parapharyngeal space; Diabetes Mellitus; Klebsiella; Abscess; DNSI.

INTRODUCTION

Deep neck space infections involve fascial planes and spaces of the head and neck. Because of complications related to the compression of upper airway, sepsis or septic shock or acute respiratory syndrome they can be life-threatening.¹ Incidence

of deep neck space infections are higher in cases of immunocompromised individuals and diabetics.

This is a case report of a patient with uncontrolled Diabetes Mellitus presenting as a case of deep neck space infection.

CASE REPORT

A 28 year old Male patient, belonging to socio-economic Class I as per Modified BG Prasad's Classification May 2022² presented to ENT OPD with swelling over right lateral aspect of the neck since 5 days and pain while swallowing accompanied by fever with chills. There is no history suggestive of any dental infection. Patient is a known diabetic since 5 years, not on regular medications. His Random Blood Sugar level was 352 mg/dl at presentation.

Author Affiliation: ^{1,2}Assistant Professor, ³⁻⁵Post Graduate Resident, Department of ORL and HNS, KAHER Jawaharlal Nehru Medical College, Belagavi, Karnataka 590010, India.

Corresponding Author: Redkar Aditya Achyut, Post Graduate Resident, Department of ORL and HNS, KAHER Jawaharlal Nehru Medical College, Belagavi, Karnataka 590010, India.

E-mail: adiredkar@hotmail.com

Received on: 00.00.2023

Accepted on: 00.00.2023

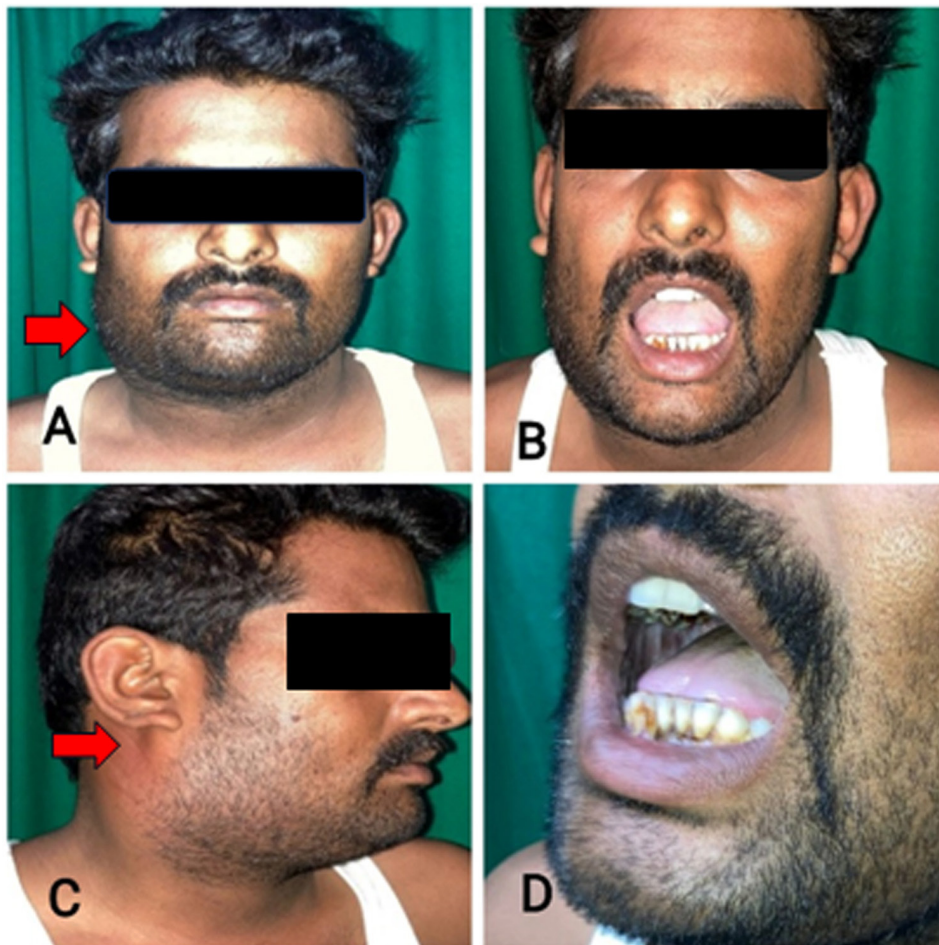

Fig. 1: Pre-operative image

On detailed clinical examination, a diffuse swelling measuring 3x5 cm was noticed at right lateral aspect of the neck in the upper cervical region pushing the lobule of the pinna superiorly and anteriorly (Fig. 1A, 1C). Skin over the swelling was warm to touch, tender, tense and reddish in colour (Fig. 1C). Patient’s mouth opening was restricted to two fingers (Fig. 1B) and had a foul smelling breath and a poor oral hygiene. Teeth were stained because of chronic tobacco consumption

(Fig. 1D). On oropharyngeal examination, the anterior tonsillar pillar of the right side along with the right tonsillar fossa and lateral pharyngeal wall was pushed medially. Posterior pharyngeal wall was congested.

All routine blood investigations were sent and patient was started on intravenous broad spectrum antibiotics as empirical therapy covering wide range of Gram positive and Gram negative organism.

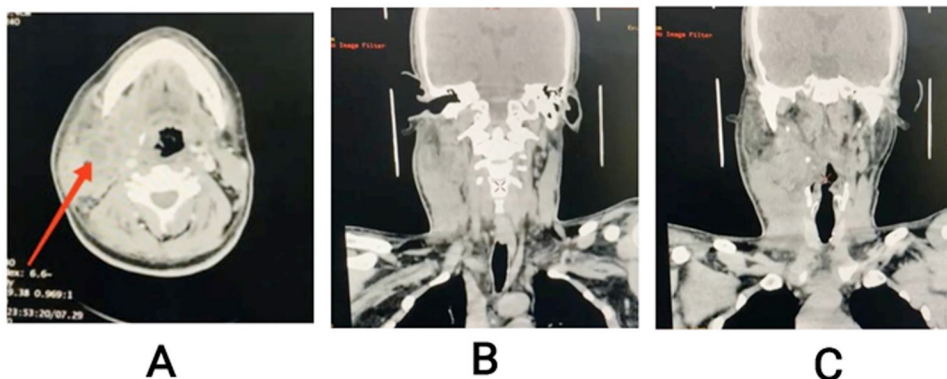


Fig. 2: Contrast enhanced Computed Tomography of neck – Axial and coronal views

A contrast enhanced CT scan of the neck was performed, showing conglomerated lymph node mass with areas of necrosis in the right level 2 region, medially extending into parapharyngeal space, laterally till sternocleidomastoid muscle with multiple sub-centimetric nodes involvement of all levels, encasement of carotid vessels on right side, compressing the right internal jugular vein.

Insulin was started in view of raised Glycosylated Haemoglobin (HbA1C - 12%) and due to presence of ketone bodies in the urine. Ophthalmology reference was given and Diabetic Retinopathy was ruled out.

Patient was shifted to the operation theatre and under general anaesthesia, Incision and Drainage of the abscess was done after making an incision over the area of maximal fluctuance. Following evacuation of the abscess contents, the abscess wall was curetted, and loculations between

adjacent neck spaces were broken down by digital dissection. Pus was sent for culture and sensitivity testing and histopathological evaluation and result was awaited. The cavity was packed by medicated ribbon gauze. Intraorally, the tonsil that was pushed medially returned to its normal position. Hence, intraoral exploration was not done.

Daily dressings of the cavity were done with mixture of Metronidazole Infusion IP (0.5%w/v) and Povidone Iodine Solution IP (10%w/v) wash and ribbon gauze soaked with Povidone Iodine Solution IP (10%w/v) was packed into the cavity. The edges of the cavity were digitally manipulated to drain out any residual pus. On post operative day 3 through microbiological reports we learnt that Gram staining of the pus showed plenty pus cells with Gram positive Bacilli and Gram negative Bacilli and Gram positive cocci.

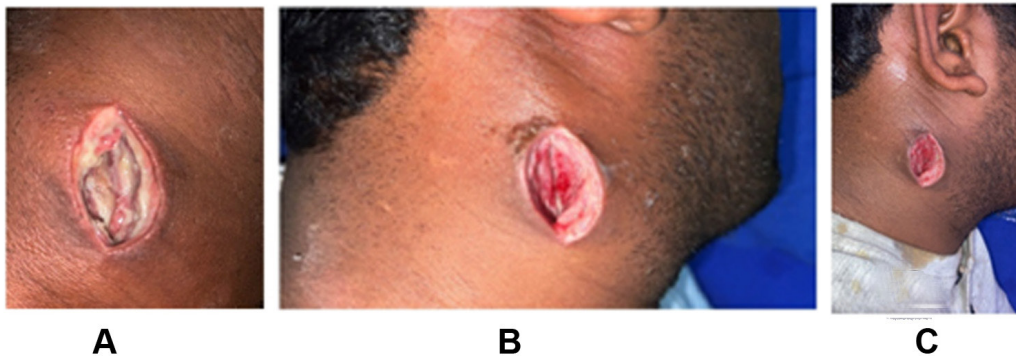

Fig. 3A: Wound image on post-operative Day 7. B: Wound image on Post-operative day 12. C: Wound image on Post-Operative Day 15.

On post-operative day 7, report for culture and sensitivity was available according to which the isolated microorganism was *Klebsiella pneumoniae* and was sensitive to most of the preferred antibiotics.

Regular dressings were done for a period of 28 days till the borders of the cavity naturally approximated following which secondary suturing was done. Raised blood sugar levels were managed by physicians throughout the hospital stay using fixed dose insulin and oral hypoglycemic agents. Patient was discharged on oral antibiotics on post operative day 29 and came for follow up on post operative day 40 showing drastic clinical and symptomatic improvement. (Fig. 4)

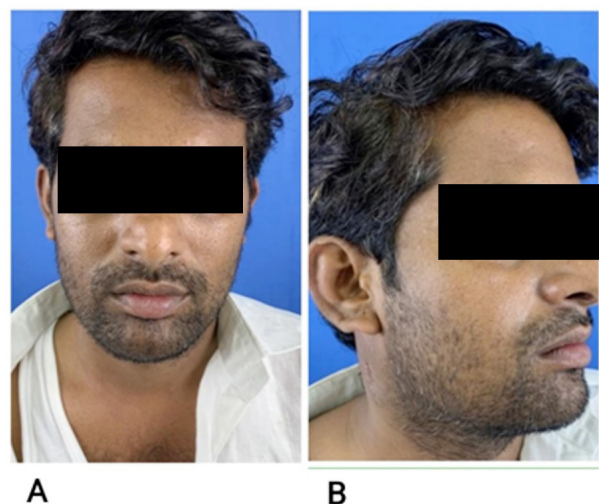

Fig. 4: Follow up clinical photograph on Post-Operative Day 40.

DISCUSSION

A combination of fever, enlargement or tenderness of the neck mass, and overlying erythema indicates that the mass belongs to an inflammatory etiology like deep neck space infections. The most prevalent cause of DNSI happens to be tonsillitis among children whereas Dental infections in adults.^{1,9} DNSI often starts as cellulitis of soft tissue involving an isolated region adjacent to the main source of infection, however the further spread is kept in check by body's natural defence system and the neck's fascial layers. However, in cases of diabetic individuals DNSI has extensive inflammation and tend to spread in the neck with alarming seriousness.³ In uncontrolled diabetics there is decreased bactericidal action due to declined neutrophil function leading to impaired phagocytosis. Systemic hyperglycemia tends to hamper the functioning of normal immune system such as neutrophil function, cellular immunity, complement fixation which plays a major role to keep the spread of infections in control.⁴ According to the study by Gino Marioni *et al*, in a series of 233 cases of DNSI most commonly isolated organism was found to be Gram positive anaerobic cocci followed by Streptococcus group of pathogens.⁵ According to a case series of 54 patients with DNSI done in New Delhi by R Meher, A Jain *et al* most positive cultures were polymicrobial and the most common single isolated species were found to be of Staphylococcus Aureus.⁶ The organism isolated in this case was Klebsiella pneumoniae which also according to Huang TT *et al* who performed his study in Taiwan, becomes the most common bacteria isolated in DNSI in diabetics.⁷ CT Scan is the most preferred radiological investigation for deep neck space infections. MRI are generally not done as they are costlier and take more time to finish the scan⁸ According to Case series on 173 patients done by Bakir S *et al*, as per radiological correlation the most common involved site was the submandibular space followed by the peritonsillar space and the third commonly involved being the parapharyngeal space.⁹ In this case, the space involved is the parapharyngeal space. Contrast enhanced CT (CECT) scan is sensitive (91%) for the identification of extent of the deep neck infections and to distinguish cellulitis from abscess. Contrast enhanced CT helps to decide whether surgical intervention is needed or not as cases with findings

of cellulitis respond to medical treatment, whereas those with abscesses are aggressive, and may require surgical treatment.⁹ In deep neck space infections penicillin with a b-lactamase inhibitor (eg. amoxicillin with clavulanic acid) or a b-lactamase resistant antibiotic (such as cefuroxime, imipenem, or meropenem) in combination with a drug that is highly effective against most anaerobes (such as metronidazole) is recommended for optimal empirical coverage.¹⁰ Combined intra oral drainage was not done in this case fearing the complication of fistula which can form, hence only external drainage was preferred in this case. Also the return of the tonsil to its normal position further gave us an indication that all pockets were drained adequately. Parhiscar A, Har-El recommend early surgical drainage as the standard treatment choice for all cases of DNSI¹¹ however, many authors like Eftekharian A, Roozbahany NA *et al* believe that surgical treatment is needed in only a few cases where as many of the cases are treated with intravenous antibiotic coverage.¹² Based upon this study and through previous article search on DNSI we propose that geographical location does play a role in deciding the prognosis of the problem and also in terms of the expected microbiological variant. The duration of hospital stay also corresponds to one's pre-disease glycaemic control. Patients of uncontrolled diabetes mellitus with higher glycaemic index tend to have a longer hospital stay, like this patient in the study who had a total hospital stay of 29 days.

CONCLUSION

Deep Neck Space Infections is a serious problem which requires immediate surgical intervention. Proper surgical drainage and removing all loculi completely ensures faster recovery and healing of the wound. Radiological imaging is helpful as in this case and thus the approach was planned better and the potential complication can be averted. Good glycaemic control is needed for optimum control in known diabetics. Oral hygiene is of utmost importance to prevent such an issue. Proper antibiotic coverage for both aerobic and anaerobic organisms is needed during the course of hospital stay and also after discharge. Standard dressing protocols must be followed while addressing the wound. Regular dressing must be done under all aseptic precautions.

REFERENCES

1. Guo, Bei-CyuanMDa,b; Wu, Han-Ping MD, PhDa,b,c,*. Deep neck infections with mediastinum abscess and respiratory failure in a pediatric patient: A case report. *Medicine Case Reports and Study Protocols* 2(7):p e0122, July 2021. | DOI: 10.1097/MD9.0000000000000012.
2. Pentapati, Siva Santosh Kumar; Debnath, DhruvajyotiJ.. Updated BG Prasad's classification for the year 2022. *Journal of Family Medicine and Primary Care* 12(1):p 189-190, January 2023. | DOI: 10.4103/jfmprc.jfmprc_1478_22.
3. Hasegawa J, Hidaka H, Tateda M, Kudo T, Sagai S, Miyazaki M, Katagiri K, Nakanome A, Ishida E, Ozawa D, Kobayashi T. An analysis of clinical risk factors of deep neck infection. *Auris Nasus Larynx*. 2011 Feb; 38(1):101-7. Doi: 10.1016/j.anl.2010.06.001. Epub 2010 Jul 6. PMID: 20609540.
4. Caccamese Jr JF, Coletti DP. Deep neck infections: clinical considerations in aggressive disease. *Oral MaxillofacSurg Clin North Am* 2008; 20:367-80. Doi: 10.1016/j.coms.2008.03.001.
5. Marioni G, Staffieri A, Parisi S, *et al.* Rational diagnostic and therapeutic management of deep neck infections: analysis of 233 consecutive cases. *Ann Otol Rhinol Laryngol*. 2010;119(3):181-187. Doi: 10.1177/000348941011900306.
6. Meher R, Jain A, Sabharwal A, Gupta B, Singh I, Agarwal AK. Deep neck abscess: a prospective study of 54 cases. *J Laryngol Otol*. 2005;119(4):299-302. Doi: 10.1258/0022215054020395.
7. Huang TT, Liu TC, Chen PR, Tseng FY, Yeh TH, Chen YS. Deep neck infection: analysis of 185 cases. *Head Neck*. 2004;26:854-860.
8. Lalakea ML, Messner AH. Retropharyngeal abscess management in children: current practices. *Otolaryngol Head Neck Surg* 1999;121: 398 - 405.
9. Bakir S, Tanriverdi MH, Gun R, *et al.* Deep neck space infections: a retrospective review of 173 cases. *Am J Otolaryngol*. 2012;33(1):56-63. Doi: 10.1016/j.amjoto.2011.01.003.
10. Vieira F, Allen SM, Stocks RSM, *et al.* Deep neck infections. *Otolaryngol Clin N Am* 2008;12:459-83. <https://doi.org/10.1016/j.otc.2008.01.002>.
11. Parhiscar A, Har-El G (2001) Deep neck abscess: a retrospective review of 210 cases. *Ann OtolRhinolLaryngol* 110(11):1051- 1054.
12. Eftekharian A, Roozbahany NA, Vaezeafshar R, Narimani N. Deep neck infections: a retrospective review of 112 cases. *Eur Arch Otorhinolaryngol*. 2009;266(2):273-277. Doi: 10.1007/s00405-008-0734-5.