

Top Loading Washing Machine Related Hand Injuries: An Uncommon Household Injury, A Study Regarding The Injury Pattern and Treatment

Raghuram Menon¹, Krishna Kumar KS²,
Ajit Kumar Pati³, Sinnet P Roy⁴

How to cite this article:

Raghuram Menon, Krishna Kumar KS, Ajit Kumar Pati *et al.*/Top Loading Washing Machine Related Hand Injuries: An Uncommon Household Injury, A Study Regarding The Injury Pattern and Treatment/RFP Journal of Plastic Surgery and Transplantation. 2023;4(2):81-86.

Abstract

Background: Washing machines can be seen in every household and there are few reports of upper extremity injuries caused by them. Here we discuss Our experience with this mode of injury and describe the pattern of cases seen by us over a three-year period and how they were managed.

Methods: This is a retrospective analysis of injuries which happened due to washing machines over the last 3 years from August 2019 to August 2022. Follow up period ranged from 3 months to 2 years. Only injuries distal to the wrist joint were included in the study.

Results: There were 14 patients. Age group ranged from 8 to 18 years with a mean age of 12 years.

All injuries were severe in nature with a bony involvement and there is a high possibility of vascular compromise. 7/14 cases had vascular compromise and vascular repair was attempted in 6 of the 7 cases. 2 cases had total amputation at the level of Distal interphalangeal joint.

Conclusions: There is less awareness amongst the public regarding the health hazards of this seemingly innocuous household appliance and we feel there is a need for the public to be aware how devastating this appliance can be if due care is not taken and the companies also need to take efforts to develop improved safety protocols for the same. Prompt assessment and treatment with microsurgical techniques can help in managing and providing optimal outcome for such injuries.

Keyword: Washing Machine Injury; Replant; Revascularisation.

Abbreviations: Ppx - Proximal phalanx, Mpx - Middle phalanx, CFF - Cross finger flap, PIPJ - Proximal interphalangeal joint, DIPJ - Distal interphalangeal joint,

Author Affiliation: ¹Senior Specialist, ²Head of Department, ³Senior Consultant, Plastic Surgery, Aster MIMS Hospital, Govindapuram, Calicut 673016, Kerala, India.

Corresponding Author: Raghuram Menon, Senior Specialist, Plastic Surgery, Aster MIMS Hospital, Govindapuram, Calicut 673016, Kerala, India.

E-mail: rgplasticdoc@gmail.com

Received on: 18-07-2023

Accepted on: 29-08-2023

INTRODUCTION

The first studies on washing machine injuries were of Wringer machine injuries which were used in America in the late nineties and the injuries ranged in severity from mild abrasive burns to partial and full-thickness skin losses.^{1,2} Most of the literature is with respect to Wringer machines, according to the United States Consumer Product

Safety Commission³, there were 19,109 injuries from 1993 till year 2000 due to wringer machines but now the Wringer machine design has become redundant and such machines are not in use nowadays.

There is no such data regarding washing machine injuries in India till now.

The new machines now-a-days can be broadly classified into the top loading and the front loading and we will be discussing the former as all the injuries were encountered with the Top loading variant. We encountered injuries ranging from joint dislocations to total amputations. The injury occurs when the individual accidentally puts his hand inside the machine whilst it is still spinning or when an attempt is made to remove the clothes from the machine and the hand gets caught in the spinning clothes.

MATERIALS AND METHODS

We did a retrospective analysis of injuries which happened due to washing machines over the last 3 years from August 2019 to August 2022. Follow up period ranged from 3 months to 2 years.

There were 14 cases. 8 males and 6 females. The age group ranged from 8 years to 18 years with mean age as 12 years. Only injuries which were distal to the wrist were included in the study. Over the last 3 years there were 3 cases of forearm injuries with fracture of both bones of the forearm when the hand was caught in the washing machine, which was primarily managed by the orthopaedic team, these cases were not included.

The level of injury and the procedures performed have been described below. (Table 1)

Table 1: Age, level of injury and the procedure performed in our series

Age/Sex	Digit affected	Diagnosis	Fracture/dislocation	Procedure
13/F	Right Index	Near Total Amputation Right Index Ppx Base	Ppx Epiphysis	Replant / Revascularization
13/M	Right Index	Near Total Amputation Right Index Ppx Base	Ppx Epiphysis	Revascularization with Volar vein graft
16/M	Right Index	Near Total Amputation Right Index Mpx Neck	Mpx Neck	Extended CFF
8/M	Right Ring	Total amputation Right Ring DIPJ	DIPJ	CFF
10/M	Right Index	Crush Amputation Right Index PIPJ / Mpx Neck	Mpx Neck / PIPJ dislocation	Debridement / K wire fixation
12/F	Right Mid	Crush Amputation right Mid PIPJ	PIPJ dislocation	Debridement / K wire fixation
9/F	Right Mid	Near Total Amputation Right Mid Ppx base	Ppx Epiphysis	Revascularization with Volar Vein graft
14/M	Right Index	Near total Amputation right index Mpx Shaft	Mpx Shaft	Revascularisation
11/M	Right Mid	Total amputation Right index DIPJ	PIPJ	Stump closure
14/M	Right Index	Near Total Amputation Right Mid Ppx base	Ppx Epiphysis	Revascularization with volar vein graft
10/F	Right Mid	Near total Amputation Right Mid Mpx Shaft	Mpx Shaft	Replant - > Stump closure
8/F	Right Index	Total amputation Right index DIPJ	DIPJ	CFF
12/F	Right Index	Near total amputation Right Index Ppx base	Ppx Epiphysis	Replant / Revascularization
18/M	Right Mid	Crush Amputation Tight Mid Mpx Neck	Mpx neck	Debridement / K wire fixation

RESULTS

There were 14 patients. Age group ranged from 8 to 18 years with a mean age of 12 years. 6 were females, 8 were males.

In all the patients the right hand was involved. The commonest digit involved was the index (8 patients) followed by middle (5 patients) and then ring (1 patient).

All 14 patients had some form of injury to the bony framework in the form of amputation or fracture or dislocation.

2/14 sustained a total amputation which was at the level of the DIPJ. 12/14 patients had some form of soft tissue attachment and of these 12 patients, 7 patients had vascular compromise.

5/12 patients had a fracture through the epiphysis of the Ppx and the remaining 7/12 had fractures or dislocations.

Classically the term replant is used for those cases

Table 2: Grading of severity of washing machine injuries

Grading	Description of injury
1	Bone and / or soft tissue injury without vascular compromise
2	Bone and soft tissue injury with only arterial compromise
3	Bone and soft tissue injury with arterial and venous compromise
4	Total amputation

where the distal part was completely detached and the term revascularisation was used in cases where there is some soft tissue attachment, but in our case series we have used the term replantation where there was both arterial and venous compromise and revascularization in those where there was arterial insufficiency only.

There were 7 cases with vascular compromise out of which 3 needed repair of both arteries and veins (replant), 2 of these 3 cases had the fracture through the epiphysis of Ppx and one at the level of the shaft of Mpx in all cases bone shortening was done and replant was attempted, in one case there was progressive congestion of the digit and we had to amputate the digit and do stump closure on Post-operative day 5, the other 2 digits survived, one patient had venous congestion which was managed with nail bed scratching and instillation of heparinized saline for 7 days, the digit survived with mild necrosis over the fingertip (Fig. 1). One digit survived completely. Remaining 4 cases had only arterial compromise, and needed only arterial repair. 3 out of the four cases needed reconstruction with vein grafts (Fig. 2), in 1 patient primary repair was possible. Post-op was uneventful in all the cases.

3 patients sustained total amputation at the DIPJ, 2 patients underwent a Cross finger flap and 1 patient underwent stump closure.³ patients had injury to the soft tissue and bony framework without vascular compromise, and they underwent

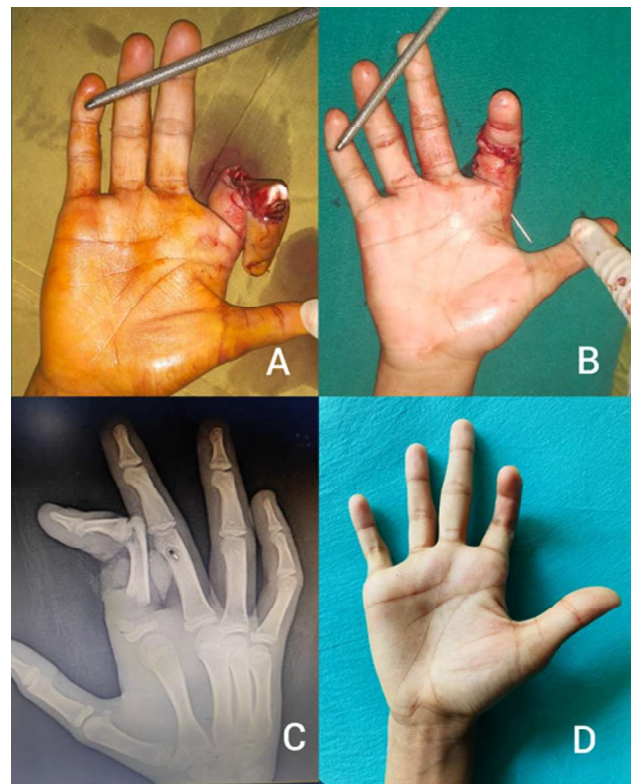


Fig. 1: A/B - Near total amputation with Injury to both arteries and veins / Fracture noted through the epiphysis
C - After replant
D - 7 months follow up with mild digital shortening

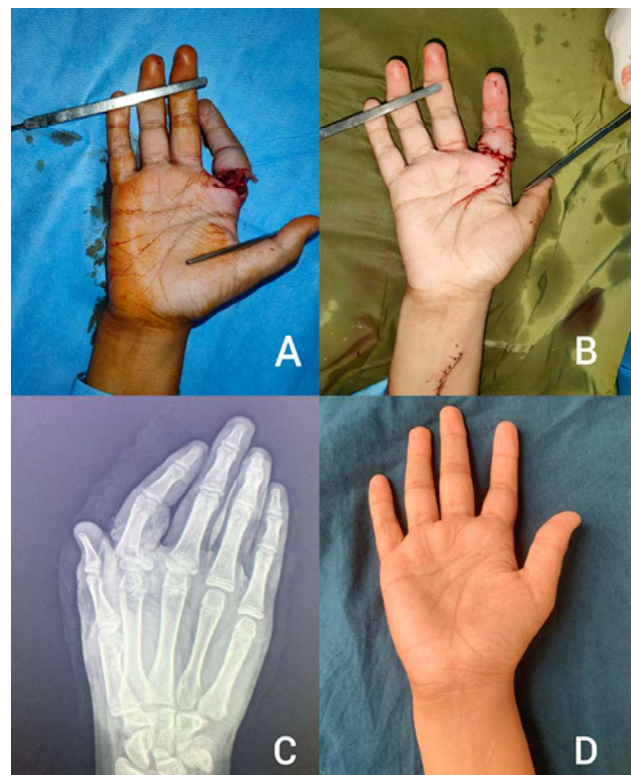


Fig. 2: A/B - Injury to Index with avulsed digital arteries / Revascularisation done with Volar vein graft
C - Fracture noted through the Epiphysis
D - 6 months follow up

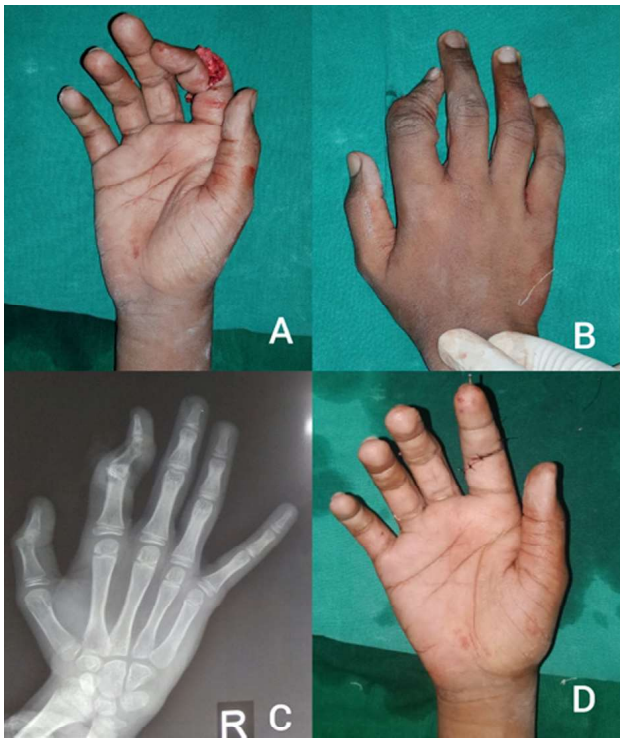
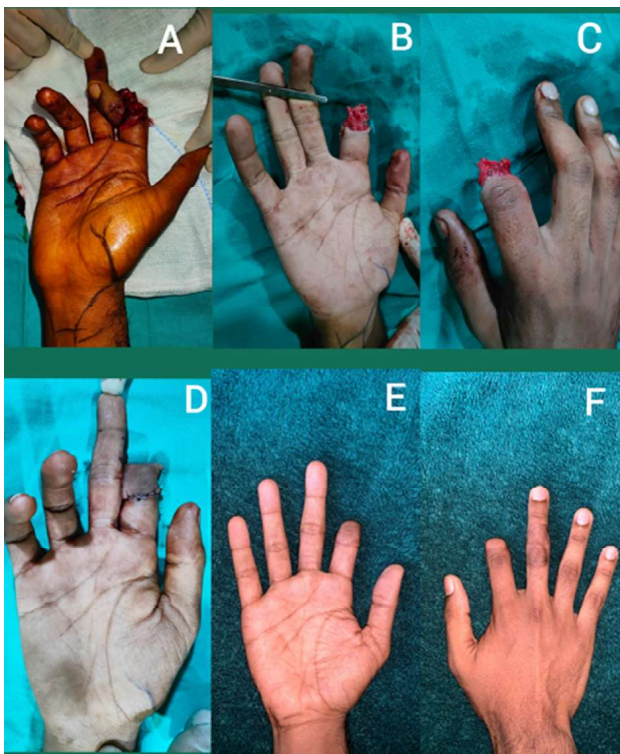

Fig. 3: A/B- Near total amputation of index without vascular compromise
B - Dislocation at level of the PIPJ
C - After K wire fixation

debridement with k wire fixation (Fig. 3).

One patient with near total amputation with



A/B/C - Replant not attempted as no useable veins were found distally intraoperatively
D/E/F - Extended cross finger flap was done to cover both the volar and dorsal aspect of the digit to preserve PIPJ movement

vascular compromise, was given the option of exploration and revascularization, but intraoperatively vessels were found to be avulsed and hence procedure was abandoned and the patient underwent an extended CFF (Fig. 4).

We have classified these injuries into 4 grades (Table 2). Grade 1 being injuries without vascular compromise and where bony fixation with soft tissue repair is adequate, Grade 2 injuries have arterial compromise, and need reconstruction of the arterial inflow along with bone and soft tissue work, Grade 3 injuries there is arterial and venous compromise, such cases are severe and mostly the finger will only be attached with a flexor tendon +/- minimal amount of soft tissue and will need repair of both the arteries and veins, Grade 4 injuries imply total amputation of the digit.

DISCUSSION

Injuries due to a washing machine is a relatively uncommon mode of household injury and most of the patients come in the paediatric age group, this occurs when the individual inserts his hand inside the machine while it is spinning, even though the spinner motor shuts off by default on opening the lid of the machine, the spinning does not stop immediately and if the hand is inserted during this time there is a high probability of the digit or even the complete limb being entangled in the clothes and causing injury. Injuries described in literature can range from mild abrasion to total amputation with a mangled upper extremity 3. This torsional force causes the entangled digit to rotate and results in the bony and soft tissue injury, most of which are severe and result in devascularization of the digit and some times total amputation.

Warner *et al.* studied 405 cases of automatic washing machine injuries that occurred over eight years with data obtained from the United States Consumer Product Safety Commission and reported a fracture rate of 15.3%, dislocation/avulsion/amputation rates of 2.9%. The mean age of victims in their study was 4 years and most were males 4.

We had 14 patients in our series with a mean age of 12 years. In all the patients the right hand was involved and all were right hand dominant. The commonly affected digits were the index and middle as these are the leading digits and had the highest probability of coming in contact with the spinner. All 14 patients had injury to the bony apparatus indicating the torsional force and severity of injury, 2/14 sustained total amputation

and that was at the level of the DIPJ, in both these patients' replantation was not offered because of the nature of injury.

All the remaining patients 12/14 had some form of bony injury out of which 5/12 patients had a fracture through the epiphysis of the Ppx and the remaining 7/12 had fractures or dislocations.

The high number of epiphyseal fractures may be because the growth plates are the softest and weakest sections of the skeleton, and the torsional force on the digit translates into a fracture at a relatively weak part of the bony framework.

All fractures and dislocations were fixed using k wires as it was the simpler and less time consuming method, dislocations were fixed as there was detachment of all collateral ligaments and the volar plate rendering the joint unstable after reduction. K wires were removed at 4 weeks.

Revascularisation and replantation in these cases can be a challenge because of the avulsion nature of the injury 5,6. There were 7 cases with vascular compromise out of which 3 needed repair of both arteries and veins, and in these 3 cases there was attachment only with the flexor tendons, 2/3 of these cases had an epiphyseal fracture through the Ppx in all the 3 cases the artery was found to be contused and after freshening the arterial edges primary repair was not possible hence bone was shortened away from the joint to facilitate tension free anastomosis. Venous compromise was noted in two of the three cases. One digit was salvaged using nail bed scratching and heparinization but we lost one digit because of progressive venous congestion. Remaining 4 cases had only arterial compromise. 3/4 cases needed reconstruction with vein grafts, in 1 patient primary repair was possible. In all cases the vessels were found to be contused and primary repair was not possible after freshening of the vessel edges. Bone shortening was not done in 3 cases as the fracture was through the epiphysis and we wanted to avoid any further injury to the growth plate with bone shortening. Vein grafts were harvested from the volar wrist. In one case fracture was at the level of the Mpx shaft and bone was shortened proximally and distally, following which primary repair was possible. All cases who underwent replantation or revascularization were started on heparin infusion for 5 days.

Patients without vascular compromise underwent k wire fixation with soft tissue repair and 3 patients underwent cover with a Cross finger flap and one patient opted for stump closure only.

All the patients are on follow up and a longer

follow up time will be needed to observe them for any growth abnormalities.

Washing machine injuries are severe in nature as all the cases (100%) had a bony component and 50% (7/14) cases had a vascular compromise requiring microsurgical techniques to re-establish the blood flow. So, we need additional safety mechanisms in place to prevent such injuries. Even though front loading washing machines are safer and use lesser amount of water, in developing countries like India top loading machines are more common as these are cheaper than the front loading type, even though the machine shuts off automatically once the top lid is opened the spinner continues to rotate because of inertia before it comes to a complete standstill. More fail safes like another lid which will cover the spinner and will open only once the machine stops spinning needs to be incorporated in the design by the manufacturers. A time delay feature in the lid lock using a thermal element has been patented any may find its way into newer models 7. The general public also needs to be more aware and specific instructions need to be given to the buyers during purchase. Easy to note warning signs also need to be in place on the machine for the public to read. The machines also need to be kept in places which are not easily accessible by children.

CONCLUSION

Salvaging a digit which has been devascularized due to a washing machine can be a challenge because of the severe crush component and avulsion injury associated with these injuries but careful patient selection with good microsurgical technique can help us in providing predictable results, there should be a low threshold in using vein grafts as and vessels should be trimmed till we get anatomically healthy vessels under the microscope, this can be aided with bone shortening when needed. Prevention is the need of the hour and manufacturers should take note and come up with better designs to prevent such unfortunate mishaps.

REFERENCES

1. Posch, J. L., & Weller, C. N. (1954). Mangle and severe wringer injuries of the hand in children. *JBJS*, 36(1), 57-74.
2. Plotsker, E., Wolfe, E. M., Slavin, B. R., White, N., Cook, J., & Panthaki, Z. J. (2022). A characterization of home maintenance equipment related hand and lower arm injuries. *Journal of clinical orthopedics and trauma*, 31, 101943.

3. Golden, G. T., Fisher, J. C., & Edgerton, M. T. (1973). "Wringer arm" reevaluated: a survey of current surgical management of upper extremity compression injuries. *Annals of surgery*, 177(3), 362.
4. Warner, B. L., Kenney, B. D., & Rice, M. (2003). Washing machine related injuries in children: a continuing threat. *Injury Prevention*, 9(4), 357-360.
5. Yamano, Y. (1985). Replantation of the amputated distal part of the fingers. *The Journal of hand surgery*, 10(2), 211-218.
6. Tamai, S. (1982). Twenty years' experience of limb replantation—review of 293 upper extremity replants. *The Journal of hand surgery*, 7(6), 549-556.
7. Hapke, K. A., & Osvatic, M. (2007). U.S. Patent No. 7,251,961. Washington, DC: U.S. Patent and Trademark Office.

