

## Role of Regenerative Technology in Skin Graft Donor Site

Kada Sri Vidhul<sup>1</sup>, Ravi Kumar Chittoria<sup>2</sup>, Barath Kumar Singh P<sup>3</sup>

### How to cite this article:

Kada Sri Vidhul, Ravi Kumar Chittoria, Barath Kumar Singh P/ Role of Regenerative Technology in Skin Graft Donor Site/RFP Journal of Plastic Surgery and Transplantation. 2023;4(2):67-69.

### Abstract

Skin grafting is one of the most common procedures done in the Departments of Plastic and General Surgery. The development of novel and inventive tissue regeneration strategies has been sparked by complex wound patterns.<sup>1,2</sup> The surgical team has successfully adopted advanced regenerative medicine technologies to enhance the results of skin graft donor site healing. This review article provides a summary of the benefits of using a regenerative technology in skin graft donor site.

**Keywords:** Regenerative Technology; Skin Graft; Donor Site; Management.

## INTRODUCTION

Plastic surgery has undergone gradual evolution over time, the basic concept of methods of reconstruction ranked by complexity has been preserved and propagated in multiple forms. Most descriptions start with closure by secondary intention, followed by direct closure, skin grafting and flap. The complex wound pattern has initiated efforts to create new and innovative techniques in tissue regeneration. Multidisciplinary team has effectively adapted advanced regenerative

techniques to improve outcomes. We employed regenerative technology at the skin graft donor site wound management in this case. We highlight the technology used in the management of our patient in this article.

## MATERIALS AND METHODS

This study was done at tertiary care hospital after obtaining approval of departmental scientific and ethical committee. Informed consent was obtained from the patient. This is a prospective descriptive non randomised case study about a 27 year old male who presented with raw area secondary to trauma for which skin grafting was planned from donor site on the contralateral thigh. The skin graft was harvested from the thigh. The following regenerative technologies were applied during wound management of the donor site raw area. Autologous platelet rich plasma (APRP) was sprayed over the raw area in the donor site after harvesting the graft. (Fig. 1) The same was repeated for the second time after 1 week. Low Level Laser therapy application over the raw donor site area

---

**Author Affiliation:** <sup>1</sup>Junior Resident, Department of Surgery, <sup>2</sup>Professor, Head of IT Wing and Telemedicine, Department of Plastic Surgery & Telemedicine, <sup>3</sup>Senior Resident, Department of Plastic Surgery, Jawaharlal Institute of Postgraduate Medical Education and Research, Pondicherry 605006, India.

**Corresponding Author:** Ravi Kumar Chittoria, Professor, Department of Plastic Surgery, Jawaharlal Institute of Postgraduate Medical Education and Research, Pondicherry 605006, India.

**E-mail:** drchittoria@yahoo.com

**Received on:** 28-01-2023

**Accepted on:** 13.02.2023

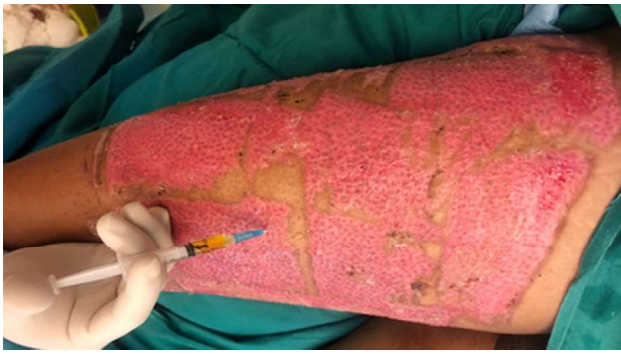


Fig. 1: APRP application over the skin graft donor site

for a duration of 10 minutes once in a week. (Fig. 2). The second session was given to the donor site after 10 days, again for a duration of 10 minutes. The dressing for the raw donor site was done

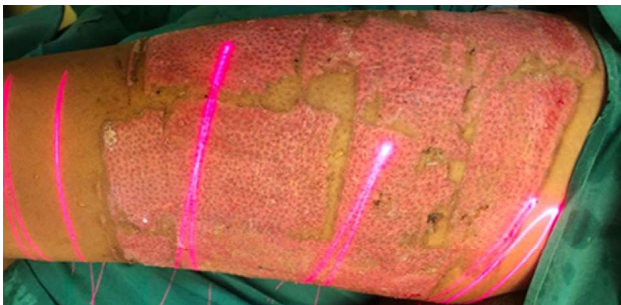

Fig. 2: Low Level Laser therapy

using collagen dressing. (Fig. 3) Negative pressure wound therapy was then applied onto the wound during closure. (Fig. 4)

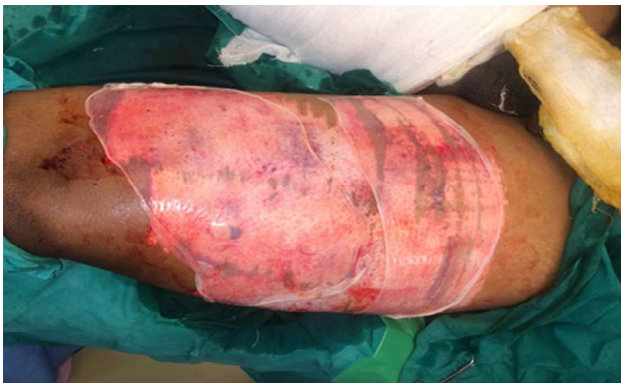

Fig. 3: Collagen application over the skin graft donor site

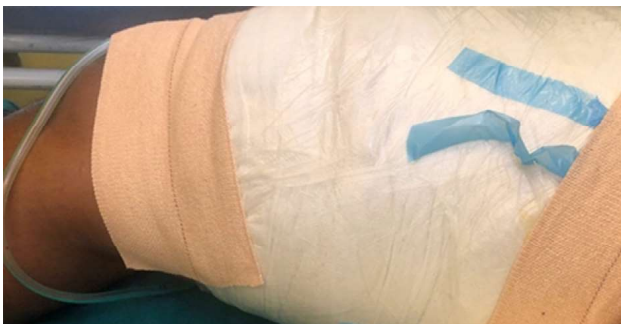

Fig. 4: Negative Pressure Wound Therapy over the skin graft donor site.

## RESULTS

The skin graft donor site showed adequate healing by the regenerative technology application (fig. 5). Patient was compliant with all the above techniques we have used for regeneration. No complications were noted post procedure. Patient was discharged successfully.

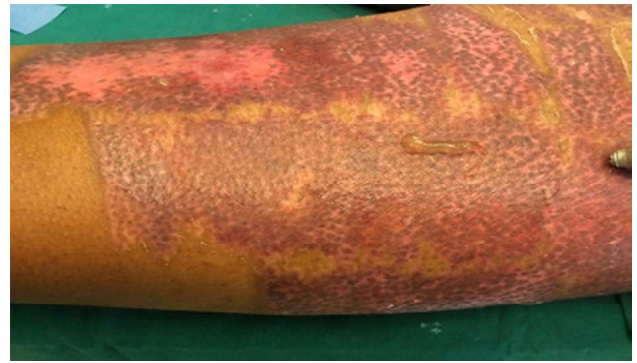

Fig. 5: Healed skin graft donor site on day 17

## DISCUSSION

The patient initially underwent regenerative therapies for improving granulation over the wound. The study effectively employed collagen dressings, autologous platelet rich plasma application, Low level laser therapy, Negative wound pressure therapy. Wet collagen was used as a scaffold for tissue regeneration of the wound bed for further intervention. It also takes into consideration factors that help the reconstructive surgeon determine the best possible option to achieve the three reconstruction goals, namely, form, function, and aesthetics.<sup>3,4</sup> The factors that aid the judgment of a reconstruction specialist, including wound complexity, surgeon skill, resources (and technology) available, and patient requests, form the boundaries of the reconstructive grid. Collagen has low antigenicity, and supports cellular growth. Wound healing and regeneration involve cell proliferation, cell migration, cell differentiation, and interaction between the different components in which collagen may affect healing not only at the final stage but also in the very early stage of healing.<sup>4,5</sup> The advantages of collagen membrane are availability in various sizes, ease of removal, ability to remain stable at room temperature, and, the ability to incorporate drugs or growth factors that can be delivered in a controlled manner Low Level Laser Therapy (LLLT) is one of the proposed modalities to improve wound healing and scar quality.<sup>6,7</sup> LLLT is claimed to increase collagen synthesis, decrease inflammation and has a positive impact on scar

remodeling.<sup>8,9</sup> Negative Pressure Wound therapy (NPWT) involve removal of exudates and infectious materials and contraction of wound margin. NPWT has been shown to be safe and effective in post debridement wounds.<sup>9</sup> Hence NPWT was started, and size of the wound was measured at the time of change of dressing.<sup>10,11</sup> Platelets act as regulators of inflammation, angiogenesis, cell migration, and proliferation with the release of various growth factors and anti-inflammatory cytokines which is thought to help in faster and better healing of the wounds. Autologous platelet rich plasma (APRP) has growth factors which when injected in the wound site or sprayed, act at the intracellular level to bring about cell proliferation and healing of a wound.<sup>12</sup>

## CONCLUSION

The application of regenerative medicine therapies in the treatment of skin graft donor site wound healing. It has significantly aided in improving the outcomes. Regenerative medicines is continuing to evolve and may become the standard of care for effective management of tissue wounds. This has to be applied to the multiple number of cases for the assessment.

## REFERENCES

1. Mathes SJ, Nahai F. *Reconstructive Surgery: Principles, Anatomy & Technique*. Vol. 2. New York: Churchill Livingstone; St. Louis: Quality Medical; 1997.
2. Gottlieb LJ, Krieger LM. From the reconstructive ladder to the reconstructive elevator. *Plast Reconstr Surg*. 1994;93: 1503–1504.
3. Wong CJ, Niranjana N. Reconstructive stages as an alternative to the reconstructive ladder. *Plast Reconstr Surg*. 2008;121: 362e–363e.
4. Erba P, Ogawa R, Vyas R, Orgill D. The reconstructive matrix: A new paradigm in reconstructive plastic surgery. *Plast Reconstr Surg*. 2010;126: 492–298.
5. Turner NJ, Badylak SF. Biologic scaffolds for musculotendinous tissue repair. *Eur. Cell Mater*. 25, 130–143 (2013).
6. Saurabgupta *et al*. Effect of LowLevel Laser Therapy (LLT) On the Severity of Post-Burn Immature Scars: A Randomized Control Study. *International Journal of Clinical and Diagnostic Research Volume 8, Issue 1, Jan-Feb 2020*.
7. Chittoria R.K., Kumar S.H. (2018) Low level Laser Therapy (LLL) in Wound Healing. In. *Recent Clinical Techniques, Results, and Research in Wounds*. Springer; 2018, Cham.
8. Mester E, Hazay L, Fenyo M, Kertész I, Toth N, Jàrànyi Z *et al*. The biostimulating effect of laser beam. In: Waidelich W, editor. *Optoelectronics in Medicine*. Berlin: Springer; 1982: 146-152.
9. Posten W, Wrone DA, Dover JS, Arndt KA, Silapunt S, Alam M. Low level laser therapy for wound healing: mechanism and efficacy. *Dermatol Surg*. 2005 Mar; 31 (3):334–40.
10. Morykwas MJ, Argenta LC, Shelton-Brown EI, McGuirt W. Vacuum-assisted closure: a new method for wound control and treatment: animal studies and basic foundation. *Ann PlastSurg* 1997;38: 553–62.
11. Venturi ML, Attinger CE, Mesbahi AN, Hess CL, Graw KS. Mechanisms and clinical applications of the vacuum-assisted closure (VAC) device: a review. *Am J Clin Dermatol* 2005;6: 18.
12. Dhurat R, Sukesh M. Principles and Methods of Preparation of Platelet-Rich Plasma: A Review and Author's Perspective. *J Cutan Aesthetic Surg*. 2014;7(4):189–97.

