

# Role of Onion Extract in Preventing Abnormal Scarring in Scald Injury

Krithika Lakshmi Arumugam<sup>1</sup>, Ravi Kumar Chittoria<sup>2</sup>, Amrutha J S<sup>3</sup>

## How to cite this article:

Krithika Lakshmi Arumugam, Ravi Kumar Chittoria, Amrutha J S/Role of Onion Extract in Preventing Abnormal Scarring in Scald Injury/RFP Journal of Dermatology 2023;8(2):95-97.

## ABSTRACT

Use of silicone derivative and onion extract had been reported in the prevention of abnormal scarring. Our study showed the preventive use of silicone derivative plus onion extract gel on abnormal scars after scald burns. Next to silicone based products, onion extract or cepalin has been highlighted as one potential anti-scarring agent over recent years. Based on several studies, onion extract alone or in combination with allantoin and heparin seems to alleviate the wound healing process and appears beneficial for preventional application in fresh scars. During each visit, pain and itching scores were graded by the patients and scar characteristics were observed by surgeons using the Vancouver scar scale (Table 1). Pain and itch score values from patients' who applied silicone derivative plus onion extract gel. No adverse events were reported by any of the patients. A silicone derivative plus onion extract gel is safe and effective for the preventing the abnormal scarring after scald burn injury.

**Keywords:** Onion extract; Scarring; Scald injury.

## INTRODUCTION

Abnormal scarring like keloid and hypertrophic scar treatment remains a challenging problem for clinicians. When scars are formed, physical conditions and emotions are affected. They may also cause significant functional and cosmetic

impairment. Hypertrophic scars tend to cause itch and pain symptoms, which are responsible for a reduction in quality of life. Cost of treatment for these scars may also be expensive depending on individual factors such as genetic, type of wound and infection. The normal duration for treatment of scars is approximately 6 months and it may extend to 1-2 years so scar prevention therapy is an interesting alternative in the management of scars.

Onion extract is reported to have anti-inflammatory, anti-microbial, anti-proliferative, and regenerative activities. Several clinical trials have confirmed that this gel is well tolerated and helps prevent pathological scarring and improves preexisting scars. Quercetin from onion extract is found in various scar treatment products. It has anti inflammatory, bacteriostatic and collagen down regulatory properties. Topical agents, with a composition of silicone derivative plus onion extract in semi liquid gel form, may improve hypertrophic scarring. In this article, we present

**Author Affiliation:** <sup>1</sup>Junior Resident, Department of Plastic Surgery, <sup>2</sup>Professor, Department of Plastic Surgery & Telemedicine, <sup>3</sup>Senior Resident, Department of Plastic Surgery, Jawaharlal Institute of Postgraduate Medical Education & Research, Pondicherry 605006, India.

**Corresponding Author:** Ravi Kumar Chittoria, Professor, Department of Plastic Surgery & Telemedicine, Jawaharlal Institute of Postgraduate Medical Education & Research, Pondicherry 605006, India.

**Email:** drchittoria@yahoo.com

**Received on:** 26.05.2023

**Accepted on:** 30.06.2023

our experience in the preventive use onion extract gel for abnormal scars after scald injury.

## MATERIALS AND METHODS

This study was conducted in the Department of Plastic Surgery in a tertiary care institute. Informed

consent was obtained. The patient under study was 37 year old male with no comorbidities presented with 2nd degree 5% TBSA involving head and neck (Fig. 1) due to accidental spillage of hot water over head under the influence of alcohol. He was unaware of the incident at that time. No one was with him at that time. He slept off and in the morning one episode of involuntary movement of




Fig. 1: 2nd degree 5% TBSA involving head and neck

both upper limb and lower limb. Patient admitted in Burns ICU, managed with antibiotics, IV Fluids, analgesics. Dressings done, regenerative therapies done and scar management (like onion extract and silicone sheet) done (Fig. 2). VSS score at the time of admission was 6/13. ENT, Ophthalmology, Neurology, Psychiatry consultations done. At discharge wound healed well and Videodermoscopy done and scar VSS score at the time of discharge is 3/13.

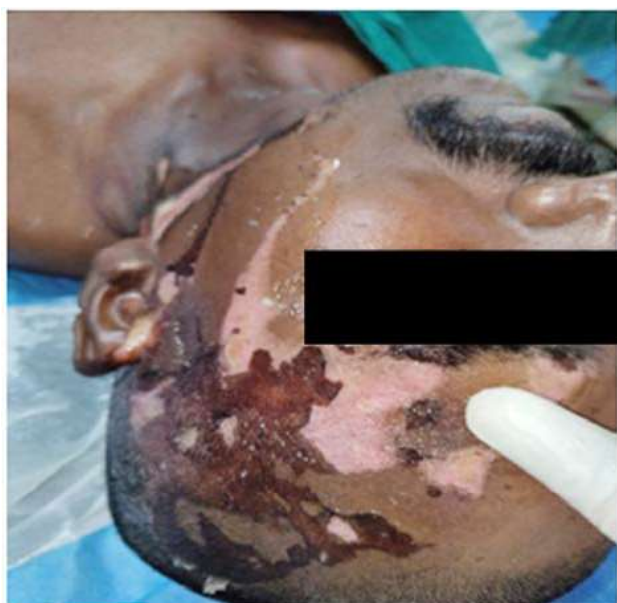

Fig. 2: Onion extract application

## RESULT

It was found that onion extract gel has plausible efficacy in the prevention and treatment of scar formation. It could improve subjective symptomatic pain, itching symptoms and hyperpigmentation of scar.

## DISCUSSION

*Extractum cepae* acts in an anti-inflammatory manner and is bactericidal.<sup>1</sup> It is currently believed that the flavonoids (quercetin and kaempferol) in onion extract play the main role in reducing scar formation through inhibition of fibroblast proliferation and collagen production.<sup>2</sup> Fibronectin expression was suppressed by quercetin suggesting a strong inhibitory effect of this compound on production of fibronectin.<sup>3</sup> Transmission electron microscopy was performed on keloid fibroblasts with and without quercetin.<sup>4</sup> Keloid fibroblasts without quercetin showed markedly higher density of ECM fibers in a homogenous ECM, but no ECM deposition was seen in the fibroblasts treated with quercetin, indicating a strong effect of quercetin in the suppression of ECM production and deposition by keloid fibroblasts.<sup>5</sup> It has been further demonstrated that several flavonoids

inhibit the antigen induced histamine release from human basophils, which may be of certain importance since there is evidence to the effect that histamine may accelerate collagen formation.<sup>6</sup> In the treatment of open wounds, scar prophylaxis using an onion extract gel should be delayed until complete epithelialization of the wound.<sup>7</sup> Treatment usually continues over several weeks to months.<sup>8</sup> While side effects are generally very low, treatment containing onion extract might be slightly irritating in facial areas, particularly in younger children.<sup>9</sup> Till to date, preventing pathologic scarring remains undoubtedly more effective than treating it. Next to specific surgical techniques and appropriate general after care of fresh wounds, a multitude of scar gels, creams, patches, and ointments are available and are being promoted for scarless wound healing. Next to silicone based products, onion extract or cepalin has been highlighted as one potential anti-scarring agent over recent years. Based on the recently published German guidelines on scarring, onion extract containing scar creams may be considered as additional therapy for active hypertrophic scars and for post surgical prophylaxis of excessive scarring.

## CONCLUSION

Scarring following surgery or trauma is difficult to predict, and both physicians and their patients are highly concerned with minimizing scar appearance and value even small improvements in scarring as clinically meaningful. Although its underlying study data remains in part contradicting regarding its efficacy, onion extract containing scar creams appear to positively influence scar texture, height, and associated symptoms compared to placebo or untreated control.

## REFERENCES

1. Draelos ZD. The ability of onion extract gel to improve the cosmetic appearance of postsurgical scars. *J Cosmet Dermatol* 2008;7:101-4. [PubMed] [Google Scholar]
2. Li Tsang CW, Lau JC, Chan CC. Prevalence of hypertrophic scar formation and its characteristics among the Chinese population. *Burns* 2005;31:610-6. [PubMed] [Google Scholar]
3. Bock O, Schmid Ott G, Malewski P, Mrowietz U. Quality of life of patients with keloid and hypertrophic scarring. *Arch Dermatol Res* 2006;297: 433-8. [PubMed] [Google Scholar]
4. Stavrou D, Weissman O, Winkler E, Yankelson L, Millet E, Mushin OP, Liran A, Halk J. Silicone based scar therapy: a review of the literature. *Aesth Plast Surg* 2010;34:646-51. [PubMed] [Google Scholar]
5. Phan TT, Lim IJ, Sun L, Chan SY, Bay BH, Tan EK, *et al.* Quercetin inhibits fibronectin production by keloid-derived fibroblasts. Implication for the treatment of excessive scars. *J Dermatol Sci.* 2003;33(3):192-4. [PubMed] [CrossRef]
6. Augusti K. Therapeutic values of onion (*Allium cepa* L.) and garlic (*Allium sativum* L.). *Indian J ExpBiol* 1996;34:634-40. [PubMed] [Google Scholar]
7. Nedelec B, Shankowsky HA, Tredget EE. Rating the resolving hypertrophic scar: comparison of Vancouver scar scale and scar volume. *J Burn Care Rehabil* 2000;21:205. [PubMed] [Google Scholar]
8. Chung VQ, Kelley L, Marra D, Jiang SB. Onion extract gel versus petrolatum emollient on new surgical scars: prospective double-blinded study. *Dermatol Surg.* 2006;32(2):193-7. [PubMed]
9. Koc E, Arca E, Surucu B, Kurumlu Z. An open, randomized, controlled, comparative study of the combined effect of intralesional triamcinolone acetonide and onion extract gel and intralesional triamcinolone acetonide alone in the treatment of hypertrophic scars and keloids. *Dermatol Surg.* 2008;34(11):1507-14. [PubMed]
10. Ho WS, Ying SY, Chan PC, Chan HH. Use of onion extract, heparin, allantoin gel in prevention of scarring in chinese patients having laser removal of tattoos: a prospective randomized controlled trial. *Dermatol Surg.* 2006;32(7):891-6. [PubMed]

