

Study of Maternal Outcome in Relation to Placental Location In Tertiary Care Centre

Alka Patil¹, Amod Mahajani², Bhagyashree Badade³, Sayli Thavare⁴

Author's Affiliation:

¹Professor and Head of Department, ²Associate Professor, ^{3,4}Junior Resident, Department of Obstetrics and Gynecology, Annasaheb Chudaman Patil Memorial Medical College, Dhule, Maharashtra 424002, India.

Corresponding Author:

Amod Mahajani, Associate Professor, Department of Obstetrics and Gynecology, Annasaheb Chudaman Patil Memorial Medical College, Dhule, Maharashtra 424002, India..

E-mail: alkapatil@rediffmail.com

Abstract

Introduction: Placenta, which serves as a crucial foeto-maternal interface, is the central support organ for developing fetus, hence its abnormalities can have an impact on both maternal and fetal health. Abnormal placentations result in poor placental perfusion and placental insufficiency. USG of placenta is primarily directed toward determining the location of the placenta and identifying its abnormalities in later weeks of pregnancy.

Aims & Objective: To determine the maternal outcome depending on second trimester placental location between 18-24 weeks and to determine whether it can be considered as a screening tool to predict these complications.

Method: This retrospective study is conducted at ACPMMC Dhule. 200 pregnant women with singleton pregnancy, who delivered after 28 weeks of gestation during 1 year period, who had prior documentation of placental location on the basis of antenatal USG performed between 18-24 weeks were included. Placental position was then categorized as anterior, posterior, fundal, lateral and placenta previa. Association of placental location with maternal outcome was then noted.

Result: Out of 200 women, the frequency of central placentation was 166 (82.8%), lateral placentation 32 (16.2%) and placenta previa was 2 (1%). Central placentation had an abnormal outcome in 77(46.3%) and lateral placentas with abnormal outcome were 18(57.2%). Abnormal maternal outcomes like Antepartum haemorrhage (APH) (23%), Pregnancy Induced Hypertension (PIH) (29%), Intrauterine Growth Restriction (IUGR) (16%), Preterm Birth (15%) were more in lateral placentation. Placenta Previa carried an increased risk of Postpartum haemorrhage (PPH) and Adherent placenta.

Conclusion: In our study, there is a significant association between lateral placentation and abnormal pregnancy outcomes. Therefore, placental location by Ultrasound examination done in second trimester is used as non-invasive predictor in determining adverse maternal outcomes

Keywords: Placental location; Lateral location; Abnormal outcome; Maternal outcome; Second trimester; Ultrasound.

How to cite this article:

Alka Patil, Amod Mahajani, Bhagyashree Badade, et al. Study of Maternal Outcome in Relation to Placental Location In Tertiary Care Centre. Indian J Matern Fetal Neonatal Med. 2020;7(2):77-82.

Introduction

Placenta, which is the vital link between the mother and her developing fetus is of critical importance for maternal and fetal well-being. It is the organ of metabolic exchange and has a potent endocrine function during pregnancy.¹ The size and site of placental implantation determines its blood supply and thereby the pregnancy outcome.²

❖ Placental location has been attributed to:

1. Preterm birth
2. IUGR
3. Preeclampsia
4. IUD or stillbirth
5. The progress of labour
6. Low APGAR score.²

The placental location and uterine artery resistance bears a relationship. Centrally located placenta receives equitable distribution of blood flow from both the uterine arteries, whereas in laterally located placenta, the uterine artery closer to the side of placenta has a low resistance and a good blood flow, which causes disparity in blood distribution. The other uterine artery supplying the placenta located laterally receives less contribution from the collateral circulation and facilitates development of preeclampsia and IUGR.²

Vidhu V Nair et al. proposed following mechanism for development of preeclampsia and IUGR:

❖ Failure of trophoblastic invasion into spiral arteries causes:

1. Faulty remodelling of utero placental arteries
2. Inadequate perfusion and
3. Release of cytokines, immunomodulators and leukotriene's into maternal circulation resulting in endothelial dysfunction and thereby producing preeclampsia and IUGR.²

Non-invasive abnormal doppler waveforms of uterine arteries in second trimester would suggest defective uterine perfusion due to placental implantation when one uterine artery is the dominant supply of the inter villous flow.²

Posterior wall of uterus is thicker and longer than the anterior wall and thereby its blood supply also differ between the walls.

❖ Posterior placental location has been attributed to development of:

1. Preterm labour

2. Foetal distress
3. Increase in foetal heart rate decelerations
4. Incidence of meconium stained liquor
5. Stillbirth
6. Increased caesarean rates.²

❖ Central placenta are more frequent and have a higher risk of:

1. Adherent placentas
2. Premature rupture of membranes
3. Preterm births²

Placental scanning is considered as an inherent component of every obstetric ultrasound.¹ Placental location may reliably be assessed by 16 weeks gestation.³ During an obstetrical ultrasound, evaluation of the fetus is chief priority but often, the other components (placenta, umbilical cord, and amniotic fluid) which represent an integral part of gestation, are arguably not given the attention they deserve. Hence, placental position and morphology should be evaluated in standard obstetric sonogram during second and/or third trimester.

Placenta previa is a severe complication of pregnancy, endangering the lives of pregnant women, hence the impact of placenta previa on pregnancy; delivery and infant outcomes has been extensively studied.⁵ It is an independent risk factor associated with postpartum haemorrhage. It is largely a complication of multiparous women, as only 20% of cases occur in first pregnancies.³ Complete placenta previas and marginal previas are serially monitored for migration over the course of the pregnancy, as most women diagnosed with placenta previa or low lying placenta in the second trimester will have normal placental location by the end of pregnancy.

During the course of clinical treatment of placenta previa, obstetricians should be aware of not only the types of placenta previa (complete and partial or marginal placenta previa) but also the position of placental attachment (anterior uterine wall, posterior wall, whether the placenta overlaps a surgical scar from a previous caesarean section).⁶

Method

This retrospective study was conducted in the Department of Obstetrics and Gynecology at ACPMMC Dhule. 200 pregnant women with singleton pregnancy, who delivered after 28 weeks of gestation during 1 year period from August 2018

to August 2019, who had prior documentation of placental location on the basis of antenatal USG performed between 18-24 weeks were included. Approval from the Institutional Ethics Committee was obtained.

Inclusion Criteria

- All Primi or Multigravid women.
- Women with singleton pregnancy.
- Gestational age between 18-24 weeks.
- All Primi or Multigravid women coming to our OPD, willing for follow up and delivery at the hospital.

Exclusion Criteria

- Patients attending OPD after 24 weeks of gestation.
- Women whose fetus had a structural abnormality.
- Multiple pregnancies.
- Rh incompatibility/fetal hydrops.
- Polyhydramnios/oligohydramnios.
- Females with unknown last menstrual period.
- Intrauterine death at the time of first ultrasonographic examination.

Informed written consent of all pregnant women was taken. The records of 200 subjects were ascertained. All sonographic examinations were performed in the Radiology Department of same institute by the radiologist on same USG machine between 18-24 weeks. It is our departmental policy to offer a routine scan at 18-24 weeks or later if the booking is late where the details of placental location are recorded apart from other parameters. Trans-abdominal scan were performed in maternal supine position using Toshiba nemio ultrasound machine attached to a 3.5 MHz curvilinear transducer.

Maternal demographic information including hospital number, age, parity, LMP, EDD, period of gestation at the time of scan and placental location on second trimester scan were collected. Pregnancy complications and neonatal outcomes were obtained from our hospital records during their routine follow up as per indications and labour room registers.

Based on the placental location in the scan, we categorized each placenta into 6 groups as anterior, posterior, fundal, left lateral, right lateral and placenta previa. For the ease of understanding it was simplified into following categories namely central, lateral location and low lying. Central placental location means those which are uniformly distributed, and it includes anterior, fundal or posterior locations. When the greater portions of placenta are confined to one side it is termed as lateral location which may be on left lateral location or on the right lateral location.

The following maternal outcomes were studied:

- ❖ Maternal Outcomes:
 1. Gestational hypertension / Preeclampsia
 2. Ante partum hemorrhage
 3. Postpartum haemorrhage
 4. Placenta previa rate.

Result

Out of 200 women, the frequency of central placentation was 166 (82.8%), that of lateral placentation was 32 (16.2%) and 2(1%) were placenta previa.

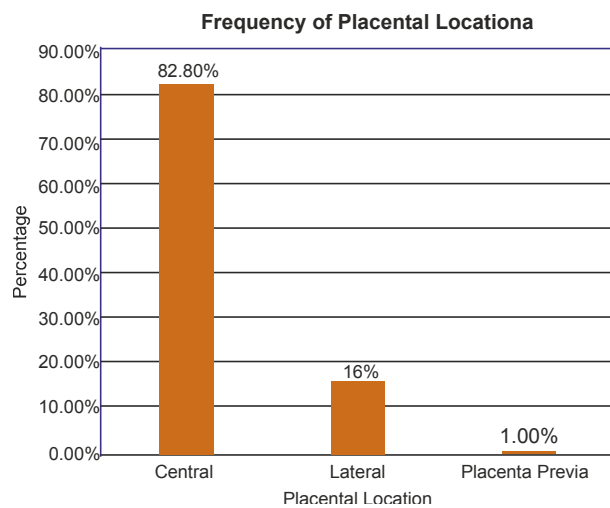


Table No. 1: Frequency of placental location.

Further, the study showed that, amongst 166 (82.8%) of central placentas: 50 (25.1%) had anterior placenta, 35 (17.5%) had posterior placenta and major part 81 (40.2%) was fundal, whereas amongst 32 (16.2%) of the lateral placentation: 7.2% were right lateral and 9% belonged to left lateral group. The frequency of placenta previa was 2 (1%).

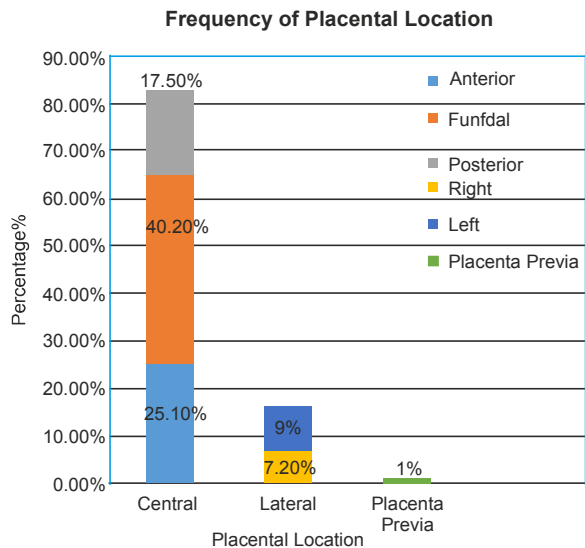


Table No. 2: Frequency of placental location.

Out of total cases, 89 (53.7%) cases with central placentation had normal outcome and 77 (46.3%) had an abnormal outcome, whereas lateral placentas with normal outcome were 42.8% and abnormal outcome was seen in 18 (57.2%) cases.

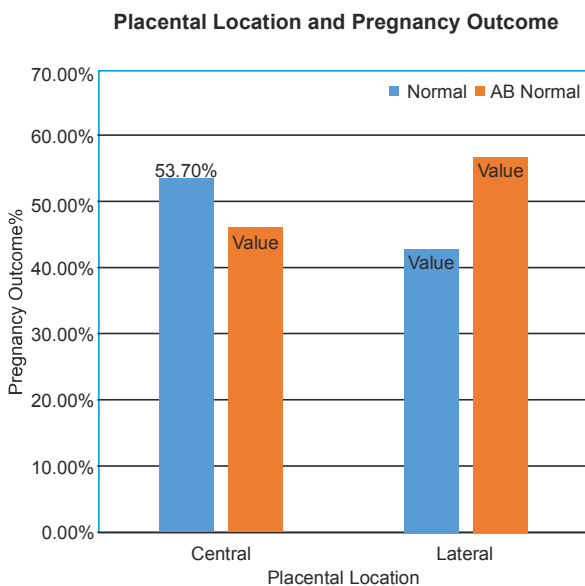


Table No. 3: Placental location and pregnancy outcome.

The number of anterior placenta with abnormal outcome was 22 (44.3%) and with normal outcome was 28 (55.7%). The number of fundal placentae with abnormal outcome was 47 (58.1%) and with normal outcome was 34 (41.9%). The number of posterior placentae with abnormal outcome was 17 (49.4%) and with normal outcome was 18 (50.6%). The number of right lateral placenta with abnormal outcome was 10 (71%) and with normal outcome was 4 (29%). The number of left lateral placenta with abnormal outcome was 11 (61%) and with normal outcome was 7 (39%).

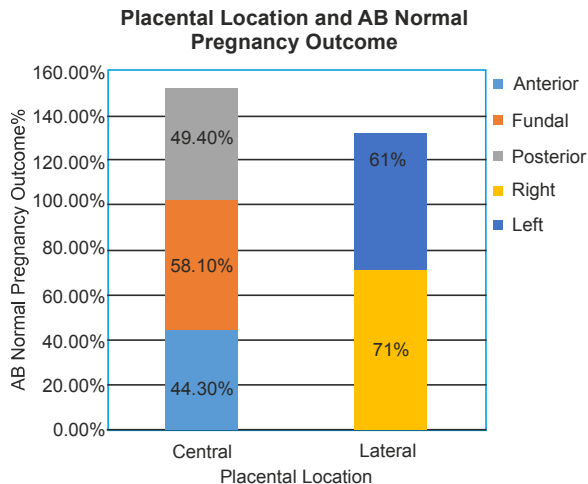


Table No. 4: Placental location and abnormal pregnancy outcome.

Right lateral placenta had majority of abnormal outcomes. Four cases of right lateral placenta were associated with 25% risk of ante partum hemorrhage, five cases were associated with preeclampsia / gestational hypertension (33%), two cases of left lateral placenta were associated with IUGR (16%), three cases were associated with 18% risk of preterm birth.

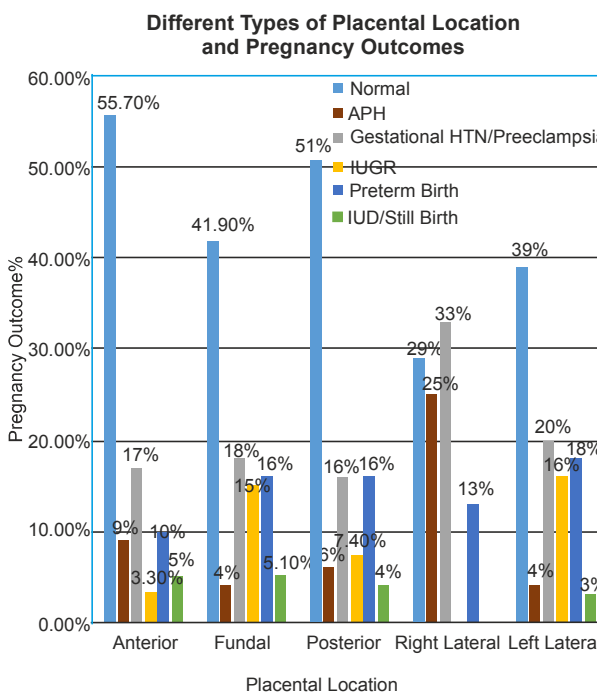


Table No. 5: Different types of placental location and pregnancy outcome.

Discussion

Ultrasonographic (USG) examination of placenta during pregnancy is a vital aid to pregnancy

management.⁷ Such an examination is primarily directed towards:

1. Interpreting signs of placental maturation/aging (the placenta having a limited life span)
2. Determining the exact location and orientation of the placenta within the uterine cavity
3. Identifying development and acquired placental abnormalities in the later weeks of pregnancy.¹

In our study, we found that lateral placenta had major abnormal outcomes. This was comparable with the study done by Singh et al. which showed 38.37% abnormal outcome with central placenta and 53.5% abnormal outcome with lateral placenta and the results were significant. Similarly, Jaisal et al also concluded that lateral placenta was associated with more abnormal outcomes compared to central placenta. Bhalerao et al in 2013 also showed lateral placentation had 2.7 times increased risk of developing pre-eclampsia. Study conducted by Pai et al showed 2.3 times, Fung et al showed 2 times and Kakkar et al, showed 2-fold risk of developing preeclampsia.²

Right lateral placenta had abnormal outcomes like preeclampsia / gestational hypertension, ante partum haemorrhage whereas left lateral location were associated with IUGR and preterm birth.

Study done by Vidhu V Nair reported that anterior placenta carries 9% risk of developing pregnancy induced hypertension. Similar observations were made by Shumaila Zia et al in a retrospective study on 474 patients and concluded that anterior placentation had 3.7 % risk of pregnancy induced hypertension. They also found significant association of anterior placenta with an increased incidence of GDM, BOH, placental abruption, IUGR and IUFD which is comparable to our study where four cases of anterior location were associated with 9% risk of APH, 8 cases had 17% risk of PIH, two cases had 3.3% risk of IUGR, five cases had 10% risk of preterm birth.²

We found fundal location of placenta predisposes women to PIH(15cases:18% risk) , preterm birth(13cases:16% risk). Consistent with our findings, Booth et al. reported a significant association between fundal placentation and PIH. Salvatore et al conducted a prospective cohort study on 1056 patients and concluded that posterior placental location were associated with gestational

hypertension/ preeclampsia with an outcome of 5.5%.² It is presumed that fundal location of the placenta places the weakest point of the membrane over the cervical os and thus predisposes the women to premature rupture of membrane with all of the consequential adverse sequale.⁹

Posterior wall of uterus is thicker and longer than the anterior wall and therefore its blood supply also differ between the walls.² We found 6 cases (16%) of posterior placenta at increased risk of preterm labor. It has also been attributed to PIH, IUFD/ stillbirth, fetal distress.

Torricelli et al conducted a prospective study on 2354 patients and found posterior placental location was associated with preterm labour with an outcome of 59.2%. Shumaila Zia et al concluded that preterm labour were associated with posterior placenta with an outcome of 3.7% .Similar observations were made by Fung et al.²

One of the study by Lin Jing et al. reported placental attachment to the anterior wall in cases of placenta previa as an independent risk factor for postpartum hemorrhage.¹⁰

An increased risk of IUGR has been reported for both high lateral implantations and low implantations.¹¹ In our study, two cases of left lateral placenta were associated with IUGR (16%), three cases were associated with 18% risk of preterm birth.

Conclusion

Placental location in early gestation indicate possibilities of future problems, therefore co-operation of healthcare professionals from multiple disciplines is necessary.⁶

In our study, most common placental location is central location. Normal outcome is associated more in central location. Lateral placenta had major abnormal outcomes like APH, PIH, IUGR and preterm birth. Placenta previa carried an increased risk of PPH and adherent placenta. Our study supports the hypothesis that the location of placenta is associated with pregnancy outcome.

We conclude that second trimester targeted USG at 18-24 weeks can be used as non-invasive predictor to evaluate pregnancies at risk for adverse antepartum, intrapartum and neonatal outcome. Follow up USG or other surveillance techniques can be used to ensure best pregnancy outcomes.

References

1. Narendra Malhotra. Ultrasound in Obstetrics AndGynecology. Pratap Kumar, S Dasgupta, R Rajan. JAYPEE Third Edition, 2000, 110-115.
 2. Nair VV, Nair SS, Radhamany K. Study of placental location and pregnancy outcome. Int J ReprodContraceptObstetGynecol 2019;8:1393-7.
 3. Mary E Norton, Leslie M. Scutt, Vickie A. Feldstein. Callen's Ultrasonography in Obstetrics and Gynecology. Peter Callen.First South Asian Edition,2017, 674-703.
 4. Gizzo S et al. Sonographic assessment of placental location: a mere notional description or an important key to improve both pregnancy and perinatal obstetrical care? A large cohort study. Int J ClinExp Med 2015;8(8):13056-13066
 5. Granfors M, et al. Placental location and pregnancy outcomes in nulliparous women: A population-based cohort study. ActaObstetGynecol Scand. 2019; Volume 98, Issue 8.
 6. Jing, Lin et al. "Effect of site of placentation on pregnancy outcomes in patients with placenta previa." PloS one vol. 13,7 e0200252. 17 Jul. 2018, 13(7).
 7. Chhabra S, Yadav Y, Srujana D, Tyagi S, Kutchi I. Maternal neonatal outcome in relation to placental location, dimensions in early pregnancy. J Basic ClinReprodSci 2013;2:105-9
 8. Booth RT, Wood C, Beard RW, Gibson JR, Pinkerton JH. Significance of site of placental attachment in uterus. Br Med J 1962; 5294: 1732-4.
 9. Zia S.Placental location and pregnancy outcome. J Turkish-German GynecolAssoc 2013; 14: 190-3
 10. Gizzo S et al. Sonographic assessment of placental location: a mere notional description or an important key to improve both pregnancy and perinatal obstetrical care? A large cohort study. Int J ClinExp Med 2015;8(8):13056-13066
 11. Mary E Norton, Leslie M. Scutt, Vickie A. Feldstein. Callen's Ultrasonography in Obstetrics and Gynecology. Peter Callen.First South Asian Edition,2017, 674-703.
-