

# Clinical Anatomy of The Superficial Peroneal

Narendra A Patil<sup>1</sup>, Mohammed Khaleel Ahmed<sup>2</sup>

## How to cite this article:

Narendra A Patil, Mohammed Khaleel Ahmed. Clinical Anatomy of The Superficial Peroneal. Indian J Anat. 2020;9(4):255-259.

**Author's Affiliation:** <sup>1</sup>Assistant Professor, Department of Anatomy, Dr Patnam Mahendra Institute of Medical Science, Chevella, Telangana 501503, India, <sup>2</sup>Associate Professor, Department of Anatomy, Shadan Institute of Medical Sciences and Research, Hyderabad 500086, India.

**Corresponding Author: Narendra A Patil**, Assistant Professor, Department of Anatomy, Dr Patnam Mahendra Institute of Medical Science, Chevella, Telangana 501503, India.

**E-mail:** [dr.mohammedkhaleel786@gmail.com](mailto:dr.mohammedkhaleel786@gmail.com)

## Abstract

**Background:** Superficial peroneal nerve (SPN): It is the nerve of lateral compartment of leg. It is one of the two terminal branches of the common peroneal nerve given at the neck of the fibula, it arises in the substance of peroneus longus on the lateral side of the neck of fibula.

**Methods:** A dissection was done in ten lower extremities (five from female and five from male) that had been well-maintained in a formalin arrangement. The subcutaneous layer was cautiously dissected in every preparation so that distortion of neural structures and their connections would be maintained a strategic distance from quite far. When the nerve structures had been recognized, the accompanying estimations were done: a) distance (in millimeters) from the upper end of the fibular head to the lower prominence of the lateral malleolus; b) number of branches from SPN when it arises through the superficial sural belt; c) distance (in millimeters) from the SPN rise highlight to the lateral malleolus; d) distance (in millimeters) from the SPN division to the lateral malleolus.

**Results:** There were two primary discoveries from these dissections. To begin with, we noticed varieties in the quantity of branches passing through superficial anterior fascia of the leg. A few cases indicated a solitary trunk rise, later partitioning into two branches, while others demonstrated two diverse recently separated cutaneous branches. Second, in both anatomical sorts, a checked variety was seen in the relative distance from the lateral malleolus, emerging at a low, medium or elevated level. Regarding the compartment from which the SPN pierces the superficial fascia, the contrast between single-trunk and two branches ought to be considered.

**Conclusion:** The information got appear to be adequately dependable for normal clinical practice, however it must be considered that successive and significant varieties may happen.

**Keywords:** Surgical anatomy; Superficial peroneal nerve; Anatomical variations.

## Introduction

Superficial peroneal nerve (SPN): It is the nerve of lateral compartment of leg. It is one of the two terminal branches of the common peroneal nerve given at the neck of the fibula, it arises in the substance of peroneus longus on the lateral side of the neck of fibula. It begins on the lateral side of the

neck of the fibula and descends for a short distance between the peroneus longus and peroneus brevis, and then lies in a groove between the peroneus brevis and extensor digitorum longus. At the junction of upper two-third lower one-third of the leg, appears as a division, and soon divides into lateral terminal branches which reach the dorsum of the foot. It gives muscular branch to peroneus

longus and peroneus brevis. It also gives cutaneous branches supply the skin of the lower one third of the lateral side of the leg and dorsum of the foot.

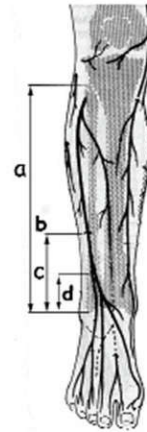
The middle terminal branches of the superficial peroneal nerve cross the ankle and divides into two dorsal digital nerves, one for the medial side of the big toe and other for the second interdigital cleft. The lateral terminal branch of the superficial peroneal nerve also divides into two dorsal digital nerve for the third and the fourth inter-a digital cleft.<sup>1</sup>

The varieties about the shallow peroneal nerve are the non attendance of either the sidelong cutaneous branch or the average cutaneous branch, which are viewed as 8.6% and 0.8%, individually. It has been demonstrated that without the average cutaneous branch, the saphenous nerve innervates the average aspect of the foot, while without the horizontal cutaneous branch, the sural nerve supplies the sidelong aspect of the dorsum of the foot.<sup>2</sup> Sometimes, the shallow peroneal nerve punctures the intermuscular septum and passes from the horizontal compartment into the foremost compartment, following a shallow course. In different cases, the average and sidelong branches partition before the shallow sash is punctured.<sup>3</sup> The average branch might be missing and might be supplanted by the profound peroneal nerve. The nerve has been portrayed as emerging from the nerve to peroneus brevis.<sup>4</sup> The shallow peroneal nerve may bifurcate in the upper aspect of the leg and both the branches may stay in the horizontal compartment.<sup>5</sup> Very seldom the shallow peroneal nerve might be found in the foremost intermuscular septum.<sup>6-8</sup>

## Materials and Methods

A dissection was performed in ten lower limbs (five from men and five from women) that had been preserved in a formalin solution. There were six (58.33%) right legs and four left legs (41.66%), the difference being due to the fact that only in some cases were both lower limbs available. The subcutaneous layer was cautiously dissected in every preparation so that distortion of neural structures and their connections would be maintained a strategic distance from quite far. When the nerve structures had been recognized, the accompanying estimations were done: a) distance (in millimeters) from the upper end of the fibular head to the lower prominence of the lateral malleolus; b) number of branches from SPN when it arises through the superficial sural belt; c) distance

(in millimeters) from the SPN rise highlight to the lateral malleolus; d) distance (in millimeters) from the SPN division to the lateral malleolus. We likewise had recorded where the SPN pierces the sural fascia from the anterior or lateral muscular compartment (Fig. 1).



**Fig. 1:** Measures taken in our examination. a: distance (in mm) from the upper end of the fibular head to the lower distinction of the parallel malleolus; b: number of branches from SPN when it arises through the shallow sural fascia; c: distance (in mm) from the SPN development point to the lateral malleolus; d: distance (in mm) from the SPN division to the lateral malleolus.

Subsequent to finishing these estimations, a deep and wide dissection was performed, particularly in those cases demonstrating a few varieties, so the anatomy of the SPN could be noticed and properly ordered along its whole course. A computer was utilized to sort out and measure all the information procured.

## Results

There were two primary discoveries from these dissections. To begin with, we noticed varieties in the quantity of branches passing through superficial anterior fascia of the leg. A few cases indicated a solitary trunk rise, later partitioning into two branches, while others demonstrated two diverse recently separated cutaneous branches (Table 1). Second, in both anatomical sorts, a checked variety was seen in the relative distance from the lateral malleolus, emerging at a low, medium or elevated level (Fig. 2). Regarding the compartment from which the SPN pierces the superficial fascia, the contrast between single-trunk and two branches ought to be considered. The outcomes for single trunks are appeared in Table 2. Three specimens showed a SPN bifurcation before nerve rise; two of them had a superficial branch piercing the superficial fascia from the anterior compartment

and a second branch emerging from the lateral compartment. In the other specimen, both branches emerged from the anterior compartment (Fig. 2).

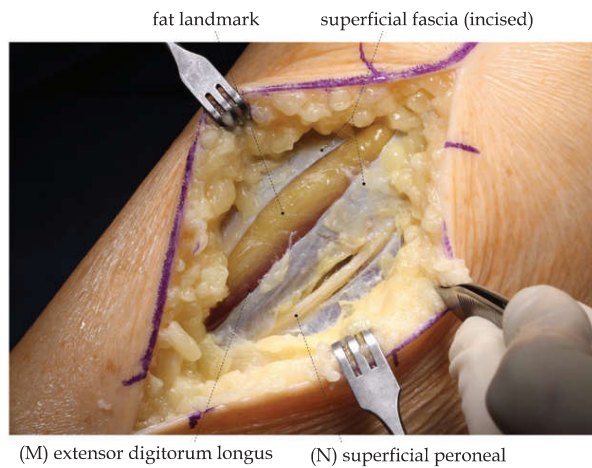


Fig. 2: Case of a superficial peroneal nerve.

Table 1: Frequency of a single-trunk for superficial peroneal nerve and two independent nerve branches when emerging.

	Number of Cases	Percentage
Single-Trunk	8	75%
Two Branches	2	25%

Table 2: Cases with a single trunk for the SPN when emerging.

	Number of Cases	Percentage
Emergence from anterior compartment	2	28.57%
Emergence from lateral compartment	4	57.14%
Emergence on intermuscular septum	1	14.28%

The level at which the SPN pierces the superficial fascia in the leg and enters into the subcutaneous cell tissue is significant. On average, the SPN gets superficial at 117.9 mm proximal to the lateral malleolus; i.e., in 95% of cases SPN emergence is somewhere in the range of 166 and 66 mm over the lateral malleolus, accepting a typical appropriation for this distance (95% confidence interval = mean  $\pm$  2 standard deviation).

Table 3: Peroneal length and emergence point of the SPN.

	Mean $\pm$ SD	Maximum	Minimum
Lateral malleolus-fibular head distance	354.2 $\pm$ 28.3 mm	400 mm	313 mm
Malleolus-emergence distance	117.9 $\pm$ 24.22 mm	135 mm	35 mm
Malleolus-emergence distance in percentage of fibular length	34.52%	42.72 %	11 %

Table 4: Distance between the malleolus and the division of the SPN.

	Mean	Standard Dev.	Maximum	Minimum	Percentage
Division-malleolus distance (all cases)	94.41 mm	68.42 mm	264 mm	35 mm	27.14 %
Single-trunk	65.21 mm	21.53 mm			18.76 %
Two branches	227 mm	54.23 mm			63.17%

This information in millimeters could be deceiving in individuals with extreme morphometric boundaries, and characterizing the development point for the SPN as a level of leg length is substantially more valuable. The level at which the SPN gets superficial was expressed as a percentage of the distance from the fibular head to the lateral malleolus, two palpable bone eminences helping clinical application. As per such estimations, SPN development speaks to 34.52% of the lateral malleolus-fibular head distance; in other words, at the upper two-thirds/lower-third limit level of fibular length (Table 3).

The SPN division level may likewise be significant in some clinical cases. Unmistakably, in cases with the SPN piercing the fascia in the wake of having separated into two branches, the division point is proximal to the rise point. In such cases, we saw that nerve division is on normal 227 mm over the lateral malleolus. This distance speaks to some 63.17% of the distance from the lateral malleolus to the fibular head; i.e., at the upper third/lower two-thirds limit level in the leg. Then again, in (more normal) cases with the SPN piercing the superficial fascia as a single trunk, nerve division is 66 mm proximal to the lateral malleolus; i.e., some 18.76% of the distance from the lateral malleolus to the fibular head, representing to the upper 4/5/lower 1/5 limit level in the leg (Table 4).

## Discussion

Clinical interest in a precise information on SPN courses and connections includes a few strengths. In patients with direct injuries or wounds to the anterolateral part of the distal third of the leg, expected association of this structure must be investigated by methods for delicate assessment in its self-governing innervation region. Neurophysiologists, be that as it may, could be keen on building up the specific point where to put cathodes to acquire an electroneurographic record, and discovering its shallow confinement could be fundamental. There is an actual sign to recognize the SPN just underneath the skin, by methods for a plantar flexion and reversal of the lower leg and foot and, optionally, an aloof flexion of the fourth toe (Fig. 2). Along these lines, the distal subcutaneous

course of the SPN can be recognized.<sup>9-13</sup> In the field of muscular medical procedure, a few specialists in fringe nerve a medical procedure have proposed utilizing this nerve as a vascularized join, since it is generally joined by a little course and vein, or utilizing the engine branches to the peroneal muscles for a neurotization of the front tibial muscle in patients with L4 root wounds (polio, spinal wounds, and others). Neither remedial choice is at present being utilized in clinical practice, yet contemplates have been wanted to survey their likely use soon.<sup>14</sup> On the other hand, in plastic medical procedure little corridors and veins going with the SPN are being utilized in vascularized skin unites.<sup>15</sup>

In some very basic circumstances, for example, arthroscopy, there is a cozy connection between lower leg ports and the danger of injury to the SPN terminal branches.<sup>16</sup> Also, when an anterolateral fasciotomy is performed because of a compartment condition of the leg, SPN position infers a danger for the nerve, wounds and delicate sequelae not being extraordinary.<sup>17</sup> One of the careful moves that may include the most noteworthy danger of SPN iatrogenic wounds is the horizontal methodology normally utilized in fibular osteosynthesis to treat lower leg cracks. The careful doctrine requiring an immediate cut from the skin to the fibula, evading a layer dismemberment, may cause accidental segment of the nerve if the specific position has not been distinguished or an anatomical variation exists. Percutaneous emplacement of pins or screws, for example, those utilized for outside fixing gadgets, or fasteners to obstruct tibialendomedullary nails can likewise cause nerve wounds.<sup>18</sup>

SPN compressive conditions have additionally been portrayed where the nerve penetrates the shallow belt of the leg, causing a clinical picture like a L5 root sickness (dysesthesia on the dorsal surface of the foot and particular toes). This circumstance requires a precise differential analysis.<sup>19</sup>

In all the above circumstances, exact ID of the course of the SPN is critical. Our information is promptly material and are adequately solid for common clinical practice. It ought to be reviewed, nonetheless, that specific significant varieties may happen. In some 75% of cases, the SPN shows up as a solitary nerve trunk, however in the excess 25% of patients it shows up as two separate branches. This must be considered so the second SPN branch isn't harmed in the wake of finding a branch when playing out a surgery.

As indicated by traditional portrayals, the SPN penetrates the shallow belt of the leg from the

parallel compartment (55%), despite the fact that in a not immaterial level of cases (35%) it comes from the foremost compartment. Besides, SPN rise can be found at the upper 66%/lower third cutoff level of the fibular length. Albeit all this information will assist with finding the SPN with a serious level of dependability, it will never be conceivable to arrive at the 100% level. This is the reason a profound information on nerve SPN life structures and great careful abilities to discover the nerve and try not to cause nerve wounds are required.

## Conclusion

The data obtained seem to be sufficiently reliable for usual clinical practice, but it must be taken into account that frequent and important variations may occur.

## Reference

1. Standring S: Gray's Anatomy. 39<sup>th</sup> edition. London: Elsevier Churchill Livingstone; 2005:1504-1505.
2. Blair JM, Botte MJ: Surgical anatomy of the superficial peroneal nerve in the ankle and foot. *ClinOrthop* 1994, 305:229-238.
3. Pacha D, Carrera A, Llusca M, Permanyer E, Molona O, Morro R: Clinical anatomy of the superficial peroneal nerve in the distal leg. *Eur J Anat* 2003, 7(Suppl 1):15-20.
4. Bergman RA, Thompson SA, Afifi AK: Compendium of Human Anatomic Variations. Munich: Urban and Schwarzenberg; 1988:146-147.
5. Browne JA, Morris MJ: Variant superficial fibular (peroneal) nerve anatomy in the middle third of the lateral leg. *Clin Anat* 2007, 20:996-997.
6. Ducic I, Dellon AL, Graw KS: The clinical importance of variations in the surgical anatomy of the superficial peroneal nerve in the midthird of the lateral leg. *Ann Plast Surg* 2006, 56:635-638.
7. Williams E, Dellon L: Intraseptal superficial peroneal nerve. *Microsurgery* 2007, 27:477-480.
8. Mondelli M, Reale F, Cavallaro T: Neuroma of the sural nerve as a complication of stripping of the small saphenous vein. *SurgNeurol* 1997, 48(4):330-332.
9. Simonetti S, Bianchi S, Martinoli C: Neurophysiological and ultrasound findings in sural nerve lesions following stripping of the small saphenous vein. *Muscle Nerve* 1999, 22(12):1724-1726.

10. Drizenko A, Demondion X, Luyckx F, Mestdagh H, Cassagnaud X: The Communicating branches between the sural and superficial peroneal nerves in the foot: a review of 55 cases. *SurgRadiolAnat* 2004, 26(6):447-452.
11. Kosinski C: The Course, Mutual Relations and Distribution of the Cutaneous Nerves of the Metazonal Region of Leg and Foot. *J Anat* 1926, 60:274-297.
12. Canovas F, Bonnel F, Kouloumdjian P: The superficial peroneal nerve at the foot. Organisation, surgical applications. *SurgRadiolAnat* 1996, 18:241-244.
13. Deutsch A, Wyzkowski RJ, Victoroff BN: Evaluation of the anatomy of the common peroneal nerve. Defining nerve-at-risk in arthroscopically assisted lateral meniscus repair. *Am J Sports Med* 1999, 27:10-15.
14. Adkison DP, Bosse MJ, Gaccione DR, Gabriel KR. Anatomical variations in the course of the superficial peroneal nerve. *J Bone Joint Surg Am* 73(1):112-114.
15. Amendola A, Petrik J, Webster-Bogaert S. Ankle arthroscopy: outcome in 79 consecutive patients. *Arthroscopy*.1996; 12(5):565-573
16. Barber FA, Click J, Britt BT. Complications of ankle arthroscopy. *Foot Ankle* 1994;10(5):263-266
17. Blair JM, Botte MJ. Surgical anatomy of the superficial peroneal nerve in the ankle and foot. *ClinOrthopRelat Res* 305:229-238.
18. Bonnin M, Bouysset M. Arthroscopy of the ankle: analysis of results and indications on a series of 75 cases. *Foot Ankle Int* 1999;20(11):744-751.
19. Carson WG Jr, Andrews JR. Arthroscopy of the ankle. *Clin Sports Med* 1987;6(3):503-512.

