

## An Anatomical Study to Identify the Variations in Occipital Artery

Bharat R. Sontakke<sup>1</sup>, Kirubhanand C<sup>2</sup>, Snehal Deulkar<sup>3</sup>, Shital Maske<sup>4</sup>,  
Gayatri Muthiyar<sup>5</sup>, A. M. Tarnekar<sup>6</sup>, Vishwajit Deshmukh<sup>7</sup>

### How to cite this article:

Bharat R. Sontakke, Kirubhanand C, Snehal Deulkar. An Anatomical Study to Identify the Variations in Occipital Artery. 2024;13(1):27-29.

### Abstract

Out of total twenty-one cadavers studied, in a 62 years old male donated cadaver, we found the Right Occipital artery was discovered to be dilated (enlarged). The left occipital artery was normal and unremarkable. The origin and course of both sided occipital arteries was as usual. In vascular lesions, the Occipital artery is a crucial artery. It is also one of the most suitable donor arteries in conditions like aneurysms.

**Keywords:** Occipital artery; Dilated; Enlarged; Vascular lesion.

## INTRODUCTION

The occipital artery emerges from posterior aspect of the External Carotid Artery (at the same level as the Facial artery originates from front side). It passes backwards and upwards beneath posterior belly of digastric muscle superficial to Internal Carotid artery, Internal Jugular vein and 9 to 12 cranial nerves. Here it crosses apex of posterior

triangle of neck. Then passes deep to mastoid process by grooving the temporal bone medial to the mastoid notch. Then the occipital artery reaches underneath the trapezius muscle after crossing the superior oblique, semispinalis capitis and apex of suboccipital triangle. The artery after piercing trapezius muscle 2.5 cm lateral to midline comes to lie on lateral aspect of greater occipital nerve. The artery supplies sternocleidomastoid muscle, mastoid air cells, dura mater of posterior cranial fossa, nearby muscles, cranial surface of the auricle via Sternomastoid, Mastoid, Meningeal, Muscular, Auricular branches respectively. The occipital artery gives a descending branch which provides the chief collateral circulation after ligation of the external carotid or the subclavian artery.<sup>1</sup>

**Author's Affiliation:** <sup>1</sup>Associate Professor, <sup>2</sup>Assistant Professor, <sup>3</sup>Additional Professor, Department of Anatomy, All India Institute of Medical Sciences, Nagpur 441108, Maharashtra, India.

**Corresponding Author:** Vishwajit Deshmukh, Assistant Professor, Department of Anatomy, All India Institute of Medical Sciences, Nagpur 441108, Maharashtra, India.

**E-mail:** drvishwajitdeshmukh@gmail.com

**Received on:** 30.03.2024

**Accepted on:** 15.04.2024

## MATERIAL METHODS

After a study on total twenty-one donated cadavers, we noted a variation in occipital artery in a 62 years old male cadaver. The occipital artery

on both sides was originating from the posterior aspect of external carotid artery at the same level, the facial artery was arising from the front.

#### On Right Side:

The initial segment of Right Occipital artery was discovered to be dilated (enlarged). The dilated (enlarged) part of right occipital artery measures about 3.9 cm in length. Further course of the right occipital was normal as usual (Fig. 1).

We have done H and E staining of the dilated (enlarged) part of the right occipital artery. We found fibro-intimal hyperplasia, fibrotic tunica media with calcification and infiltration. This suggests the changes due to chronic hypertension (Fig. 2). Masson's trichrome staining performed on the same tissue, confirmed the above-mentioned observations (Fig. 3).



Fig. 1: Dilated (enlarged) Right Occipital Artery in a Cadaver

#### On Left Side:

The left occipital artery was normal and unremarkable.

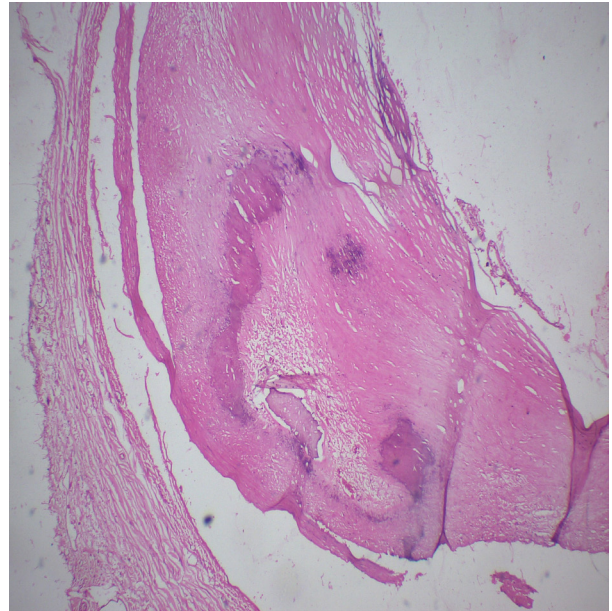


Fig. 2: H and E staining of Dilated (Enlarged) Right Occipital Artery

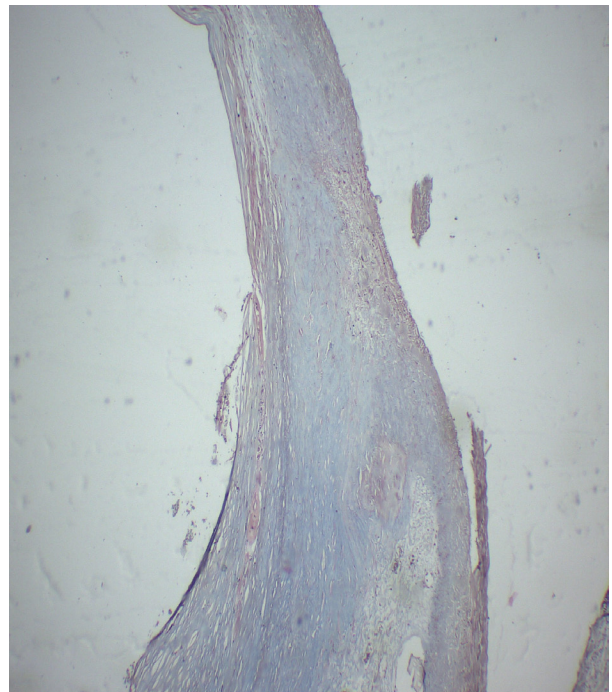


Fig. 3: Masson's Trichrome staining of Dilated (Enlarged) Right Occipital Artery

No variation in other vasculature of body was observed.

### **DISCUSSION**

Numerous variations of the occipital artery have been documented in the literature. Sometime the occipital artery may anastomose with the

vertebral artery.<sup>2</sup> The occipital artery may share a common origin with another artery like posterior auricular artery, the ascending pharyngeal artery and the superior thyroid artery etc. An author described the crossing of the Occipital artery and Greater Occipital nerve. This may damage the nerve and may be the reason for Idiopathic Greater Occipital Neuralgia.<sup>3</sup> In our study no any crossing was noted. In vascular lesions, the Occipital artery is a crucial artery. It is also one of the most suitable donor arteries in conditions like aneurysms. In case of occlusion disorders or in cases aneurysm (particularly giant or fusiform aneurysms), the Occipital artery is used as extra to intracranial bypasses for both the anterior or posterior circulation. So, the detailed knowledge of this vessel is extremely necessary to choose this vessel as donor vessel.<sup>4,5</sup>

The occipital artery has a tortuous course passing through multiple layers of suboccipital muscles. Here needs layer by layer dissection. To avoid multilayer dissection, an author described a landmark-based novel anterograde approach to harvest the occipital artery.<sup>6</sup> As per literature in some cases, the internal carotid artery may give rise to the occipital artery.<sup>7</sup> An author found the islanded Occipital artery flap useful in management of defects in posterior scalp region. This method provides one-stage hair bearing scalp tissue for closure of large defects as well the closure of donor site<sup>8</sup>.

Another author found the resection of occipital artery remarkably lowering the success rate of occipital migraine headache surgery. So, it is not necessary to remove the occipital artery or its branches. Greater occipital nerve decompression without routinely ligating occipital artery, tremendously improves the occipital migraine headache in most of the patients.<sup>9</sup>

The variations in Occipital artery must be carefully attended to avoid further complications may be during interventional radiologic procedures, head and neck surgeries etc.<sup>10</sup>

## REFERENCES

1. Vishram Singh: Textbook of Anatomy- Head, Neck and Brain Volume III. Reed Elsevier India Private Limited Elsevier Publishers, 2019. 86-96.
2. Guo Y, Chen H, Chen X, Yu J. Clinical importance of the occipital artery in vascular lesions: a review of the literature. *The Neuroradiology Journal*. 2019 Oct;32(5):366-75.
3. Shimizu S, Oka H, Osawa S, Fukushima Y, Utsuki S, Tanaka R, Fujii K. Can proximity of the occipital artery to the greater occipital nerve act as a cause of idiopathic greater occipital neuralgia? An anatomical and histological evaluation of the artery-nerve relationship. *Plastic and reconstructive surgery*. 2007 Jun 1;119(7):2029-34.
4. Alvernia JE, Fraser K, Lanzino G. The occipital artery: a microanatomical study. *Operative Neurosurgery*. 2006 Feb 1;58(1):ONS-114.
5. Benet A, Tabani H, Ding X, Burkhardt JK, Rubio RR, Meybodi AT, Nisson P, Kola O, Gandhi S, Yousef S, Lawton MT. The transperiosteal "inside-out" occipital artery harvesting technique. *Journal of neurosurgery*. 2018 Jan 26;130(1):207-12.
6. Ateş Ö, Ahmed AS, Niemann D, Başkaya MK. The occipital artery for posterior circulation bypass: microsurgical anatomy. *Neurosurgical Focus*. 2008 Feb 1;24(2):E9.
7. Iwai T, Izumi T, Inoue T, Maegawa J, Mitsudo K, Tohnai I. Incidence of the occipital artery arising from the internal carotid artery identified by three-dimensional computed tomographic angiography. *British Journal of Oral and Maxillofacial Surgery*. 2012 Jun 1;50(4):373-5.
8. Sharma RK, Tuli P. Occipital artery Island V-Y advancement flap for reconstruction of posterior scalp defects. *Journal of plastic, reconstructive & aesthetic surgery*. 2010 Mar 1;63(3):410-5.
9. Chmielewski L, Liu MT, Guyuron B. The role of occipital artery resection in the surgical treatment of occipital migraine headaches. *Plastic and reconstructive surgery*. 2013 Mar 1;131(3):351e-6e.
10. Uchino A, Saito N, Mizukoshi W, Okada Y. Anomalous origin of the occipital artery diagnosed by magnetic resonance angiography. *Neuroradiology*. 2011 Nov;53:853-7.

