

Management of Compound Gustilo and Anderson Type 3C Distal Femur and Tibia Fracture with Ilizarov: A Case Reports

R B Uppin¹, S K Saidapur², Gangadhar Bhuti³, Bachchu Satish⁴, Vishal Upendra Kulkarni⁵

Author Affiliation: ¹Professor, ²Associate Professor, ³Senior Resident, ^{4,5}Post Graduates, Department of Orthopedic, Jawaharlal Nehru Medical College, Belgaum, Karnataka 590010, India.

Corresponding Author: R B Uppin, Professor, Department of Orthopedic, Jawaharlal Nehru Medical College, Belgaum, Karnataka 590010, India.

E-mail: uppinrajendra@rediffmail.com

How to cite this article:

R B Uppin, S K Saidapur, Gangadar Bhati, et al. Management of Compound Gustilo and Anderson Type 3C Distal Femur and Tibia Fracture with Ilizarov: A Case Reports. J orth. Edu. 2020;6(2):41-00.

Abstract

Distal femur fractures are mostly caused by a high-energy injury mechanism. Managing these compound fractures with vascular injury can be a challenging task. Most surgeons agree that distal femur fractures with vascular injury need to be treated operatively to achieve optimal patient outcomes. The effective surgical methods include external fixation and vascular repair, limb reconstruction system if there is bone loss, Masquelet technique and Ilizarov distraction osteogenesis. Post traumatic limb reconstructive surgeries, non-union, infection, bone loss, shortening and for deformity correction, Ilizarov is best operative technique to get excellent results.⁷ Common treatment for femoral nonunion with large segmental bone defect is difficult and complex.²

Keywords : Compound; Gustilo; Anderson.

Introduction

Compound distal femoral fractures with vascular injury constitute a type of lower limb injuries and open tibia fibula fractures difficult to treat. Despite advances in surgical technique and development of implants used for internal fixation of fracture fragments, the treatment continues to result in numerous complications. The Ilizarov External Fixator reduces the risk of complications and allows for bone union by distraction osteogenesis. Use of the Ilizarov apparatus reduces soft tissue laceration, preserves blood supply to the bone fragments, and allows for easier skin care, which is particularly important in the case of open fractures.⁴ Early rehabilitation with the patient fully loading the operated limb reduces muscle atrophy and stimulates bone union.¹ Primary and definitive fixation for infected nonunion of distal end femur fracture with Ilizarov technique is effective. Advantages include continuity of device until

union, reduced risk of infection, early mobilization, restoration of primary defect caused by bone loss, easy and accurate application, convertibility and versatility, and improved union rate for infected nonunion distal end femur fractures. Ilizarov technique helps to bring about healing of nonunion of fractures of long bones.³ Here we are going to discuss about a compound distal end femur fracture with femoral artery injury which is treated with LRS (Limb Reconstruction system) which got eventually ended as infected nonunion of distal end femur fracture and got treated with Ilizarov.

Case Report 1

A 60-year-old male patient presented to the Emergency Department (Casualty) with complaints of deformity, wound over left thigh and severe pain in his left thigh following a Road Traffic Accident. The patient gave a history of being a two-wheeler

rider and being hit by a tractor which subsequently ran over his left thigh. Patient was conscious and oriented to time, place and person. His vitals were stable. There was no head injury or history of loss of consciousness, vomiting or ENT bleed.

On inspection there was a gross deformity and swelling over his left thigh along with multiple abrasions and wound over left thigh. There were no signs of head injury. There is left foot drop with no active toe movements of left lower limb. On palpation, there was tenderness over the left thigh which aggravated upon any attempt at passive movement. The distal pulsations namely anterior and posterior tibial artery were found to be feeble compared to the contralateral side. Popliteal artery was not palpated due to severe pain exhibited by the patient on moving the limb. The foot was cold compared to the contralateral limb. Arteriogram was not performed owing to obvious signs of an ongoing or potential vascular compromise and hence to save time.

Plain Radiograph of Left Femur Oblique View

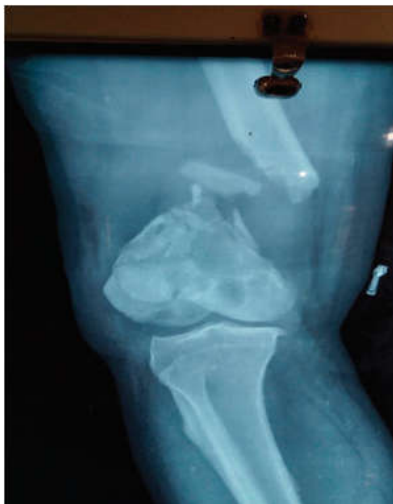

Fig. 1a: Compound left distal femur fracture.

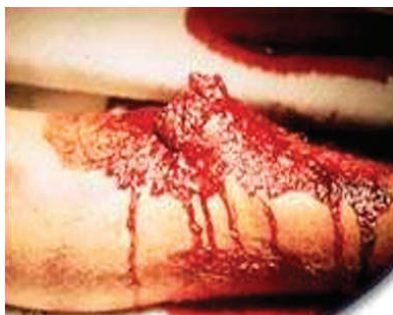

Fig. 1b: Clinical wound photograph.

Immediately after confirming left distal end femur fracture patient shifted to operation room stabilized the fracture with limb reconstruction system, wound debridement and femoral artery repair was done and skin defect was repaired 19 days after primary procedure with split thickness skin graft and patient got discharged after confirming of taking up of skin graft.(Fig. 1a and 1b)

Patient came after two months with the complaints of discharge from the pin tracts, swelling of left leg and inability to bear weight. No history of fever, weight loss and repeat trauma. On examination left lower limb LRS in place, discharge from proximal 3 pin tracts, swelling present at middle 1/3rd of thigh, firm in consistency, distal pulses felt, foot drop with no active toe movements and left lower limb shortening of 2 cms compared with right lower limb. Patient underwent LRS removal, application of Ilizarov ring external fixator, debridement and antibiotic bead application at surgical site under spinal anesthesia. After 2 months of ring external fixator fixation patient signs of infection subsided and admitted for removal of antibiotic beads and got discharged after 10 days of procedure. (Fig. 2 and 3)

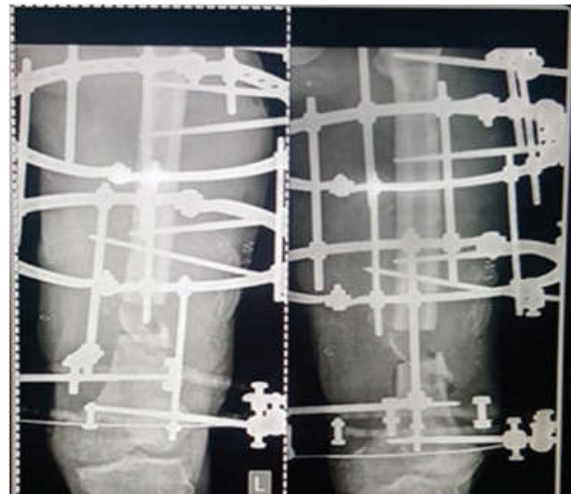


Fig. 2: Immediate post-operative x-ray left femur after Ilizarov fixation (ring external fixator).

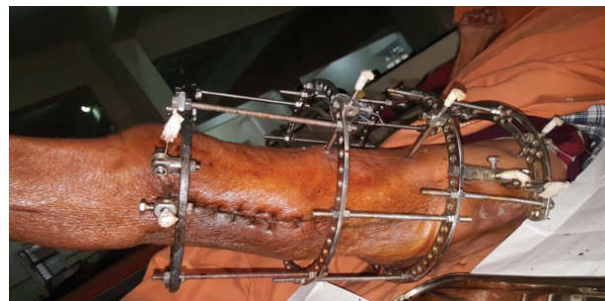

Fig. 3: Post-operative image after Ilizarov ring external fixator.

Results

Patient was with ring external fixator for 17 months and with multiple admission for distraction at proximal and compression at fracture site. Ring external fixator was removed after conforming bridging callus formation at fracture site on radiographs of left femur AP, lateral and oblique views. After removal of ring external fixator no movement at fracture site is confirmed by dynamic views under c-arm. (Fig. 4 and 5a)

Patient bone looks osteoporotic and bridging callus formation at fracture site, to avoid further fracture patient left lower limb stabilized with fiber glass cast application after healing of ring external fixator pin tracts.(Fig. 5b)

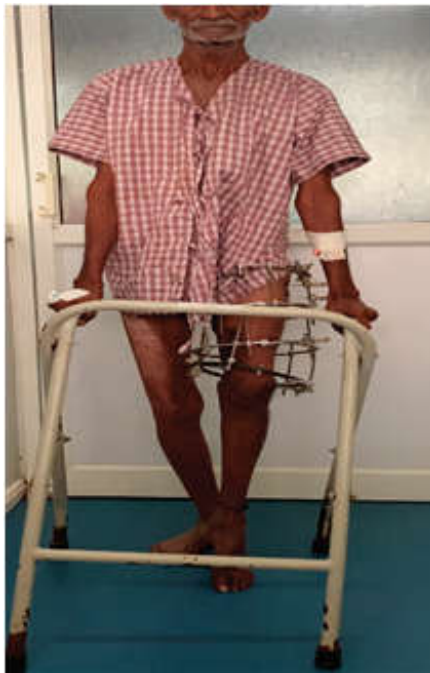

Fig. 4: Image just before removing Ilizarov fixator after conforming callus formation by comparing all follow up x-rays.

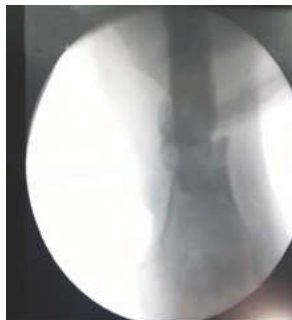

Fig. 5a: C-arm image after removal of ring external fixator.

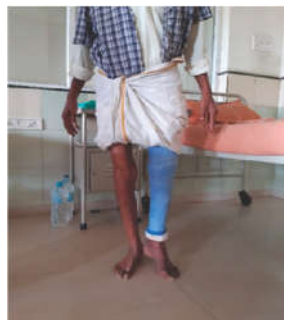

Fig. 5b: Fiberglass cast application after removal of ilizarov ring fixator healing of pin tract wound.

Case Report 2

A 55-year-old male patient presented to the Emergency Department (Casualty) with complaints of deformity, wound over right leg and severe pain in his right leg following a Road Traffic Accident. The patient gave a history of being a two-wheeler rider and being hit by a 4 wheeler. Patient was conscious and oriented to time, place and person. His vitals were stable. There was no head injury or history of loss of consciousness, vomiting or ENT bleed.

On inspection there was a gross deformity and swelling over his right leg along with multiple abrasions and wound over right leg. There were no signs of head injury. Active toe movements present. On palpation, there was tenderness over the right leg which aggravated upon any attempt at passive movement. The distal pulsations namely anterior and posterior tibial artery were found to be feeble compared to the contralateral side.

Plain x-ray of right leg anteroposterior view, lateral view done and found right tibia fibula comminuted segmental fracture, patient was hemodynamically stable and shifted to operation theater for debridement and AO external fixator application done and split thickness skin grafting done 13 days after primary procedure after confirming the healthy granulation tissue. Patient got discharged 14 days after surgery. (Fig. 6a)

After 1½ month patient came with the complaint of pus discharge from the pin tracts and repeat x-rays showed no signs of fracture union and diagnosed as infected fracture non-union of right tibia. AO external fixator removed and Ilizarov ring external fixator applied. Patient got discharged 12 days of Ilizarov fixation.(Fig. 6b and 7)

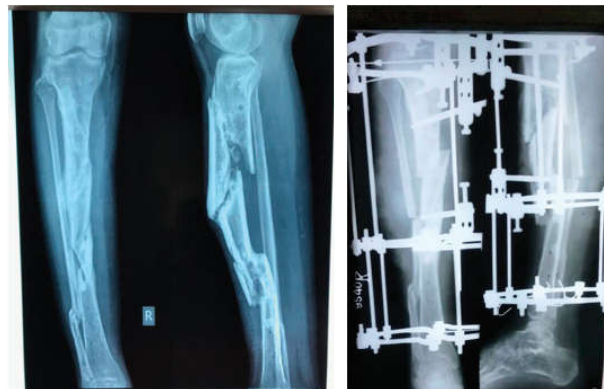

Fig. 6a: X-ray right tibia fibula after removal of AO external fixator.

Fig. 6b: ilizarov ring external fixator for right tibia.

Result

Patient was with ring external fixator for 9 months and with multiple admission for distraction at proximal and compression at fracture site. Ring external fixator was removed after confirming callus formation at fracture site on radiographs of right tibia AP, lateral and oblique views. After removal of ring external fixator no movement at fracture site is confirmed by dynamic view under c-arm. Patient was able to walk from 2nd day of Ilizarov ring fixator removal.

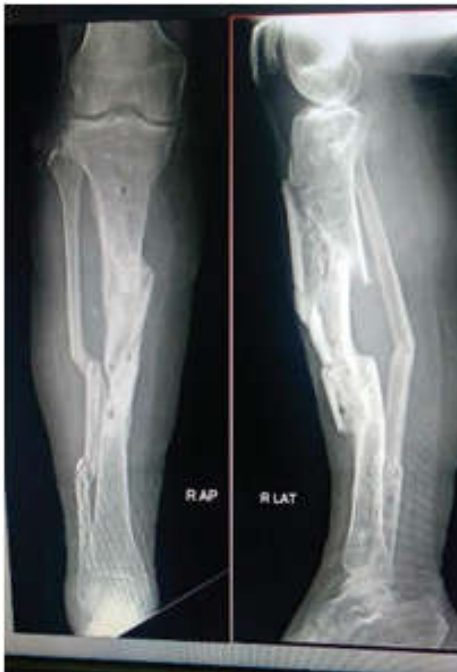

Fig. 7: X-ray of right tibia fibula after removal of Ilizarov ring external fixator removal.

Discussion

Treating compound injuries with conventional uniplanar or biplanar spanning external fixator is easy in emergency conditions, comfortable to patient and less learning curve compared to Ilizarov and limb reconstruction system to surgeon but stability, treating bone loss and early mobilization with ring external fixator is better.¹ Limb reconstruction system is a uni-dimensional system with less weight and basic principle of Ilizarov which is even tried primarily in this patient but failed to achieve union because of its hemi-callotaxis principle and uni-directional stability.⁹ Ilizarov ring external fixator works under the principle of distraction osteogenesis which is defined as process of new bone formation between

surfaces of two segments of bone that are gradually separated by incremental traction.⁷ Indication of Ilizarov ring external fixator are fracture nonunion, limb lengthening procedures, long bone deformity correction, open fracture with infection, non union with infection, Malunion, correction of joint contractures, reconstruction of bone defects and most important early mobilization and intense physiotherapy of joints possible.² Advantages of Ilizarov ring external fixator are minimal invasive, relatively easy application and allows deformity to be corrected in 3 dimensional (axial, angular and translational), simple hardware removal at the end. In both above discussed cases patient was treated with external fixation and treated the open wounds but because of hygienic compromise ended up with infection of the external fixator and nonunion of fracture seen and Ilizarov ring external fixator done which is sophisticated way of treatment.⁸ Both the patients was mobilized 2nd day of Ilizarov ring fixator. Both the patients are mobilized throughout the course of treatment and was on early physiotherapy which prevented them from joint stiffness and contractures.⁶ Ilizarov ring external fixator is best way of treating compound open long bone fractures, reduces soft tissue laceration, preserves blood supply to the bone fragments, and allows for easier skin care, which are particularly important in the case of open fractures.

References

1. Paley D, Catagni MA, Argnani F, Villa A, Benedetti GB, Cattaneo R, et al. Ilizarov treatment of tibial non unions with bone loss. *Clin Orthop Relat Res.* 1989;241:146-65.
2. Pal CP, Kumar H, Kumar D, Dinkar KS, Mittal V, Singh NK. Comparative study of the results of compound tibial shaft fractures treated by Ilizarov ring fixators and limb reconstruction system fixators. *Chinese J Traumatology.* 2015;18:347-351.
3. Canale ST, Beaty JH. 12th ed. Philadelphia: Elsevier Mosby; 2013. *Campbell's Operative Orthopaedics*; pp. 2981-95.
4. Golyakhovsky V, Frankel VH. New Delhi: Jaypee Brothers Medical Publishers; 2010. *Biomechanics of the Ilizarov external fixator.* In: *Textbook of Ilizarov Surgical Techniques Bone Correction and Lengthening*; pp. 1-8.
5. Shahid M, Hussain A, Bridgeman P, Bose D. Clinical outcomes of the Ilizarov method after an infected tibial non union. *Arch Trauma Res.* 2013;2:71-5.
6. Seenappa HK, Shukla MK, Narasimhaiah M. Management of complex long bone nonunions using limb reconstruction system. *Indian J Orthop.* 2013;47:602-7.

7. Blum AL, Bongiovanni JC, Morgan SJ, Flierl MA, dos Reis FB. Complications associated with distraction osteogenesis for infected nonunion of the femoral shaft in the presence of a bone defect: A retrospective series. *J Bone Joint Surg Br.* 2010;92:565-70.
 8. Rohilla R, Wadhvani J, Devgan A, Singh R, Khanna M. Prospectiverandomizedcomparison of ring versus rail fixator in infected gap nonunion of tibia treated with distraction osteogenesis. *Bone Joint J.* 2016;98-B:1399-1405.
 9. Hiranya Kumar S, Karthik MN and Sachin HG. Limb reconstruction system (LRS) in infected non union of femur: A case series. *International Journal of Orthopaedics Sciences.* 2019; 5(4): 639-645. DOI: 10.22271/ortho.2019.v5.i4k.1747.
-