

A Comparative Study of Expression of PTEN and p53 in Endometrial Hyperplasia and Carcinoma in a Tertiary Care Hospital

P Vineetha¹, Jaison Jacob John²

How to cite this article:

P Vineetha, Jaison Jacob John. A Comparative Study of Expression of PTEN and p53 in Endometrial Hyperplasia and Carcinoma in a Tertiary Care Hospital. Indian J Forensic Med Pathol. 2020;13(4):561-567.

Abstract

Context: A comparison of PTEN and p53 expression in endometrial hyperplasia and carcinoma.

Aims: To study the histomorphology and expression of PTEN and p53 markers in endometrial hyperplasia and carcinoma in histopathology samples.

Settings and Design: This is a comparative study done on 40 cases of endometrial hyperplasia and 20 cases of endometrial carcinoma.

Methods and Material: This is a 2 year study done on 40 cases of endometrial hyperplasia and 20 cases of endometrial carcinoma in a tertiary care hospital. Endometrial biopsies and resected specimens of uterus received at pathology department were grossed, processed and were stained by hematoxylin and eosin and examined by the pathologist. The expression of PTEN and p53 markers was evaluated on the diagnosed samples.

Results: Out of 36 cases of endometrial hyperplasia without atypia, 4 atypical hyperplasias and 20 endometrioid carcinomas, loss of PTEN expression was found to be 16.7%, 25% and 80% respectively, whereas expression of p53 was found to be 5.6%, 75% and 90% respectively in the same cases.

Conclusions: The loss of PTEN expression or positive expression of p53 in hyperplasias may be used as an early indicator of progression to carcinoma. The altered expressions of these markers are initiated in few cases of hyperplasia, which may progress to atypical hyperplasia, a premalignant lesion and ultimately develop into carcinoma.

Keywords: Endometrial hyperplasia; PTEN; p53; Endometrioid carcinomas; Immunohistochemistry.

Introduction

Endometrial carcinoma is the fourth most common malignancy in women. In the year 2018, in India, a total number of 13328 new cases of endometrial carcinoma and 5010 deaths were noted.¹ Endometrial carcinomas are classified as two types.

Type I carcinomas account for 90% of endometrial carcinomas, are estrogen dependent and follow hyperplasia – carcinoma sequence²; whereas Type II carcinomas arise in an atrophic background.³

PTEN and p53 are the most commonly involved mutations which follow different carcinogenic pathways. The present study is to assess the expression of PTEN and p53 markers in endometrial hyperplasia and carcinoma.

Objectives

- To diagnose endometrial hyperplasia and carcinoma on histopathology samples.

Authors Affiliation: ¹Postgraduate, ²Professor, Department of Pathology, Sri Ramaswamy Memorial Institute of Science and Technology, Potheri, Kattankulathur, Chengalpattu, Tamilnadu 603203, India.

Corresponding Author: Jaison Jacob John, Professor, Department of Pathology, Sri Ramaswamy Memorial Institute of Science and Technology to Sr Ramaswamy Memorial Institute, Potheri, Kattankulathur, Chengalpattu, Tamilnadu 603203, India.

E-mail: jaisonjacobjohn@yahoo.com

- To compare the expression of PTEN and p53 markers in endometrial hyperplasia and carcinoma.

Materials and Methods

This study includes 60 endometrial samples of which 40 were endometrial hyperplasias and 20 carcinomas. (Fig. 10)

The endometrial biopsies and resected specimens of uterus were received in the department of pathology in a Tertiary care hospital during a period of 24 months. The specimens received were subjected to tissue processing, section cutting and routine histopathology staining with hematoxylin and eosin, followed by examination by the pathologist. The samples which were diagnosed as hyperplasia and carcinoma of endometrium were subjected for immunohistochemistry and the expression of PTEN and p53 markers was assessed.

Inclusion criteria: The samples which were diagnosed as endometrial hyperplasia and carcinoma on routine hematoxylin and eosin staining were considered.

Exclusion criteria: The samples which were scanty or inadequate to perform immunohistochemistry and those for which blocks were not available were excluded.

Results

The results were interpreted in detail as the following. The PTEN nuclear and cytoplasmic expression was assessed based on Memorial Sloan Kettering Cancer Centre (MSKCC).⁴

Positive staining – Strong positive staining in the entire tumour.

Negative staining – No staining in entire/most tumour with strong positive staining of adjacent normal endometrium or stromal cells.

Heterogenous staining – Tumour with convincingly positive staining and convincingly negative staining.

Out of the 60 cases which were evaluated, there were 36 cases of (Fig.2 and Fig.3)endometrial hyperplasia,(Fig.1) 4 cases of atypical (Fig.4 and Fig.5) hyperplasia, 20 endometrioid carcinomas (Type - I) and no Type - II carcinomas. Out of the 36 cases of endometrial hyperplasia, 24 cases (66.6%) showed positive PTEN nuclear staining, 6 (16.7%)

were negative and 6 (16.7%) had taken up the stain heterogeneously.(Fig.8 and 9) Out of 4 cases of atypical hyperplasia, 1 (25%) case showed positive PTEN staining, 1 (25%) showed negative staining and 2 (50%) showed heterogenous staining.

Out of 20 endometrioid carcinomas, 16 (80%) showed negative staining for PTEN, 2 (10%) were positive and other 2 (10%) were stained heterogeneously.(Table 1) Loss of PTEN expression is seen predominantly in endometrioid carcinoma, followed by atypical hyperplasia and then by hyperplasia without atypia.

p53 scoring was done by calculating the percentage of tumour cells with positively stained nuclei to total number of tumour cells along with the intensity of staining which can be negative, weakly positive or strongly positive.⁵

Grade - 1 :<5% of cells with nuclear staining.

Grade - 2 :>/=5% and < 50% of cells with nuclear staining.

Grade - 3 :>/= 50% of cells with nuclear staining.

Out of 36 hyperplasia cases, 34 (94.4%) cases showed Grade-1 p53 staining, 2 (5.6%) cases showed Grade-2 staining. Out of 4 atypical hyperplasias, 1 (25%) case showed grade-1, 2 (50%) cases grade -2 and 1 (25%) case grade-3 p53 staining. Among 20 endometrioid carcinomas, 2(10%) cases showed grade-1, 14 (70%) cases showed grade-2 and other 4(20%) cases showed grade-3 staining. (Table 2)

Thus, in cases of hyperplasia without atypia positive staining for p53 was seen in 5.6% , in hyperplasia with atypia 75% and endometrioid carcinomas showed positive staining with p53 staining in 90% of the cases.(Fig.6 and Fig. 7)

Table 1: Expression of PTEN in endometrial hyperplasia and carcinoma.

PTEN Staining	Positive	Negative	Heterogenous
Endometrial Hyperplasia	24 (66.6%)	6 (16.7%)	6 (16.7%)
Atypical hyperplasia	1 (25%)	1 (25%)	2 (50%)
Endometrioid carcinoma	2 (10%)	16(80%)	2 (10%)

Table 2: Expression of p53 in Endometrial hyperplasia and carcinoma.

p53 staining/	Grade - 1	Grade - 2	Grade - 3
Hyperplasia	34 (94.4%)	2 (5.6%)	0
Atypical Hyperplasia	1 (25%)	2 (50%)	1 (25%)
Endometrioid carcinoma	2 (10%)	14(70%)	4 (20%)

Grade-1 : Negative staining, Grade-2 : weak staining, Grade-3 : strong staining.

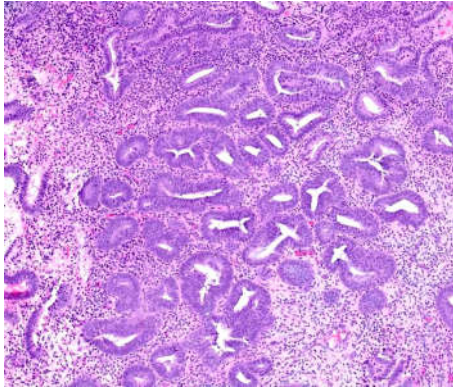


Fig 1: Endometrial Hyperplasia without atypia, {Hematoxylin & Eosin (H&E) stain,10X}.

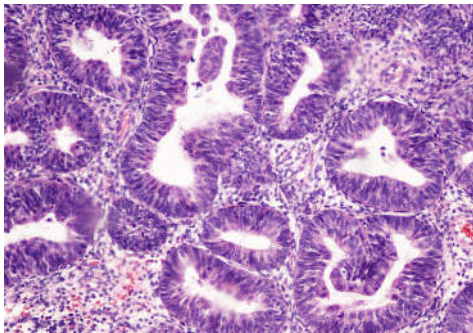


Fig. 2: Endometrial Hyperplasia with atypia, { H & E, 40x}.

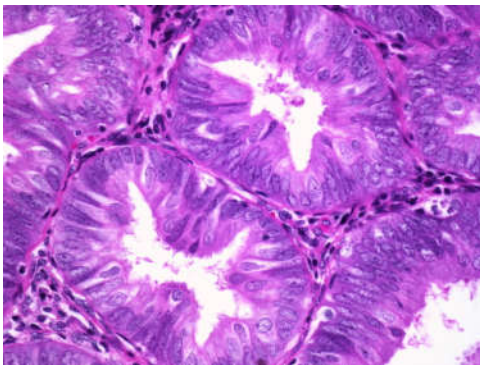


Fig. 3: Endometrial hyperplasia with Atypia showing loss of basal polarity {H & E, 40X}.

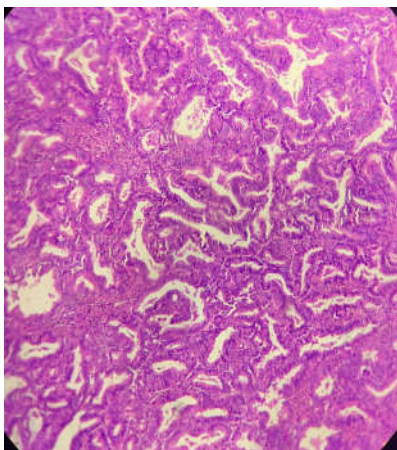


Fig. 4: Well differentiated endometrioid carcinoma,{H & E, 10X}.

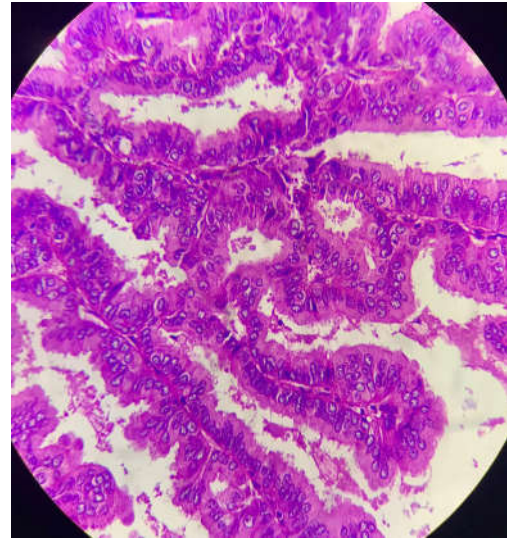


Fig. 5: Well differentiated endometrioid carcinoma - villoglandular architecture {H & E, 40X}.

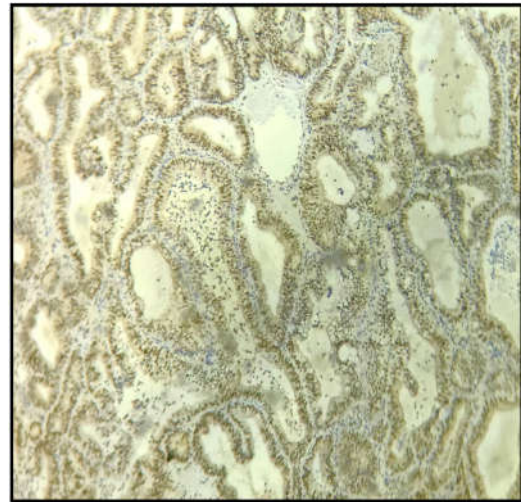


Fig. 6: Endometrioid Carcinoma showing p53 nuclear expression, {10X}.

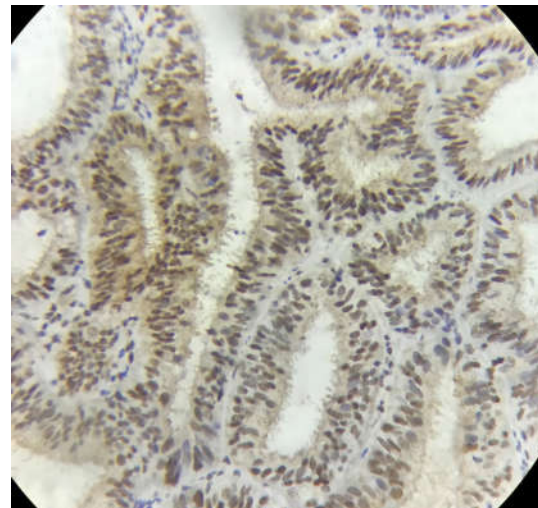


Fig. 7: Endometrioid carcinoma showing p53 nuclear expression, {40X}.

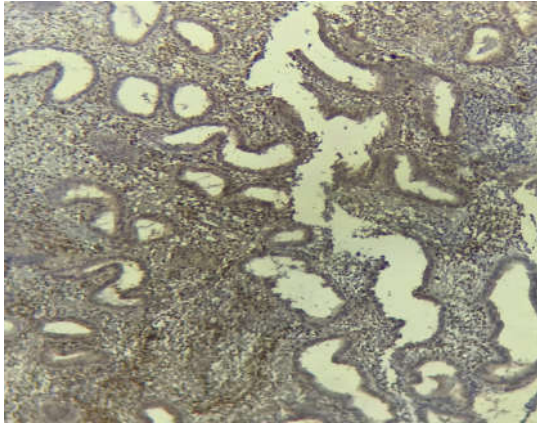


Fig. 8: PTEN cytoplasmic and nuclear expression in Endometrial Hyperplasia – Heterogenous staining, Stromal cells also show expression which act as internal positive control, {10X}.

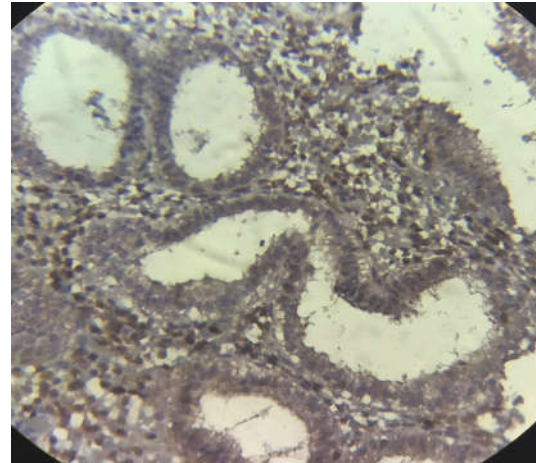


Fig. 9: PTEN expression in Endometrial Hyperplasia, 40X.

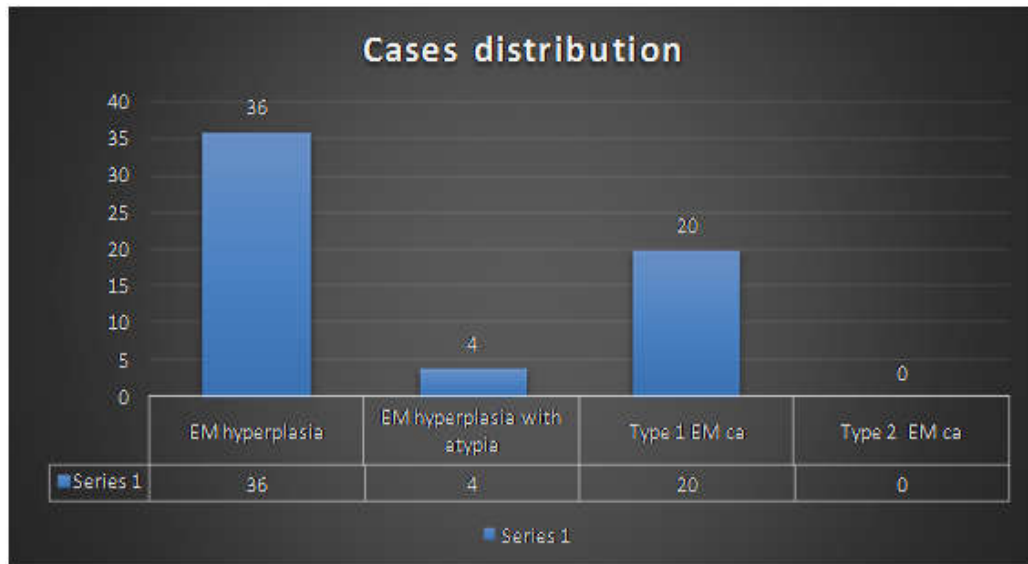


Fig. 10: Distribution of cases in present study.

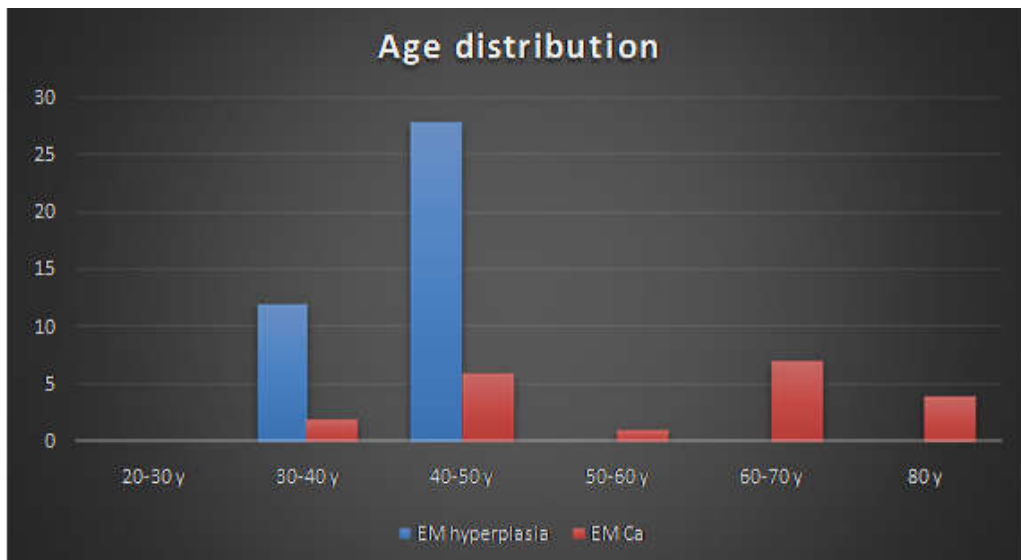


Fig. 11: Age distribution in cases of Endometrial hyperplasia and Endometrial Carcinoma.

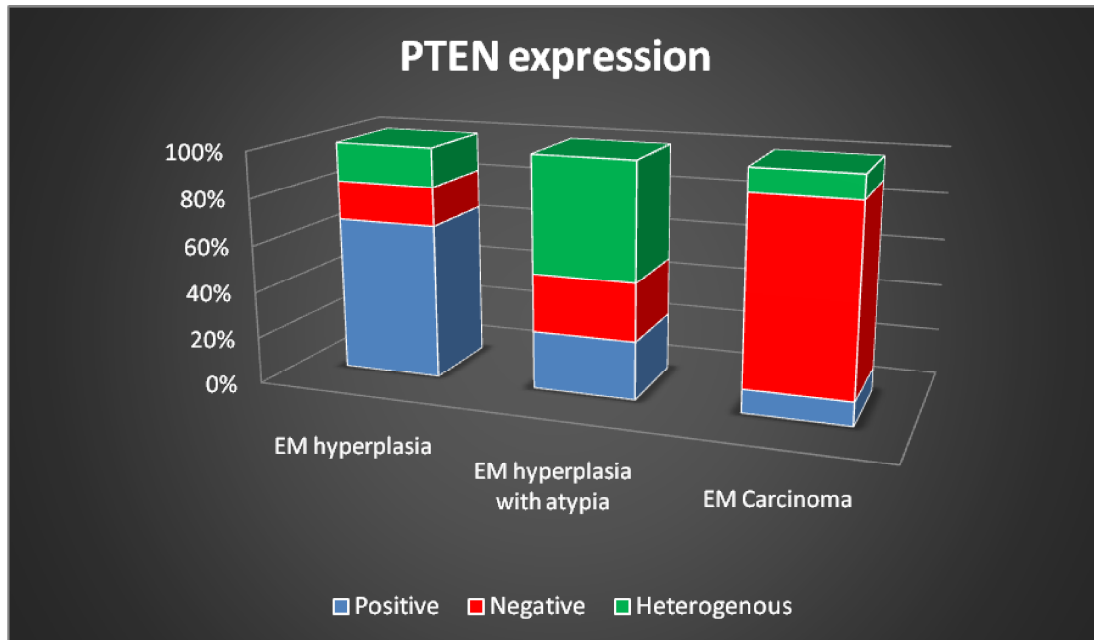


Fig. 12: Comparison of PTEN expression in Endometrial hyperplasia without atypia, Atypical hyperplasia and Endometrial carcinoma.

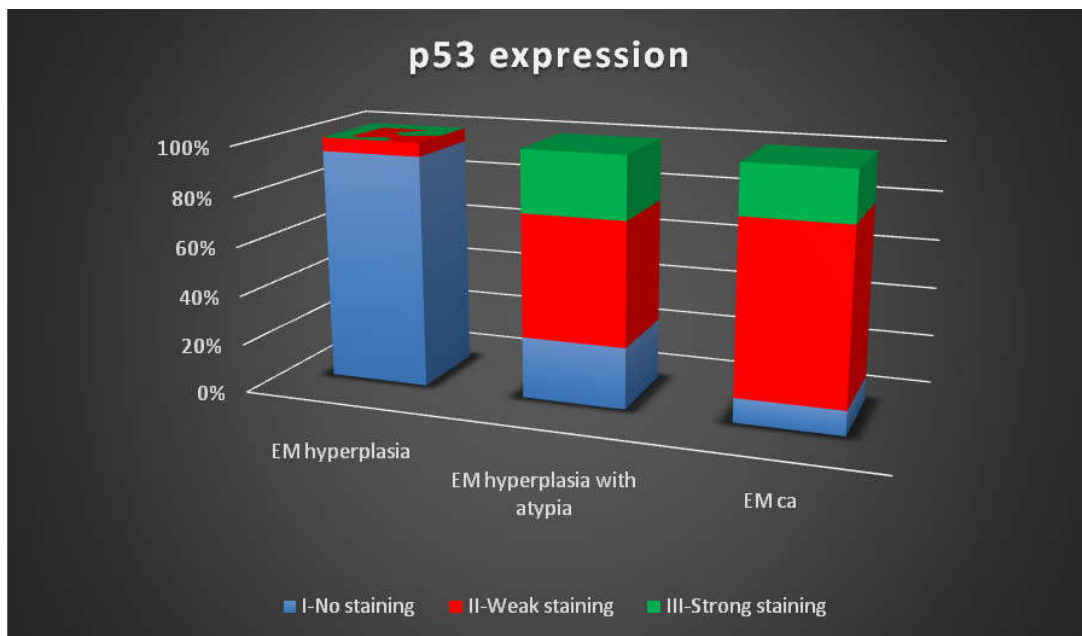


Fig. 13: Comparison of expression of p53 in Endometrial Hyperplasia without atypia, Atypical hyperplasia and Endometrioid carcinoma.

Discussion

Endometrial carcinoma most commonly occurs in postmenopausal women and the incidence is 4.3 per 1,00,000 women. There are two well known types- Type 1 accounts for 90% of the endometrial carcinomas and is estrogen dependent-atypical hyperplasia is the precursor lesion. Type 2 are non-estrogen dependent and arises in an atrophic background.

Endometrial hyperplasia, as per the latest 2014 WHO classification⁶ are divided into 2 types - Endometrial hyperplasia without atypia and endometrial hyperplasia with atypia. The pathogenesis of endometrial carcinoma and its precursor atypical hyperplasia is complex and involves PTEN inactivation and p53 mutation.

Yoshiaki Norimatsu et al. in their study stated that the median age of presentation of patients with endometrial carcinomas was 58.9 years (range

44-75 years). In the year 2017, Katarzyna et al. in their study stated that average age for endometrial hyperplasia and endometrial carcinoma was found to be 52 years and 63 years respectively. Supriya Sandeepa et al. in their study observed that 37% of hyperplasia cases presented in the age between 41 to 50 years. This correlated with the findings in our study. In our study, most cases of endometrial hyperplasia were seen in fifth decade and carcinoma cases were seen in seventh decade which correlated with the study findings of Katarzyna et al.

PTEN is a tumour suppressor gene identified in 1997- It is a phosphatase and tensin homologue present on chromosome 10. PTEN encodes a lipid phosphatase that antagonizes PI3K/AKT pathway by dephosphorylating PIP3(Product of PI3K). PTEN inactivation can be considered as the earliest event which is commonly seen in most of the endometrioid carcinomas.

The PTEN expression is seen in normal endometrium, it varies from a very high expression in proliferative endometrium to a gradual decrease by the end of secretory phase. The loss of PTEN expression has been correlated with both favourable and unfavourable prognosis as this gene inactivation is not only seen in early stage and well differentiated endometrial carcinomas, but also found in advanced, poorly differentiated and invasive carcinomas.

In a study by Tantbirojn et al. in 2008, loss of PTEN expression in endometrial hyperplasia without atypia, endometrial hyperplasia with atypia and endometrioid carcinomas was observed to be 24%, 60% and 60% respectively.⁷ Soheila Sarmadi et al. in the year 2009, documented that loss of PTEN in endometrioid carcinoma and endometrial hyperplasia with atypia to be 52% and 25% respectively.⁸ In the year 2017, Shanmugapriya et al. discussed that the loss of PTEN expression in endometrial hyperplasia without atypia, hyperplasia with atypia and endometrioid carcinoma was 11%, 50% and 70% respectively.⁹ In a study by Sitara S et al. in 2018, the PTEN loss in endometrial carcinoma and hyperplasia with atypia was found to be 61% and 37% respectively.

In our study, loss of PTEN expression in endometrial hyperplasia without atypia, endometrial hyperplasia with atypia and endometrioid carcinomas was 16.7%, 25% and 80% respectively. (Fig.12) Hence, the loss of PTEN expression in endometrial carcinoma in our study was correlating with the other studies.

p53 is a tumour suppressor gene which is situated on the chromosome 17p13.1. It is found to

be the most frequent target for genetic alteration in human tumours including Endometrial cancer and plays a vital role in tumour progression. When a p53 mutation occurs, a non-functional protein is produced which is non-degradable and allows immunohistochemical detection. Normal endometrium does not show positive nuclear staining in glandular epithelial cells. The expression of p53 increases as the severity of the endometrial lesion increases from endometrial hyperplasia to carcinoma. Inaba et al. stated in their study that p53 expression is associated with high histological grade, advanced stage of the carcinoma and also with unfavourable prognosis.

Risinger et al. mentioned in their study that the expression of p53 is seen in 29% of Type-1 endometrial carcinomas.¹⁰ Illie D et al. in their study on 30 cases of endometrial hyperplasia showed p53 expression in endometrial hyperplasia without atypia and hyperplasia with atypia to be 30% and 60% respectively. Boruban MC et al. in their study in the year 2008, stated that p53 gene mutation was present in 20% of endometrial carcinomas and was absent in cases of hyperplasia.¹¹ Nayar Musfera Abdul Masjeed et al. in the year 2017, observed the expression of p53 in endometrial hyperplasia without atypia, hyperplasia with atypia and endometrioid carcinomas to be 8.57%, 53.33% and 95.45% respectively.¹²

In our study, expression of p53 in hyperplasia without atypia was shown in 5.6% cases (weak staining), whereas among the cases of atypical hyperplasia, 50% showed weak staining and 25% showed strong staining. Endometrioid carcinomas showed 70% weak staining and 20% strong staining. (Fig.13) Hence, in our study the expression of p53 was correlating with the study done by Nayar Musfera Masjeed et al.¹²

In our study significant differences in expression of PTEN and p53 was found in endometrial hyperplasia without atypia, hyperplasia with atypia and endometrial carcinoma.

An inverse relationship was found with expression of PTEN and p53 as lesions progress from hyperplasia without atypia to endometrial carcinoma.

Conclusion

In our study done on 40 cases of endometrial hyperplasia and 20 carcinomas, it was observed that the most common age of presentation of endometrial hyperplasias was in the 5th decade and

carcinomas was in the 7th decade. ((Fig.11) In most endometrioid carcinomas, it was observed that there was loss of PTEN expression and positive staining for p53. In endometrial hyperplasia without atypia, loss of PTEN expression and p53 positive staining was seen in 16.7% and 5.6% of cases respectively, whereas in atypical hyperplasia it was found to be 25% and 75% respectively.

Acknowledgement: Nil.

Conflict of Interest: Nil.

References

1. Dar M, Sharma K. Burden of cancer in India: GLOBOCON 2018 estimates incidence, mortality, prevalence and future projections of cancer in India. J Emer Technol Innovat Res. 2018;6(6):e505.
2. Robert J Kurman, MD; Diagnosis of endometrial biopsies and curettings; 2nd edition, Pg 208-250.
3. Daniilidou K, Frangou-Plemenou M, Grammatikakis J, Grigoriou O, Vitoratos N, Kondi-Pafiti A. Prognostic significance and diagnostic value of PTEN and p53 expression in endometrial carcinoma. A retrospective clinicopathological and immunohistochemical study. J BUON.2013;18(1):195-20.
4. Garg K, Broaddus RR, Soslow RA, Urbauer DL, Levine DA, Djordjevic B. Pathologic Scoring of PTEN Immunohistochemistry in Endometrial Carcinoma is Highly Reproducible. Int J Gynecol Pathol. 2012;31(1):48-56.
5. Alkushi A, Lim P, Coldman A, Huntsman D, Miller D, Gilks CB. Interpretation of p53 immunoreactivity in endometrial carcinoma: establishing a clinically relevant cut-off level. Int J Gynecol Pathol. 2004 Apr;23(2):129-37.
6. GeburtushFrauenheilk 2015; 75: 135 -136): Emons G, Beckmann MW, Schmidt D, et al. New WHO classification of endometrial hyperplasias.
7. Tantbirojn P, Triratanachat S, Trivijitsilp P, et al. Detection of PTEN immunoreactivity in endometrial hyperplasia and adenocarcinoma. J Med Assoc Thai 2008;91(8):1161-5.
8. Sarmadi S, Izadi-Mood N, Sotoudeh K, et al. Altered PTEN expression : a diagnostic marker for differentiating normal, hyperplastic and neoplastic endometrium. Diagnostic Pathology 2009;4(1):41.
9. Shanmugapriya M, Sudha M, Geetha P. A study of PTEN expression in endometrial hyperplasia and endometrioid type of endometrial carcinoma. Trop J Path Micro 2017;3(1):39-45.
10. Risinger JI, Hayes K, Maxwell GL, Carney ME, Dodge RK, Barrett JC, et al. PTEN mutation in endometrial cancers is associated with favorable clinical and pathologic characteristics, Clin Cancer Res. 1998;4(12):3005-10.
11. Boruban MC, Altundag K, Kilic GS, Blankstein J. From endometrial hyperplasia to endometrial cancer: insight into the biology and possible medical preventive measures. Eur J Cancer Prev.2008;17(2):133-38.
12. Masjeed NMA, Khandeparkar SGS, Joshi AR, Kulkarni MM, Pandya N. Immunohistochemical study of ER,PR, Ki67 and p53 in Endometrial Hyperplasias and Endometrial Carcinomas. J Clin Diagn Res. 2017;11(8):EC31-EC34.

